



## CASE REPORT

**COMPLICATION OF THE EXTRACTION OF MAXILLARY ANTERIOR SUPERNUMERARY TEETH: THE ACCIDENTAL EXTRACTION OF THE PERMANENT TOOTH BUD**

Giuseppe Varvara<sup>1</sup>, Francesca Angiolani<sup>1</sup>, Fabiola Rinaldi<sup>1</sup>, Davide Gerardi<sup>2</sup>, Sara Bernardi<sup>2</sup>, Sofia Rastelli<sup>2</sup>, Gianluca Botticelli<sup>2</sup>, Tommaso Pizzolante<sup>2</sup>.

<sup>1</sup> Department of Innovative Technologies in Medicine & Dentistry, Dental School, 'G. D'Annunzio' University of Chieti-Pescara, 66100 Chieti, Italy.

<sup>2</sup> Department of Life, Health and Environmental Sciences, University of L'Aquila, 67100 L'Aquila, Italy

**Corresponding author:** Sofia Rastelli, University of L'Aquila, L'Aquila, Italy,  
email: [sofia.rastelli@graduate.univaq.it](mailto:sofia.rastelli@graduate.univaq.it)

**Received:** Dec 6, 2024; **Accepted:** Dec 26, 2024; **Published:** Jan 20, 2025

### Abstract

**Background.** This article aims to report the case of a seven-year-old girl affected by a numerical dental anomaly. Supernumerary teeth can lead to secondary dental eruption disturbance dental crowding and bone cysts formation. Even though the clinical and instrumental documentation was adequate to make a correct diagnosis and a surgical-orthodontic treatment plan, a technical error during the surgical phase can lead to the extraction of the permanent bud instead of the supernumerary tooth. The presented case highlights the 2-year follow-up of the immediate reimplantation of the avulsed tooth after the attempt to extract the supernumerary bud and provides the clinician with the most precise awareness and knowledge of possible medico-legal implications regarding surgery at the wrong site.

**Materials and Methods.** During the extraction attempt, the clinician mistakenly extracted the wrong dental element, the bud of the permanent 1.1, and proceeded to reimplant it. After 11 months, a second dentist extracted the correct supernumerary tooth. The case defines guidelines applicable in outpatient clinical practice to manage complications in the best possible way.

**Results and conclusion.** The therapy of supernumerary teeth is extraction. Further work is needed to monitor why a wrong tooth extraction occurs and how it can be prevented; this will be possible by reporting incidents, analyzing the root causes, and clearly and thoroughly educating the clinician on his medico-legal responsibilities.

**Keywords:** supernumerary teeth, tooth bud, complication, extraction

### INTRODUCTION

Dentistry often faces diagnostic and management concerns due to dental anomalies, and in particular, delayed eruption of the permanent maxillary incisors.<sup>1-2</sup> Failure in incisors eruption occurs in the early mixed dentition and can be due to several causes. However, the most common cause is impaction associated with the presence of a supernumerary tooth (ST) in the anterior premaxillary region.<sup>3-4</sup> The reported prevalence of supernumerary teeth (STs) is 2.6%, of which 90-98% occur in the maxilla.<sup>5</sup> Delay or failed eruption results in 43% of affected maxillary central incisors.<sup>5</sup> Although there is no significant sex distribution in primary teeth, males are affected approximately twice as frequently as females in the permanent dentition. However, the ratio is 1:1 in the primary dentition.<sup>6-7</sup>

Only approximately 25% of maxillary anterior STs erupt into the oral cavity. The inheritance of STs does not follow a simple Mendelian pattern, but case reports suggest a familial tendency. A thorough clinical examination and routine radiological examination reveal and confirm the diagnosis of STs. Radiographic examination is most important when abnormal clinical signs are found.<sup>8</sup> An anterior occlusal or periapical radiograph is useful to show the incisor region in detail, but orthopantomogram (OPG) and lateral cephalogram helps to locate STs that are deep in the palate and allow the practitioner to decide whether to use a buccal rather than palatal approach to remove them.<sup>9</sup> Many studies have stated that three-dimensional reconstructions based on Cone Beam Computed Tomography (CBCT) data can be used to examine the dental and bone structures around STs.

Giuseppe Varvara, Francesca Angiolani, Fabiola Rinaldi, Davide Gerardi, Sara Bernardi, Sofia Rastelli, Gianluca Botticelli, Tommaso Pizzolante. Complication of the extraction of maxillary anterior supernumerary teeth: the accidental extraction of the permanent tooth bud. *Bulletin of Stomatology and Maxillofacial Surgery*. 2025;21(1):29-35. doi:10.58240/1829006X-2025.1-29

Many studies have stated that three-dimensional reconstructions based on Cone Beam Computed Tomography (CBCT) data can be used to examine the dental and bone structures around STs. Katheria et al. compared the efficiency of conventional radiography and CBCT for detecting impacted and supernumerary teeth in children and concluded that CBCT provides more information about the location, presence of root resorption, and treatment planning.<sup>10</sup>

When STs are identified, the decisional tree includes two branches: the “wait and see” approach and the surgical removal.<sup>11-13</sup> Indeed, surgery may cause damage to anatomical structures or adjacent teeth. Therefore, the risks and benefits of surgery should be weighed.<sup>13</sup>

Some authors suggest a follow-up unless the teeth cause any complications or occlusal changes.

Generally, while erupted STs can be extracted, extraction is not always suitable for unerupted STs, especially in children with developing permanent tooth buds in the pre-maxilla region.<sup>14</sup> The best time to extract unerupted supernumerary teeth in this population is still controversial. Alsani et al. suggested that early extraction of STs (before 6 years of age) can effectively prevent STs-related complications and maximize the eruption potential of permanent teeth.<sup>15</sup> It is emphasized that STs should be removed as soon as they are found.<sup>15</sup>

However, considering that the developing permanent tooth germ may be damaged during the operation, some authors advocate delaying extraction until the patient reaches the age of 8–10 years, when the roots of adjacent teeth are basically developed.<sup>16</sup> However, the disadvantage is that delayed extraction may cause loss of eruption potential of adjacent teeth. Therefore, secondary surgical and/or orthodontic interventions may be necessary at later stages.<sup>17</sup>

From the available literature, the age of 6 may be a suitable time for the extraction of unerupted ST.

It is very important for the dentist to be aware of the causes of unerupted teeth, such as space availability and the patient's chronological age, and to carefully consider the appropriate timing for referral and surgical intervention. A good prognosis depends on a multidisciplinary approach to diagnosis and treatment planning by the pediatric dentist, surgeon, and orthodontist working together. This approach can also prevent the development of dental misalignments.<sup>18</sup> Surgical-orthodontic management strategies for children with impacted maxillary incisors due to a supernumerary tooth generally involve three possible interventions: removal of the supernumerary tooth alone, removal of the supernumerary and space creation, or removal of the supernumerary and orthodontic traction on the

impacted incisor.<sup>19</sup>

Apparently, since 30%- 54% of impacted maxillary incisors require additional surgery after removal of the supernumerary tooth alone, the sole removal of the supernumerary tooth alone does not ensure proper eruption of the affected maxillary incisor, and more importantly, the time required for incisor eruption is subject to great variability.<sup>20,21</sup>

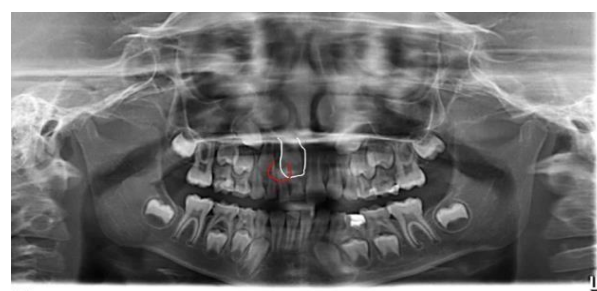
An orthodontic device should create space within the dental arch prior to surgery. After surgery, the device is used to apply directional traction to the incisor.<sup>22</sup> A key step in this treatment modality is the creation of space. Patient characteristics, type of obstruction, impaction of the incisor, or the execution treatment performed may also affect the success of incisor eruption after removal of the supernumerary.<sup>23</sup>

The surgical-orthodontic treatment of supernumerary teeth requires an accurate diagnosis and precise localization of the teeth and surrounding structures.

The presented case reports a clinician evaluating a 7-year-old girl with a failed eruption of element 11 and the presence of a supernumerary tooth; after performing a surgical-orthodontic diagnostic and therapeutic analysis, she planned to remove the supernumerary tooth. The analysis of the case highlighted the existence of a material error, with the hypothesis of generic professional liability attributable to the dental practitioner.

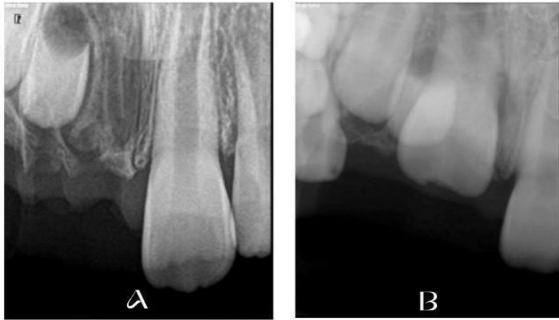## Case report

A 7-year-old girl presented herself at a private dental practice where she was being treated to undergo the extraction of three deciduous teeth, with the aim of being able to extract a supernumerary tooth included in the maxillary bone in position 1.1 (Figure 1)



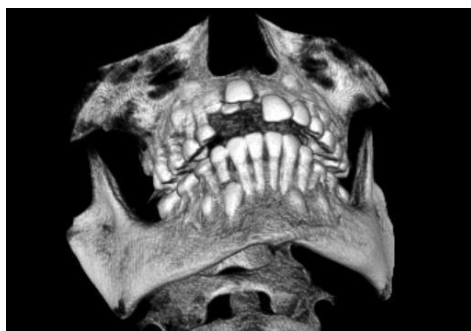**Figure 1.** Patient's OPG. The supernumerary bud (red contoured) is appreciable on the distal angle of 1.1 tooth (white contoured).

While attempting to extract the supernumerary tooth, the clinician realized that he had mistakenly extracted the dental element 1.1 and proceeded to reimplant it, no longer proceeding with the extraction of the supernumerary tooth, as foreseen in the previously scheduled intervention (Figure 2).



**Figure 2.** A. Radiograph showing the extraction of the 1.1. instead of the supernumerary bud. B. Radiograph after the re-implantation.

The same doctor checked the girl in the period following the extraction to evaluate the post-extraction phase. The dentist maintained that the accidentally extracted incisor suffered no trauma and reported that tooth 1.1's emergence was slow but gradual, asserting that the tooth would have resumed its natural course. However, a CBCT was required by the child parents, assessing the presence of the ST (Figure 3).

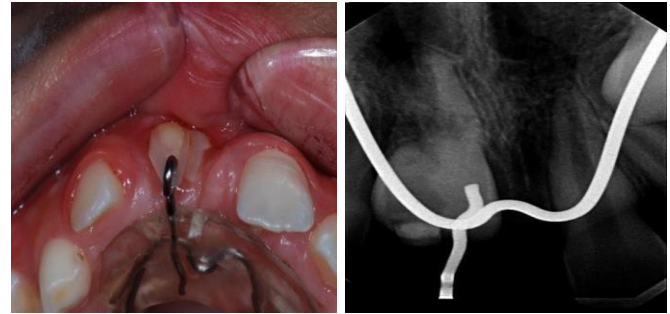


**Figure 3.** Volume rendering of the CBCT.

A different dentist, after 5 months, performed the extraction of ST and, in the following five additional months, given the failure of the incisor to emerge into the arch, proceeded with the "uncapping" of the same.

After a year, following the tooth's failure to move, the young patient was applied an upper plate with a button on the surface of the incisor with the aim of pulling it into the arch; this attempt, however, also did not have the desired effect.

After 11 months from the extraction attempt the clinical and instrumental examination confirmed:  
 - presence in the arch of the vestibular mesial surface of tooth 1.1 in an ectopic position subjected to slow traction with elastics on a fixed device anchored on teeth 1.6 and 2.6 with a resin plate and  
 - alteration in minus of the morphology of the vestibular portion of the maxillary arch in the 1.1-1.2 location (Figure 4).



**Figure 4.** Clinical view of the operated site.

**Figure 5.** Inflammatory process of external root resorption involving the distal portion of the root of tooth 1.1

The analysis confirmed the possible presence of professional liability due to technical error attributable to the first dentist. In addition, the 1.1, when the patient will be grown, should be extracted and replaced with a fixture to avoid further loss of cortical bone in premaxilla and consequently maintain aesthetic and masticatory functionality<sup>24</sup>.

**Discussion**

*The medical error in the case*

In the case report, an incorrect assessment is evident due to the presence of a supernumerary element. The incorrect management behavior that occurred in the dental practice may be associated with the absence in the records of a preoperative volumetric radiographic examination, which in some way could have directed the doctor to perform a correct intervention, avoiding the complication. According to literature, ST's 3D characteristics (orientation and position) are associated with ST's eruption status, suggesting that CBCT evaluation of non-erupted ST is recommended for accurate planning.<sup>25</sup>

In addition to an incorrect evaluation of diagnostic imaging, the error in the case report can be associated with the application of an improper extraction technique or with the secondary or incorrect technique of using surgical instruments. Medical errors are a common cause of morbidity and mortality in a variety of healthcare settings. The Institute of Medicine (IOM) published a report in November 1999 focused on medical errors and patient safety. The report defined medical error as "the failure to complete a planned action as intended or the use of an incorrect plan to accomplish a purpose."<sup>26</sup> Wrong-site tooth extraction falls under the definition of medical error, where a tooth other than the one intended by the referring dentist is extracted.<sup>4</sup> The Joint Commission on Accreditation of Healthcare Organizations (JCAHO) also considers wrong-site surgery a sentinel event.<sup>27</sup> They define a sentinel event as "an unexpected occurrence that results in death or serious physical or psychological injury, or the risk thereof."<sup>27</sup> Despite its well-known medico-legal implications, there have been few reports on wrong-site tooth extraction in the literature.<sup>5</sup>

The articles reported in the literature regarding the experience of wrong-site extraction are likely an underreported error, as are other medical errors,<sup>3</sup> for which the incidence of such an unreported error is defined as an unknown value.

### **Prevention and Management of the mistaken extraction: the use of immediate Replantation.**

Most cases of tooth extractions in the wrong site are preventable and can be minimized by developing an educational program, developing a standard, unequivocal, and informative reporting form, a preoperative checklist, and incorporating a Universal Protocol. The JCAHO has mandated that, effective July 1, 2004, all JCAHO-accredited organizations comply with the Universal Protocol to Prevent Wrong Site, Wrong Procedure, Wrong Person Surgery.<sup>27</sup>

The ADA and JCAHO agree and recommend the following:<sup>27,28</sup>

1. Review the dental record, including medical records, history, laboratory results, appropriate charts, and dental X-rays. Record the tooth number(s) or mark the location of the tooth or surgical site on the chart or x-ray to be included as part of the patient's record.
2. Ensure that the X-rays are correctly oriented and visually confirm that the correct teeth or tissues have been mapped.
3. Conduct a "time out" to review the patient, tooth, and procedure with the assistant present during extraction (2-person rule).

Adhering to these safety principles and protocols aims to improve the delivery of quality care, ensure patient safety, and increase national awareness of preventable medical errors. It is essential that the clinician knows how to manage the complication that has occurred and that any tooth extraction at the wrong site is identified immediately for a better clinical outcome and reduced legal liability. In fact, from a clinical point of view, when tooth extraction in the wrong site is identified immediately, dental reimplantation can be performed with subsequent endodontic therapy to allow retention of the affected tooth. Avulsion and intrusion of permanent teeth are considered the most serious dentoalveolar traumatic injuries.<sup>29</sup> An avulsion is one of the most serious tooth injuries and can occur due to trauma, as in the majority of cases, or due to other causes, such as a medical error in our case.<sup>29</sup> Immediate transplantation of the avulsed tooth is the recommended treatment and guarantees a good prognosis, although this is not always possible.<sup>29</sup> However, successful reimplantation requires effective management of both the damaged periodontal and pulpal tissues. Despite treatment, 21-89% of replanted teeth are ultimately lost and have

the worst outcomes of all dentoalveolar traumas.<sup>30</sup>

Factors that influence the success of the replantation procedure include the type of preservation medium, extraalveolar time, degree of periodontal damage, pulpal condition, and root development. Most complications following traumatic tooth avulsion and subsequent replantation are related to impaired healing of the pulp and periodontal ligament (PDL). Possible complications include inflammation and infection-related root resorption;<sup>25</sup> the latter condition tends to be progressive and is initiated and maintained by intracanal bacteria that reach the root surface through the dentinal tubules. Pulp space infection and related root resorption can be prevented or successfully treated with appropriate endodontic treatment, arresting its progression. This is the complication that occurred in our case. Another possible complication of replantation is radical ankylosis<sup>31,32</sup> and tooth loss. Pulpal management in avulsed teeth is different from other forms of trauma due to the complete loss of blood supply. After replantation, root canal treatment should be started 7-10 days later for teeth with closed apices.<sup>33</sup> In immature teeth with open apices, pulpal revascularization<sup>30</sup> with subsequent intrapulpal hard tissue formation is possible, known as "pulp canal obliteration (PCO)" or "calcified metamorphosis."

PCO can be partial or complete. Although considered a sign of healing, partial and complete PCO present a challenge in pulp canal management if endodontic treatment is needed due to subsequent pulp necrosis or other reasons. However, the risk of secondary pulp necrosis, even during restorations, prostheses, or orthodontic treatments, is limited. Other clinical complications are considered to be the yellowish coloration of the crown<sup>23</sup> and the lack of pulpal sensitivity.<sup>32</sup> According to a study, pulp healing after replantation of immature teeth occurred in 75 teeth (32.9%), while pulp necrosis occurred in 153 teeth (67.1%) out of 228 replanted teeth analyzed.<sup>34</sup> PCO was the most frequent outcome of pulpal healing since it occurred in 96% of the healed pulps.<sup>34</sup>

### **Medical-legal aspects.**

Problems associated with incorrect tooth extraction deserve high attention because they are characterized by low therapeutic complexity and important medico-legal aspects.<sup>35</sup> Wrong-site surgery is a serious event that can attract litigation from the patient and his relatives.<sup>31,32,35</sup> Wrong-site tooth extractions continue to be a major reason for filing malpractice claims against oral and maxillofacial surgeons, despite mandatory education, training and courses on risk management requirements for dentists.<sup>36</sup> In terms of medico-legal and ethical obligations, the surgeon must not deliberately withhold information from the patient,

and the patient's treatment must not proceed without informed consent. It is the surgeon's obligation to inform the patient immediately when the error is identified, such as when the wrong tooth has been extracted or the wrong site operated on. It is, therefore, necessary to communicate the erroneous event to the patient, regardless of whether the error was identified immediately or later.<sup>37-40</sup> The risk management company must also be informed immediately. The ideal protocol consists of determining the options for tooth replacement, discussing these options with the referring dentist, and finally counseling the patient to orient him/her towards the possible solutions. It is typical for the discussion to take place on the costs of the solution. Agreements should be made between the referring dentist and the surgeon regarding the costs of the solution to minimize the impact on the patient. In many situations of incorrect extraction, the immediate offer of a solution is sufficient to grant little or no financial impact, stop the patient's worries, and avoid potential and important legal actions.

### Conclusions

The case report aims to help operators make therapeutic clinical decisions when faced with a child with an impacted maxillary anterior tooth due to an obstacle in its eruption, i.e., the presence of a supernumerary tooth.<sup>41-45</sup>

1. The prognosis of orthodontic-surgical treatment for impacted incisors is good; however, failures also occur, particularly when the etiology of the failed tooth eruption is given by incorrect extraction with consequent immediate reimplantation and inflammation occurs in the distal root of the tooth.<sup>46-50</sup>

2. Based on the results presented in this case, it can be recommended that the obstacle present in the eruption path of the permanent tooth be surgically extracted using modern and cutting-edge techniques, such as three-dimensional instrumental examinations, and an accurate treatment plan that follows the appropriate guidelines to prevent the wrong site and procedure and to manage the complications in the best possible way.<sup>51-56</sup>

3. Other factors, such as surgical management errors, may influence the therapeutic approach. Further research is essential to understanding the causes of incorrect tooth extraction and identifying effective prevention strategies. This can be achieved through incident reporting and in-depth analysis of the main causes.<sup>56-57</sup>

4. Furthermore, the case report aims to provide the clinician with a clear and in-depth awareness of the possible medico-legal implications of surgical interventions performed on the wrong site for which he is responsible.<sup>57-62</sup>

### Conflicts of interest and financial disclosures

The author declares that he has no conflict percent and there was no external source of funding for the research in question.

**Ethical approval:** The study was approved by the University ethics committee and was conducted in accordance with the Declaration of the World Medical Association.

**Informed consent:** Informed consent was obtained from all individual participants included in the study.

**Source of funding:** The work was not funded

## REFERENCES

1. Bernardi S, Bianchi S, Bernardi G. et al. Clinical management of fusion in primary mandibular incisors: a systematic literature review. *Acta Odontol Scand.* 2020 Aug;78(6):417-424
2. Bianchi S, Bernardi S, Belli M. et al. Exposure to persistent organic pollutants during tooth formation: molecular mechanisms and clinical findings. *Rev Environ Health.* 2020;17;35(4):303-310
3. Bernardi S, Mummolo S, Zeka. et al. Use and Evaluation of a Cooling Aid in Laser-Assisted Dental Surgery: An Innovative Study. *Photomed. and Laser Surgery.* 2016;34(6): 258–262
4. Di Biase DD. Midline supernumeraries and eruption of the maxillary central incisor. *Dent Pract Dent Rec* 1969;20:35-40.
5. Di Paolo, C., Qorri, E., Falisi, G., Inchingolo. et al *Journal of Personalized Medicine,* 2023, 13(7), 1095
6. Kumar SS, Thailavathy V, Srinivasan D. et al Comparison of Orthopantomogram and Lateral Cephalogram for Mandibular Measurements. *J Pharm Bioallied Sci.* 2017 ;9(1):92-95.
7. Pizzolante, T., Memè, L., Ciccariello, A., Inchingolo, F., Mummolo, S. Complications of zygomatic implantology: observational clinical study. *Bulletin of Stomatology and Maxillofacial Surgery,* 2024, 20(4);73–80
8. Scheiner MA, Sampson WJ. Supernumerary teeth: a review of the literature and four case reports *Aust Dent J.* 1997 ;42(3):160-5.
9. Nogami, S., Miyamoto, I., Yamauchi, K., Supernumerary deciduous teeth with multiple maxillary impacted mesiodens: A case report. *Pediatric Dental Jour.* 2012. 22(2),193-197.
10. Memè, L., Bambini, F., Pizzolante, T., Bianchi, A., Mummolo, S. Evaluation of a single non-surgical approach in the management of periimplantitis: glycine powder air-polishing versus ultrasonic device. *ORAL and Implantology,* 2024;6(2), 67–78
11. Omer RSM, Anthonappa RP, King NM. Determination of the Optimum Time for Surgical removal of Unerupted Anterior Supernumerary

- Teeth. *Pediatr Dent.* 2010;32(1):14–20
12. Botticelli G., Severino M., Ferrazzano G.F. et al. Excision of lower lip mucocele using injection of hydrocolloid dental impression material in a pediatric patient: A case report *Applied Sciences (Switzerland)*.2021;11;(13);5819,
  13. Iacomino, E., Rastelli, S., Capogreco, M., Grivetto, F., D'amario, M. Pterygoid implants in severe posterior maxillary atrophy: a case report. *ORAL and Implantology*, 2024;16(2);88–94
  14. Falisi, G., Qorri, E., Botticelli, G., Mondragon, M., Di Giacomo, P. Stabilization of the lower denture through the use of fine mini-implants: retrospective study. *European Journal of Musculoskeletal Diseases.* 2024;13(2);1–7
  15. Arcuri, C., Petro, E., Sollecchia, G., Mummolo, S., Marzo, G. Laser in periodontal pockets: In vivo and in vitro study. *Journal of Biological Regulators and Homeostatic Agents.*2020;34(3);139–146
  16. Rastelli, S., Capogreco, M., D'amario, M., ... Severino, M., Iacomino, E. PTERIGOID IMPLANTS: A viable alternative for the rehabilitation of the posterior sectors of the atrophic maxilla *ORAL and Implantology.*2024;16(1);38–43
  17. Mummolo S., Nota A., Marchetti E., Capuano S., Tecco S., Marzo G., Campanella V. Histologic and histomorphometric analysis of maxillary sinus augmentation with different biomaterials. A pilot split-mouth human study. *ORAL and Implantology*, 2018;11 (4);249 - 256,
  18. Alsani A, Balhaddad A. Delayed eruption of Maxillary Central Incisors Associated with the Presence of Supernumerary Teeth: a Case Report with 18 months follow-up. *J Contemp Dent Pract.* 2018;19(12):1434–6.
  19. Shih WY, Hsieh CY, Tsai TP. Clinical evaluation of the timing of mesiodens removal. *J Chin Med Association.* 2016;79(6):345–50.
  20. Minguez-Martinez I. Management and outcome following extraction of 303 supernumerary teeth in pediatric patients. *Pediatr Dent.* 2012;34(5):136–9.
  21. Tecco S, Lacarbonara M, Dinoi MT, Gallusi G, Marchetti E, Mummolo S, Campanella V, Marzo G. The retrieval of unerupted teeth in pedodontics: two case reports. *J Med Case Rep.* 2014 Oct 9;8:334. doi: 10.1186/1752-1947-8-334.
  22. Seehra J, Mortaja K, Wazwaz F, Papageorgiou SN, Newton JT, Cobourne MT. Interventions to facilitate the successful eruption of impacted maxillary incisor teeth due to the presence of a supernumerary: A systematic review and meta-analysis. *Am J Orthod Dentofacial Orthop.* 2023 ;163(5):594-608.
  23. Tecco, S., Baldini, A., Mummolo, S., Marzo, G., Gherlone, E.F. Mason C, Azam N, Holt RD, Rule DC. A retrospective study of un- erupted maxillary incisors associated with supernumerary teeth. *Br J Oral Maxillofac Surg* 2000;38:62-5.
  24. Mason C, Azam N, Holt RD, Rule DC. A retrospective study of un- erupted maxillary incisors associated with supernumerary teeth. *Br J Oral Maxillofac Surg* 2000;38:62-5.
  25. Seehra J, Yaqoob O, Patel S, O'Neill J, Bryant C, Noar J, et al. National clinical guidelines for the management of unerupted maxillary incisors in children. *Br Dent J.* 2018;224:779-85.
  26. Becker A. Early treatment for impacted maxillary incisors. *Am J Orthod Dentofacial Orthop* 2002;121:586-7.
  27. Traini T, Pettinicchio M, Murmura G, Varvara G, Di Lullo N, Sinjari B, Caputi S. Esthetic outcome of an immediately placed maxillary anterior single-tooth implant restored with a custom-made zirconia-ceramic abutment and crown: a staged treatment. *Quintessence Int.* 2011;42(2):103-8.
  28. Brauer HU. Case report: Non-syndromic multiple supernumerary teeth localized by cone beam computed tomography. *Eur Arch Paediatr Dent* 2010;11(1):41-43.
  29. Kohn L T, Corrigan J M, Donaldson MS (Institute of Medicine) To err is human: building a safer health system. Washington, DC: Nat> Academy Press, 2000
  30. Bernardi S., Mummolo S., Zeka K., Pajewski L., Continenza M.A., Marzo G. Use and Evaluation of a Cooling Aid in Laser-Assisted Dental Surgery: An Innovative Study. *Photomedicine and Laser Surgery.*2016;34 (6);258 - 262,
  31. Pizzolante, T., Rasicci, P., Saggiomo, A.P., et al. Buccal Fat Pad Flap and Buccal Advancement Flap for Closure of Oroantral Fistula: A Systematic Review and a Case Report. *ORAL and Implantology*, 2024, 16(2);50–61
  32. Falisi G, Foffo G, Severino M, Paolo C, Bianchi S, Bernardi S, Pietropaoli D, Rastelli S, Gatto R, Botticelli G. SEM-EDX Analysis of Metal Particles Deposition from Surgical Burs after Implant Guid- ed Surgery Procedures. *Coatings* 2022; 12: 240.
  33. Bernardi S, Qorri E, Botticelli G, Scarano A, Marzo G, Gatto R, Greco Lucchina A, Mortellaro C, Lupi E, Rastelli C, Falisi G. Use of electrical field for biofilm implant removal. *Eur Rev Med Pharmacol Sci.*2023;27(3)114-121
  34. D'Amario M., De Angelis F., Vadini M., Marchili N., Mummolo S., D'Arcangelo C. Influence of a repeated preheating procedure on mechanical properties of three resin composites. *Operative Dentistry.*2015; 40(2);181 - 189,
  35. Mummolo S., Nota A., De Felice M.E., Marcattili D., Tecco S., Marzo G. Periodontal status of buccally and palatally impacted maxillary canines after surgical- orthodontic treatment with open technique (2018) *Journal of Oral Science.*2015.60(4),552 – 556

36. Memè, L., Bambini, F., Pizzolante, T., ... Bianchi, A., Mummolo, S. Osteonecrosis of the jaw in patients with metastatic renal carcinoma: systematic review and meta-analysis. *ORAL and Implantology*, 2024;16(2);79–87
37. Memè, L., Grilli, F., Pizzolante, T., et al. Clinical and histomorphometric comparison of autologous dentin graft versus a deproteinized bovine bone graft for Socket Preservation. *ORAL and Implantology*, 2024;16(2);101–106
38. Severino, M., Caruso, S., et al. Hand-carried ultrasonography instrumentation in the diagnosis of temporomandibular joint dysfunction. *Methods and Protocols*. 2021;4(4);81
39. Guerra, D., Severino, M., Caruso, S., Rastelli, S., Gatto, R. The importance of using physical tridimensional models for the management and planning of extended osseous odontogenic lesions *Dentistry Journal*. 2021;9(11):134
40. Tecco S., Baldini A., Mummolo S. et al. Frenulectomy of the tongue and the influence of rehabilitation exercises on the sEMG activity of masticatory muscles *Journal of Electromyography and Kinesiology*. 2015;25(4);619-628
41. Brennan, T.A., Leape, L.L., Laird et al., 1991. Incidence of adverse events and negligence in hospitalized patients: results of the Harvard Med. Practice Study I. *N. Engl. J. Med.* 324, 370–376. 1991.
42. Laurance, J., 1991. The case of the wrong tooth. *Am. J. Orthod. Dent. Orthop.* 100, 376–381.
43. Abbott PV, Treatment of external inflammatory root resorption with Ledermix paste. *Aust Endod.* 1999;25;104-5.
44. Abd-Elmeguid A, ElSalhy M, Yu DC. Pulp canal obliteration after replantation of avulsed immature teeth: a systematic review. *Dent Traumatol.* 2015;31(6):437-41.
45. Lee, J.S., Curley, A.W., Smith, R.A., 2007. Prevention of wrong-site tooth extraction: clinical guidelines. *J. Oral Maxillofac. Surg.* 65, 1793–1799
46. Pinchi V, Varvara G, Pradella F. et al. Analysis of professional malpractice claims in implant dentistry in Italy from insurance company technical reports, 2006 to 2010. *Int J Oral Maxillofac Implants.* 2014;29(5):1177-84.
47. Campanella V., Mummolo S., Grazzini F. The effectiveness of endodontic sealers and endodontic medicaments on the elimination of *Enterococcus faecalis*: An in vitro study. *Journal of Biological Regul. and Homeostat. Agents*. 2019;33(3);97 -102,
48. Wu AW, Cavanaugh TA, McPhee SJ, et al: To tell the truth: Ethical and practical issues in disclosing medical mistakes to patients. *J Gen Intern Med* 12:770, 1997
49. Marchetti E., Mummolo S., Mancini L. et al. Decontamination in the dental office: a comparative assessment of a new active principle. *Valutazione di un nuovo principio attivo. Dental Cadmos*. 2012; 89 (3);200 – 206
50. Mummolo S., Severino M., Campanella V. Chlorhexidine gel used as antiseptic in periodontal pockets (2019) *Journal of Biological Regulators and Homeostatic Agents*. 2019.;33(3);83-88
51. Arcuri C., Petro E., Sollecchia G. Laser in periodontal pockets: In vivo and in vitro study (2020) *Journal of Biol. Regul. and Homeost. Agents*, 34 (3);139-146.
52. Scarano A, Piattelli A, Polimeni A. Bacterial adhesion on commercially pure titanium and anatase-coated titanium healing screws: an in vivo human study. *J Periodontol* 2010; 81: 1466-1471.
53. Botticelli G, Calabria E, Severino M. Ultrashort implant in the upper jaw, an alternative therapeutic procedure after the failure of the sinus lift: a case report. *Annali di Stomatologia* 2020; XI: 28-32.
54. Bernardi S., Mummolo S., Ciavarelli L.M., Li Vigni M., Continenza M.A., Marzo G. n Cone beam computed tomography investigation of the antral artery anastomosis in a population of Central Italy *Folia Morphologica (Poland)*. 2016.75(2);149 - 153
55. Mummolo S, Botticelli G, Quinzi V. et al Implant-safe test in patients with peri-implantitis. *J Biol Regul Homeost Agents* 2020; 34: 147-153.
56. Mummolo S., Sapio S., Falco A. et al. Management of pedodontic patients in moderate sedation in clinical dentistry: Evaluation of behaviour before and after treatment. *Journal of Biolog. Regul. and Hom. Agents*. 2020; 34 (1);5 - 62.,
57. Marchetti, E., Pizzolante, T., Americo, L.M., et al. *Europ Journ. of Paediatric Dent.* 2022, 23(4), 332–335
58. Falisi G, Di Paolo C, Rastelli C. et al. Ultrashort Implants, Alternative Prosthetic Rehabilitation in Mandibular Atrophies in Fragile Subjects: A Retrospective Study. *Healthcare* 2021; 9: 175.
59. Falisi G, Bernardi S, Rastelli C, Pietropaoli D, DE Angelis F, Frascaria M, Di Paolo C. “All on short” prosthetic-implant supported rehabilitations. *ORAL Implantol* 2017; 10: 477-487.
60. Scarano A, Bernardi S, Rastelli C, Mortellaro C, Vittorini P, Falisi G. Soft tissue augmentation by means of silicon expanders prior to bone volume increase: a case series. *J Biol Regul Homeost Agents* 2019; 33: 77-84.
61. Quinzi V., Marchetti E., Guerriero L., Bosco F., Marzo G., Mummolo S. Dentoskeletal class II malocclusion: Maxillary molar distalization with non-compliance fixed orthodontic equipment. *Dentistry Journal*. 2020;8 (1), art. no. dj8010026,
62. Quinzi V., Tecco S., Nota A., Caggiati E., Mummolo S., Marzo G. Mesial rotation of the upper first molar: Association with anterior dental crowding in mixed and permanent dentition. *Applied Sciences (Switzerland)*; 2020; 10(15), art. no. 5301

**Giuseppe Varvara, Francesca Angiolani, Fabiola Rinaldi, Davide Gerardi, Sara Bernardi, Sofia Rastelli, Gianluca Botticelli, Tommaso Pizzolante. Complication of the extraction of maxillary anterior supernumerary teeth: the accidental extraction of the permanent tooth bud. *Bulletin of Stomatology and Maxillofacial Surgery*. 2025;21(1):29-35. doi:10.58240/1829006X-2025.1-29**