

ISSN 1829-006X



ԲԱՆԲԵՐ
ՍՏՈՄԱՏՈԼՈԳԻԱՅԻ ԵՎ ԴԻՄԱԾՆՈՏԱՅԻՆ
ՎԻՐԱԲՈՒԺՈՒԹՅԱՆ
Գիտագործնական հանդես
Հատոր 19, թիվ 4

ВЕСТНИК
СТОМАТОЛОГИИ И ЧЕЛЮСТНО-ЛИЦЕВОЙ ХИРУРГИИ
Научно-практический журнал
Том 19, вып. 4

BULLETIN
OF STOMATOLOGY AND MAXILLOFACIAL SURGERY
Scientific and practical journal
Volume 19, No. 4

2023

ԲԱՆԲԵՐ ՍՏՈՄԱՏՈԼՈԳԻԱՅԻ ԵՎ ԴԻՄԱԾՆՈՏԱՅԻՆ

ՎԻՐԱԲՈՒԺՈՒԹՅԱՆ

Գիտագործնական հանդես

Գլխավոր խմբագիր - Հակոբյան Գ.Վ.

Գլխավոր խմբագրի տեղակալ - Տատինցյան Վ.

Գործադիր քարտուղար - Ազատյան Վ.Յու.

Խմբագրական խորհուրդ

Ավետիսյան Գ.Ա., Ենկոյան Կ.Բ., Խաչատրյան Գ.Ա., Եսայան Լ.Կ., Մաթեոսյան Դ.Վ.

Խմբագրական կոլեգիա՝ Ազնատրյան Վ.Ա. (Հայաստան), Աղաջանով Մ.Ի. (Հայաստան), Բակարյան Վ.Լ. (Հայաստան), Բաղդասարյան Ա.Գ. (Հայաստան), Բայկով Ա.Վ. (Հայաստան), Գրիգորյան Կ. Լ. (Հայաստան), Դաշտոյան Թ.Մ. (Հայաստան), Ենոքյան Հ.Դ. (Հայաստան), Հայրապետյան Ա.Դ. (Հայաստան), Կիրակոսյան Վ.Պ. (Հայաստան), Լալայան Կ.Վ. (Հայաստան), Մարգարյան Մ.Մ. (Հայաստան), Պողոսյան Յ.Մ. (Հայաստան), Պողոսյան Ա. Յու. (Հայաստան), Տեր-Պողոսյան Հ. Յու. (Հայաստան), Փափազյան Ա.Թ. (Հայաստան), Վարդանյան Ի.Ֆ. (Հայաստան), Խաչատրյան Գ.Է. (Հայաստան), Հովհաննիսյան Ա.Ռ. (Հայաստան), Սահակյան Ա.Բ. (Հայաստան), Խաչատրյան Ս.Գ. (Հայաստան), Խոտրավերդյան Դ.Ն. (Հայաստան), Խաչատրյան Ս.Գ. (Հայաստան), Հայրապետյան Ա.Դ. (Հայաստան), Մուրադյան Լ.Կ. (Հայաստան), Չիլիֆյան Ա.Ա. (Հայաստան), Սանրիկյան Մ.Է. (Հայաստան), Պապիկյան Ա. Վ. (Հայաստան), Վարդանյան Ա.Ռ. (Հայաստան), Խաչիկյան Խ.Մ. (Հայաստան), Ոսկանյան Լ.Ա. (Հայաստան), Թամանյան Գ.Ն. (Հայաստան), Տատինցյան Լ.Վ. (Հայաստան), Ղարիբյան Ա.Դ. (Հայաստան)

Խմբագրական կոլեգիայի օտարերկրյա անդամներ՝ Մազուր Ի. (Ուկրաինա), Կուզմինա Ի. (Ռուսաստան), Սադեն Ռ. (ՌԴ), Մարգարյան Է. (Ռուսաստան), Ապրեսյան Ս. (Ռուսաստան), Դավիդյան Ա. (Ռուսաստան), Ակուլովիչ Ա. (Ռուսաստան), Կարապետյան Կ. (Ռուսաստան), Էսենբակա Ս. (Ղազախստան), Յավրու-Սակուկ Բ. (ԱՄՆ), Աղանյան Ռ. (Ռուսաստան), Նեյման Հ. (Իսրայել), Դոմինյակ Մ. (Լեհաստան), Դելուիտ Ի. (Ուկրաինա), Գրիչանյուկ Դ. (Բելոռուս), Խարազյան Ա. (Ռուսաստան), Չխադայակով Գ. (Բելոռուս), Մերդոկ Բ. (Արգենտինա), Շիրկով Ն. (Բուլղարիա), Չակարոսի Տ. (Իսրայել), Կրյազնիովա Ի. (Ռուսաստան), Նազարյան Դ. (Ռուսաստան), Նալբանդյա Ս. (Ավստրալիա), Կումար Ռ. (Հնդկաստան), Ստեփանով Ա. (Ռուսաստան), Միլին Ի. (Պարագվայ), Չարրոմնի Լ. (Լեհաստան), Մուզիտ Լ. (Իտալիա), Սպիրիտո Ֆ. (Իտալիա), Ֆիորե Ա. (Իտալիա), Մոստաֆա Մ. (Եգիպտոս), Սինգի Պ. (Հնդկաստան), Քաթիր Է. (Պարագվայ), Շաբան Ա. (Եգիպտոս), Ալ-Օթայբի Մ. (Սաուդյան Արաբիա), Սուլեյմանյան Ա. (Քաթար), Միրբերգեր Գ. (Իտալիա), Ֆունկտես Մ. (Չիլի), Գեհիլ Չ. (ԱՄՆ), Կորեիա Լ. (Պորտուգալիա), Էլբեսիի Ա. (Եգիպտոս), Հուերտոս Ա. (Մեքսիկա), Բոլեն Կ. (Հոլանդիա), Էրզին Վ. (Թուրքիա), Շիբլի Դ. (Բրազիլիա), Նոգոտի Մ. (Իտալիա), Արվես Մ. (Բրազիլիա), Մարվահա.Չ. (Հնդկաստան), Ասրոշկևիչ Վ. (Ռուսաստան), Յարենենկո Ա. (Ռուսաստան), Մարգարյան Ն. (Ռուսաստան), Ռուսանցև Վ. (Ռուսաստան) Հյունինգեն-Հունեն Դ. (Գերմանիա), Չուլիանո Լ. (Իտալիա), Մելքեր Դ. (ԱՄՆ), Ֆերբեր Պ. (Մեծ Բրիտանիա), Դեմիրսկի Գ. (Արժանիա), Գետչա Վ. (Ռուսաստան), Ֆայնբերգ Մ. (ԱՄՆ), Վալենտինի Պ. (Ֆրանսիա), Կիմ Դ. (Ավստրալիա), Վասիլև Յ. (Ռուսաստան), Ինկով Ի. (Բուլղարիա), Ֆերնանդես Ֆ. (Ֆիլիպիններ), Շանմուզանաթան Ս. (Շրի Լանկա), Տրունին Դ. (Ռուսաստան), Կարակով Կ. (Ռուսաստան), Արդելֆաթահ Մ. (Եգիպտոս, ԱՄՆ), Մյուրուպե Ա. Մ. (Հնդկաստան), Բուլիչևա Է. (Ռուսաստան), Ժոզեֆ Ն. (Իսրայել), Բազարիա Ա. (Հնդկաստան), Ֆերնանդես Պ. (Բրազիլիա), Շտորինա Գ. (Ռուսաստան), Չալյան Գ. (Մարդիվներ), Տոմով Գ. (Բուլղարիա), Պերլես Պ. (Ռումինիա), Սերխիտ Ս. (Իտալիա), Սոսկի Կ. (Իտալիա), Աուն Ժ. (Լիբանան), Մարատի Բ. (Թունիս), Գարդոն Ն. (Ֆրանսիա)

Հիմնադիր՝ «ԱԿՈԱ» ՍՊԸ

Հասցե՝ ՀՀ, 375025, Երևան, 0025, Աբովյան փող., 60.

Հեռ.՝ +37491750404

Էլ. փոստ՝ hakobyan_gv@rambler.ru, prom_hg@yahoo.com, stomatologymfsjournal@gmail.com

Կայք՝ <https://stomatology-mfsjournal.com>

Ամսագիրը ինդեքսավորված է միջազգային տվյալների բազաներում Google Scholar, CrossRef, CiteFactor, Scilit (Scientific Literature), Academic Resource Index (ResearchBib), ResearchGate, DOI:

Ինֆորմացիոն հովանավոր ԵՊԲՀ, Վիրաբույժ ստոմատոլոգների և Դիմա-ձնոտային վիրաբույժների, Պարոզոնտոլոգների, Օրթոդոնտների, Ակնաբույժների, Քիթ-Կոկորդ-Ականջաբանների, Մաշկա-վեներաբանների և Մաշկի դերմատոսկոպիայի Հայակական ասոցիացիաները, Հայ Ստոմատոլոգների Միությունը՝ medu.am:

ВЕСТНИК СТОМАТОЛОГИИ И ЧЕЛЮСТНО-ЛИЦЕВОЙ ХИРУРГИИ

Научно-практический журналтом

Главный редактор - Акопян Г.В.
Зам. главного редактора - Татинцян В.Г.
Ответственный секретарь - Азатян В.Ю

Редакционный совет

Аветисян Г.А., Енкоян К.Б., Хачатрян Г.А., Есаян Л.К., Матевосян Д.В.

Редакционная коллегия: Азнаурян В.А. (Армения), Агаджанов М.И. (Армения), Айрапетян А.Д. (Армения), Бакалян В.Л. (Армения), Бадалян А.Г. (Армения), Варданян И.Ф. (Армения), Григорян К.Л. (Армения), Даишоян Т.М. (Армения), Енкоян А.Д. (Армения), Киракосян В.П. (Армения), Лалаян К.В. (Армения), Маркарян М.М. (Армения), Погосян Ю.М. (Армения), Погосян А.Ю. (Армения), Тер-Погосян Г.Ю. (Армения), Папазян А.Т. (Армения), Хачатрян Г.Э. (Армения), Хачатрян С.Г. (Армения), Хачикян Х.М. (Армения), Папикян А.В. (Армения), Оганнисян А.Р. (Армения), Саакян А.Б. (Армения), Худавердян Д. Н. (Армения), Мурадян Л.К. (Армения), Зилфян А.А. (Армения), Манрикийн М.Э. (Армения), Варданя А.Р. (Армения), Азнаурян А.В. (Армения), Байков А.В. (Армения), Восканян Л.А. (Армения), Тамамян Г.Н. (Армения), Татинцян Л.В. (Армения), Гарибян А.Д. (Армения)

Иностранные члены редколлегии: Мазур И. (Украина), Кузьмина И. (Россия), Салеев Р. (Россия), Маргарян Э. (Россия), Апресян С. (Россия), Давидян А. (Россия), Акулович А. (Россия), Карапетян К. (Россия), Эсенбаева С. (Казахстан), Яверу-Сакук Б. (США), Адамаян Р. (Россия), Нойман Х. (Израиль), Доминиак М. (Польша), Двулит И. (Украина), Дмитрий Г. (Беларусь), Харазаян А. (Россия), Чистякова Г. (Беларусь), Мердок Б. (Аргентина), Ширков Н. (Болгария), Чакартчи Т. (Израиль), Кряжинова И. (Россия), Назарян Д. (Россия), Налбандян С. (Австралия), Кумар Р.Ч. (Индия), Степанов А. (Россия), Мильхем И. (Палестина), Задрожны Л. (Польша), Муцио Л. (Италия), Спирито Ф. (Италия), Фьоре А. (Италия), Мостафа М. (Египет), Сингх П. (Индия), Катиб Э. (Палестина), Шабаан А. (Египет), Гехил Ч. (США), Аль-Отаиби М. (Саудовская Аравия), Сукумаран А. (Катар), Силбергер Г. (Италия), Фуэнтес М. (Чили), Коррейя Л. (Португалия), Эльбешихи А. (Египет), Уэрта А. (Мексика), Боллен К. (Нидерланды), Эргин У. (Турция), Шибли Д. (Бразилия), Саркисян Н. (Россия), Румянцев В. (Россия), Нозотти М. (Италия), Алвес М. (Бразилия), Марваха Ж. (Индия), Мирупель А.М. (Индия), Ярёмченко А. (Россия), Хойнинген Хюэн Д. (Германия), Джулиано Л. (Италия), Мелкер Д. (США), Фэйрберн П. (Великобритания), Демираки Г. (Албания), Геча В. (Россия), Файнберг М. (США), Валентини П. (Франция), Ким Д. (Австралия), Василиев Ю. (Россия), Инков И. (Булгария), Фернандес Ф. (Филиппины), Шанмуганатан С. (Шри-Ланка), Трунин Д. (Россия), Караков К. (Россия), Абдельфаттах М. (Египет-США), Булычева Е. (Россия), Багариа А. (Индия), Фернандес П. (Бразилия), Шторина Г. (Россия), Джозеф Н. (Израиль), Залян Г. (Мальдивы), Томов Г. (Болгария), Перлеа П. (Румыния), Спинато С. (Италия), Стакки К. (Италия), Аун Дж. (Ливан), Марави Б. (Тунис), Гардон Н. (Франция)

Учредитель: ООО "АКРА"

Адрес: РА, 375025, Ереван, 0025, ул. Абовяна 60.

Тел.: +37491750404

Эл. почта: hakobyan_gv@rambler.ru, prom_hg@yahoo.com, stomatologymfsjournal@gmail.com

Веб-сайт: <https://stomatology-mfsjournal.com>

Журнал индексируется в международных базах данных Google Scholar, CrossRef, CiteFactor, Scilit (Scientific Literature), Academic Resource Index (ResearchBib), ResearchGate, DOI.

Информационный спонсор: ЕГМУ Армянская ассоциация хирургов-стоматологов и челюстно-лицевых хирургов, Союз Армянских стоматологов, Армянские ассоциации пародонтологов, ортодонтон, офтальмологов, ото-рино-ларингологов, дерматовенерологов, medu.am.

BULLETIN OF STOMATOLOGY AND MAXILLO-FACIL SURGERY

Scientific and practical journal

Editor-in-chief - Hakobyan G.V.
Vice-editor - Tatintsyanyan V.G.
Executive secretary - Azatyan V.Yu.

Editorial council

Avetisyan G.A., Yenokyan K.B., Khachatryan G.A., Yessayan L.K., Matevosyan D.V.

Editorial board: Aznauryan V.A. (Armenia), Agadzhanov M.I. (Armenia), Baykov A.V. (Armenia), Hayrapetyan A.D. (Armenia), Bakalyan V.L. (Armenia), Badalyan A.G. (Armenia), Vardanyan I.F. (Armenia), Grigoryan K.L. (Armenia), Dashtoyan T.M. (Armenia), Yenokyan H.D. (Armenia), Kirakosyan V.P. (Armenia), Lalayan K.V. (Armenia), Margaryan M.M. (Armenia), Pogosyan YU.M. (Armenia), Pogosyan A.YU. (Armenia), Ter-Pogosyan G.YU. (Armenia), Papazyan A.T. (Armenia), Khachatryan G.E. (Armenia), Khachikyan KH.M. (Armenia), Papikyan A.V. (Armenia), Hovhannisyanyan A.R. (Armenia), Saakyan A.B. (Armenia), Khudaverdyan D.N. (Armenia), Muradyan L.K. (Armenia), Zilfyan A.A. (Armenia), Vardanyan A.R. (Armenia), Voskanyan L.A. (Armenia), Tamamyanyan G.N. (Armenia), Tatintsyanyan L.V. (Armenia), Gharibyan A.D. (Armenia), Khachatryan S. (Armenia)

Foreign members of the Editorial Board: Mazur I. (Ukraine), Kuzmina I. (Russia), Saleev R. (Russia), Margaryan E. (Russia), Apresyan S. (Russia), Davidyanyan A. (Russia), Akulovich A. (Russia), Karapetyan K. (Russia), Esenbayeva S. (Kazakhstan), Yavrusakuk B. (USA), Adamanyan R. (Russia), Neumann H. (Israel), Dominiac M. (Poland), Dvulit I. (Ukraine), Dmitry G. (Belarus), Kharazyan A. (Russia), Chistyakova G. (Belarus), Murdoch B. (Argentina), Shirkov N. (Bulgaria), Chakartchi T. (Israel), Kryazimova I. (Russia), Nazaryan D. (Russia), Nalbandyan S. (Australia), Kumar R.Ch. (India), Stepanov A. (Russia), Milhem I. (Palestine), Zadrozny L. (Poland), Muzio L. (Italy), Spirito F. (Italy), Fiore A. (Italy), Mostafa M. (Egypt), Singh P. (India), Katib E. (Palestine), Shabaan A. (Egypt), Al-Otaibi M. (Saudi Arabia), Sukumaran A. (Qatar), Silberberger G. (Italy), Fuentes M. (Chile), Gehil Ch. (USA), Correia L. (Portugal), Elbesihi A. (Egypt), Huerta A. (Mexico), Bollen K. (Netherlands), Ergin W. (Turkey), Shibli D. (Brazil), Sarkisyan N. (Russia), Nozotti M. (Italy), Alves M. (Brazil), Marwaha J. (India), Yaremenko A. (Russia), Heuning-Huen D. (Germany), Giuliano L. (Italy), Melker D. (USA), Fairbairn P. (Great Britain), Demiraki G. (Albania), Getcha V. (Russia), Fainberg M. (USA), Valentini P. (France), Kim D. (Australia), Vasiliev Y. (Russia), Vitaly Rumyantsev (Russia), Inkov I. (Bulgaria), Fernandez F. (Philippines), Shanmuganathan S. (Sri Lanka), Trunin D. (Russia), Karakov K. (Russia), Abdelfattah M. (Egypt), Bulycheva E. (Russia), Bagaria A. (India), Fernandez P. (Brazil), Shtorina G. (Russia), Joseph N. (Israel), Zalyan G. (Maldives), Tomov G. (Bulgaria), Paula P. (Romania), Spinato S. (Italy), Myrupel A.M. (India), Stucky K. (Italy), Aun Dzh. (Lebanon), Maravi B. (Tunisi), Gardon N. (France)

Founder: "AKRA" Ltd.

Address: RA, Yerevan, 0025, Abovyan St., 60.

Phone: +37491403038

E-mail: hakobyan_gv@rambler.ru, prom_hg@yahoo.com, stomatologymfsjournal@gmail.com

Website: <https://stomatology-mfsjournal.com>

The indexed in international databases: Scopus, Google Scholar, CrossRef, CiteFactor, Scilit (Scientific Literature), Academic Resource Index (ResearchBib), ResearchGate, DOI.

Information sponsor: YSMU, Armenian Association of Oral and MFS Surgeons, Armenian Association of Dentists, Periodontists, Orthodontists, Ophthalmologists, Otorhinolaryngologists, Dermatovenerolog, medu.am.

DOI: 10.58240/1829006X-2023.19.4-5



ORIGINAL ARTICLE

**COMPARATIVE ANALYSIS OF THE EFFECT OF ADHESIVE SYSTEMS ON THE
MICROELEMENT COMPOSITION OF THE DENTIN OF THE CROWN PART OF THE
TOOTH**

Galina Chistyakova*

Associate Professor Belarusian State Medical University, Department of Dental Propaedeutics and Materials Science, Minsk, Belarus

* Corresponding author: Galina Chistyakova, Belarusian State Medical University Minsk, Belarus;
e-mail: galinach2018@mail.ru

Received: Oct. 2, 2023; **Accepted:** Oct. 27, 2023; **Published:** Nov. 5, 2023

Abstract

Title: Comparative analysis of the effect of adhesive systems on the microelement composition of the dentin of the crown part of the tooth.

Purpose: To research the microelement composition of the «filling-tooth» interactive zone, the morphological characteristics of its border, to assess the effect of adhesive systems of the V and VII (self-etching) generations on the ion-exchange composition of the dentin of the crown part of the tooth, and to qualitatively assess the microelement composition of the hybrid dentin zone.

Materials and methods: Extracted teeth with preserved crown part (n=20), enamel etching gel (Vladmiva), V generation Singlebond - 2 adhesive system (3M ESPE), self-etching adhesive system Prime-Bond Universal (Dentsply Sirona), light-cured composite material Migrofil (Republic of Belarus). The research of the microstructure of samples with formed and sealed Class I cavities according to Black was carried out on a certified high-resolution scanning electron microscope «Mira» by Tescan (Czech Republic). The research of the microelement composition of the «filling-tooth» border was carried out by X-ray spectral analysis, which consisted of 2 blocks: using the adhesive system of the fifth generation and the seventh generation of the adhesive system.

Conclusions: 1. A comparative analysis of the results of using the fifth-generation adhesive system and the self-etching adhesive system showed that when using the total etching technique, trace elements Ca and P migrate from the tooth dentin structure into the hybrid zone. When using the adhesive system VII, the migration of elements was not established, due to the lack of demineralization of the dentin structure and the modification of the smeared layer. 2. Qualitative assessment of planar spectrograms revealed an increase in the carbon element in the modified adhesive layer. which is due to the presence of a smeared layer after odontopreparation of hard tissues of teeth destroyed by a carious process. 3. The migration of the Si element indicates the chemical interaction of the adhesive and the filling material, as well as the filling material and the dentin of the tooth through the adhesive layer. 4. The use of the adhesive system of the fifth generation provides a higher quality of the marginal fit of the filling material to the surface of the dentin than when using a self-etching adhesive system.

Keywords: adhesive system, trace element composition, hybrid zone.

Introduction

In modern restorative dentistry, adhesive systems are used, designed not only to ensure better adhesion of the filling (micromechanical adhesion), but also to migrate useful microelements into the hard tissues of the tooth (chemical adhesion) and vice versa.^{2,3}

After preparation of the carious cavity, a so-called smear layer is formed on the surface of the dentin, which forms a film 2–10 µm thick on the surface of the dentin, closing the intra- and peritubular spaces of the dentin, thereby preventing the penetration of the components of the adhesive system into its structures. In the early 90s. XX century in dental practice, the sixth and seventh generations of adhesive systems appeared, represented by self-etching systems. Their development for use was determined by the desire of manufacturers to reduce the number of stages of working with adhesive systems and, thereby, reduce the number of dentist errors when working with adhesive systems. The development of the strategy of self-etching of dental tissues was due to the high sensitivity to violations of adhesive preparation when using adhesive systems of the IV and V generations and, as a consequence, the frequent occurrence of postoperative sensitivity. In addition, the use of self-etching systems reduced the number of work steps and, accordingly, reduced the number of errors at the stages of working with the adhesive system.

The advantages of self-etching systems are a shorter adhesive preparation time, a very simple operating procedure, and a low risk of postoperative sensitivity. However, the absence of the stage of etching and removal of the smear layer from the surface of the dentin of the tooth after preparation of the carious cavity doubt remains full. The disadvantages of using self-etching adhesive systems were considered to be large differences in adhesion to enamel and dentin. These indicators, presented by manufacturing companies as higher values than those of the IV and V generations, as well as the low efficiency of etching of intact enamel and sclerotic dentin, the high hydrophilicity and acidity of the components did not always lead to good final results. In connection with the above, when using self-etching systems, a selective etching technique is used.¹ At present, the degree of influence of various adhesive

systems on the ion-exchange composition of dentin of the tooth crown has not been fully revealed.

Thus, studies of the effect of adhesives not only on the structural characteristics of the tooth (components of the hybrid zone), but also on the metabolism of its tissues, in particular, on the mineral component, and the possibility of penetration of tooth microelements into the bonding system, remain relevant.³

This research is aimed at studying the replacement therapy of the tooth crown in the context of establishing the microelement composition of the dentin of the crown of the tooth after restoration using adhesive systems of the V and VII (self-etching) generations in vitro.

Purpose

The purpose of the work was to research the microelement composition of the interactive «filling-tooth» zone, the morphological characteristics of its border, to assess the influence of adhesive systems of the V and VII (self-etching) generations on the ion-exchange composition of dentin in the coronal part of the tooth and to qualitatively assess the microelement composition of the hybrid dentin zone.

Materials and methods

Research materials: extracted teeth with the crown part preserved (n=20), gel for etching enamel (Vladmi-va), fifth generation adhesive system Singlebond - 2 (3M ESPE), self-etching adhesive system Prime-Bond Universal (Dentsply Sirona), light-curing composite material Migrofil (Republic of Belarus). The experiment used teeth removed for medical reasons. The score of tested samples for the research is divided into two groups: group 1 (n=10) and group 2 (n=10) - experimental with cavities of Black class I formed, depending on the type of adhesive system used. In the first group, total etching and a fifth-generation adhesive system were used to fill cavities; in the second experimental group, a seventh generation (self-etching) adhesive system was used. After filling, the teeth were placed in a thermostat for 72 hours at a temperature of 37°C and 100% humidity. To obtain samples, longitudinal and transverse cuts of the tooth crown were made.

The microstructure of the samples was studied using a certified high-resolution scanning electron microscope «Mira» from Tescan (Czech Republic) with a field emission cathode. To research in a scanning electron microscope, the surface of polished sections of tooth samples was sprayed with conductive cathode chromium under vacuum conditions for 10 s. The research of the elemental composition was carried out using a micro-X-ray spectral analyzer from Oxford Instruments (England).

Sections of tooth samples were placed in a scanning electron microscope camera for X-ray spectral analysis at various magnifications.

The scanning areas were the following zones: «composite material - adhesive layer - hybrid zone - dentin».

The research of the microelement composition of the «filling-tooth» interface was carried out using X-ray spectral analysis, which consisted of 2 blocks:

1-block

1-block: Micro-X-ray spectral analysis of the «filling-tooth» boundary when using the fifth generation of adhesive system.





Figure 1. Scanning area within which MRSA was performed (1 block of the research - when using the V generation adhesive system)

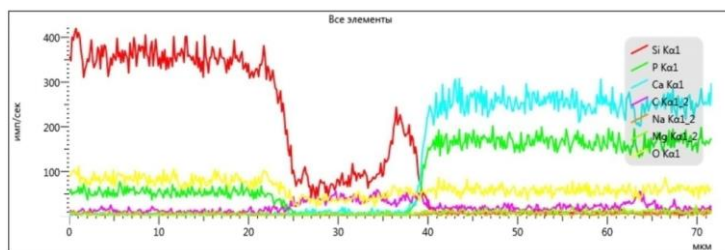


Figure 2. Planar spectrogram 1 - Concentration curves of distribution of elements (1 block of research - when using adhesive system of the fifth-generation)

The figure 1 shows the scanning area of the test sample of block 1.

Based on the sounding performed, planar spectrogram 1 was obtained (Figure 2), which reflects the microelement composition in the scanning area.

Interpretation of planar spectrogram 1.

On the Oy axis: changes in the intensity value of the secondary characteristic radiation excited by a directed electron beam within the designated scanning line. The line thickness is about 1 μm. On the Ox axis: distance and total length of the scan line in 1 μm.

Research Results of the 1-block

- 1) Concentration curves of the following elements were obtained: Si, P, Ca, C, Na, Mg. Migration is determined only for Si, P, Ca.
- 2) Qualitative analysis of planar spectrograms in filling areas using V generation adhesive systems revealed accumulation of P and especially Ca in the hybrid zone. The increased concentration of Ca in the hybrid zone is primarily due to decalcification of dentin after exposure to 37% orthophosphoric acid. At the border of the adhesive layer and the filling material, a high concentration of trace elements calcium and phosphorus was also established, but trace elements such as Si, P, Ca, C, Na, Mg were also identified. Interactive zones, where a dense contact zone is established, confirms the presence of chemical adhesion, which is determined by the mutual penetration of elements from the adhesive system into the structure of the material, and vice versa. The chemical interaction of the adhesive and the filling material, as well as the filling

material and tooth dentin through the adhesive layer is evidenced by the migration of the Si element (Figure 1).

2-block

2-block: Micro-X-ray spectral analysis of the «filling-tooth» interface using a self-etching adhesive system.

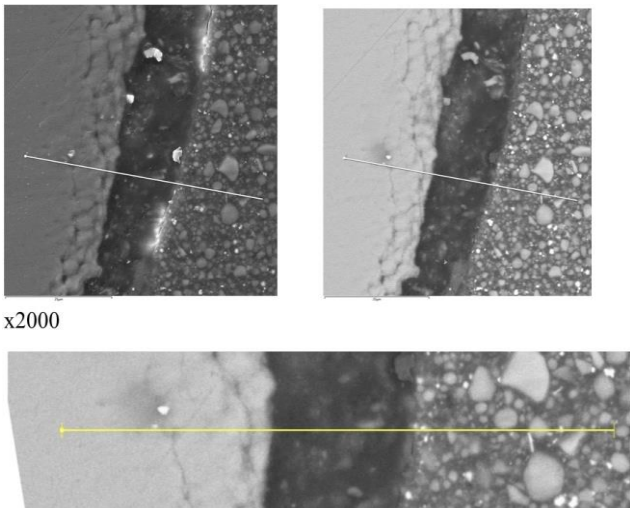


Figure 3. Scanning area within which MRSA x2000 was performed (2 block of the research - when using a self-etching adhesive system)

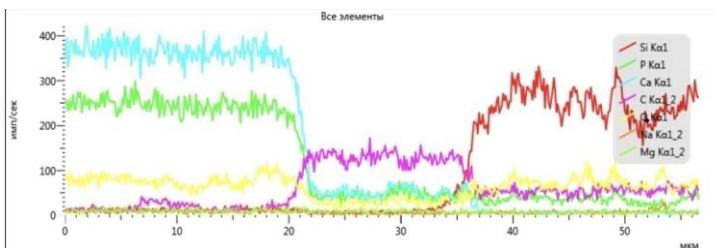


Figure 4. Planar spectrogram 2. Concentration curves of distribution of elements (2 block of research - when using a self-etching adhesive system)

The interpretation of Figure 3 and planar spectrogram 2 (Figure 4) is similar to the interpretation of Figure 1 and planar spectrogram of block 1.

Research Results of the 2-block

- 1) Concentration curves of the elements Si, P, Ca, C, Na, Mg were obtained. Traces of microelements Si, P, Ca are determined in the modified zone.
- 2) A qualitative analysis of spectrogram 2 revealed the absence of Ca and P in the hybrid zone in a comparative analysis with spectrogram 1 when using the fifth-generation adhesive system, which is due to the non-removal of the smear layer, and the modification of the smear layer when using a self-etching adhesive system.

Discussion

In this research, it is not possible to assess the migration of microelements, as well as the depth of their penetration, but it allows us to give a qualitative assessment of the migration of microelements from the adhesive system to dentin and in the opposite direction.

Qualitative analysis of the spectrogram revealed the absence of Ca and P in the hybrid zone, which is due to the presence of a modified smear layer when using a self-etching adhesive system.

Figures 5 and 6 show sections of teeth showing the «filling-tooth» boundary when using the fifth-generation adhesive system (Figure 5) and a self-etching adhesive system (Fig. 6). A qualitatively tighter fit of the filling material and the adhesive system was established in samples using the V generation of the adhesive system (Figure 5). When analyzing samples from the second block of research (using a self-etching adhesive system), areas of impaired contact of the modified adhesive layer with the surface of the dentin of the tooth were identified, as well as single areas of impaired contact of the modified adhesive layer with the filling material (Figures 3, 6). During the analysis of planar spectrograms, an increase in element C in the zone of modified adhesive layer, which is due to the presence of a smear layer after odontopreparation.




Figure 5. Section of the «filling-tooth» border when using the adhesive system of the V generation




Figure 6. Section of the «filling-tooth» border when using the adhesive system of the VII generation

Thus, during the research was established that the sealing density of the filling to the dentin when using a self-etching adhesive system is lower than when using a V generation adhesive system, which is due to the modification of the smear layer on the dentin surface after odontopreparation.

When conducting comparative analysis of the results, it was found that only when using the fifth-generation adhesive system does migration of trace elements Ca and P occur from the structure of tooth dentin into its hybrid zone, as well as migration of the element Si from the filling material through the adhesive layer into tooth dentin. The data obtained are combined with previously conducted studies in the mode of total etching of hard dental tissues.³

Conclusions

Based on the results of the research, we formulated the following conclusions:

1. A comparative analysis of the results of using the fifth-generation adhesive system and a self-

etching adhesive system showed that when using the total etching technique, trace elements Ca and P mi-grate from the tooth dentin structure to the hybrid zone.

When using the VII generation adhesive system, no migration of elements was detected due to the lack of demineralization of the dentin structure and the formation of a modified smear layer.

2. A qualitative assessment of planar spectrograms revealed an increase in the carbon element in the modified adhesive layer. which is due to the presence of a smear layer after odontopreparation of hard dental tissues destroyed by the carious process
3. Migration of the Si element indicates the chemical interaction of the adhesive and the filling material, as well as the filling material and tooth dentin through the adhesive layer.
4. The use of a V generation adhesive system ensures a higher quality of marginal seal of the filling material to the dentin surface than when using a self-etching adhesive system.

Declarations

Conflict of interest and financial disclosure

The author declares that he has no conflict of interest and there was no external source of funding for the present study. None of the authors have any relevant financial relationship(s) with a commercial interest.

Ethical approval

Research protocol was approved by the local Ethical Committee (2018/23) and in accordance with those of the World Medical Association and the Helsinki Declaration.

Informed consent

Informed consent was obtained from all individual participants included in the study.

Source of Funding

Non funding.

Availability of Data and Materials

Not applicable.

REFERENCES

1. Hramchenko SN, Kazeko LA, Goreglyad AA. Sovremennye adgezivnye sistemy. *Uchebno-metodicheskoe posobie. Minsk: BGMU. 2008;2:47*
2. Chistyakova GG, Sahar GG, Koltun KG, Sikorskogo AV, Doroninoy OK. Innovacii v medicine i farmacii - 2016. *Materialy distancion. nauch.-prakt. konf. studentov i molodyh uchenyh, Minsk, Belorus. gos. med. un-t. pod red. BGMU. 2016;513-517*
3. Chistyakova GG. Ocenka adgezionnoj svyazi fotokompozitov s tvyordymi tkanyami koronok zubov na osnovanii metoda skaniruyushchej elektronnoj mikroskopii i mikrorentgenospektral'nogo analiza. *Sovremennaya stomatologiya Minsk. 2019;4:56*

ԱՏԱՄԻ ՊՍԱԿԻ ԴԵՆՏԻՆԻ ՄԻԿՐՈՏԱՐՐԵՐԻ ԿԱԶՄԻ ՎՐԱ ԱԴՂՇԵԶԻՎ ՀԱՄԱԿԱՐԳԵՐԻ ԱԶԴԵՑՈՒԹՅԱՆ ՀԱՄԵՄԱՏԱՏՎԱՆ ՎԵՐԼՈՒԾՈՒԹՅՈՒՆ

Գալինա Չիստյակովա

Բելառուսի պետական բժշկական համալսարանի ստոմատոլոգիական պրոպեդևտիկայի և նյութագիտության ամբիոնի դոցենտ, Մինսկ, Բելառուս

Ամփոփում

Նպատակը. Ուսումնասիրել «լցանյութ-ատամ» ինտերակտիվ գոտու միկրոտարրերի կազմը, դրա եզրագծի մորֆոլոգիական բնութագրերը, գնահատել V և VII սերնդի ադեզիվ համակարգերի ազդեցությունը իոնափոխանակման բաղադրության վրա, ատամի դենտինի և դենտինի հիբրիդային գոտու միկրոտարրերի բաղադրության որակական գնահատում:

Նյութեր և մեթոդներ. Հեռացված ատամներ՝ պահպանված պակով (n=15), էմալը մշակելու համար նախատեսված գել (Վլադմիր), հինգերորդ սերնդի ադեզիվ համակարգ Singlebond - 2 (3M ESPE), բոնդ Prime-Bond Universal (Dentsply Sirona), լուսակարածրացող կոմպոզիտային նյութ Migrofil (Բելառուսի Հանրապետություն): I դասի ձևավորված և լցված խոռոչներով նմուշների միկրոկառուցվածքի ուսումնասիրությունը՝ ըստ Black-ի, իրականացվել է Tescan-ի (Չեխիա) հաստատված սկանավորող էլեկտրոնային մանրադիտակի միջոցով (Չեխիա):

«Լցանյութ-ատամ» ինտերակտիվ գոտու ուսումնասիրությունը իրականացվել է ռենտգենյան սպեկտրային անալիզով, որը բաղկացած է եղել 2 բոլկից՝ օգտագործելով հինգերորդ սերնդի ադեզիվ համակարգ և յոթերորդ սերնդի ադեզիվ համակարգ:

Եզրակացություններ. 1. Հինգերորդ սերնդի ադեզիվ համակարգի և ինքնակող ադեզիվ համակարգի արդյունքների համեմատական վերլուծությունը ցույց է տվել, որ ընդհանուր մշակման տեխնիկա կիրառելիս Ca և P միկրոտարրերը ատամի դենտինի կառուցվածքից տեղափոխվում են հիբրիդային գոտի:

VII սերնդի ադեզիվ համակարգ օգտագործելիս տարրերի միգրացիա չի հայտնաբերվել դենտինի կառուցվածքի դեմինալիզացիայի և քսուքի շերտի փոփոխության պատճառով:

2. Պլանային սպեկտրոգրամների որակական գնահատումը բացահայտեց փոփոխված ադեզիվ շերտում ամֆաժնի տարրի ավելացում, ինչը պայմանավորված է կարիեսային պրոցեսից քայքայված ատամի կոշտ հյուսվածքների օդոնտոպատրաստումից հետո քսուքի շերտի առկայությամբ:

3. Si տարրի միգրացիան ցույց է տալիս ադեզիվ և լցանյութի, ինչպես նաև լցանյութի և ատամի դենտինի քիմիական փոխազդեցությունը ադեզիվ շերտի միջով:

4. V սերնդի ադեզիվ համակարգի օգտագործումը ապահովում է լցանյութի մարզինալ կաշունության ավելի բարձր որակ դենտինի մակերեսին, քան ինքնակող ադեզիվ համակարգ օգտագործելիս:

КОМПАРАТИВНЫЙ АНАЛИЗ ВЛИЯНИЯ АДГЕЗИВНЫХ СИСТЕМ НА МИКРОЭЛЕМЕНТНЫЙ СОСТАВ ДЕНТИНА КОРОНКОВОЙ ЧАСТИ ЗУБА

Галина Чистякова

Доцент Белорусского государственного медицинского университета, кафедра стоматологической пропедевтики и материаловедения, Минск, Беларусь

Абстракт

Цель: Исследование микроэлементного состава интерактивной зоны «пломба-зуб», морфологической характеристики ее границы, оценка влияния адгезивных систем V и VII (самопротравливающего) поколений на ионно-обменный состав дентина коронковой части зуба и качественная оценка микроэлементного состава гибридной зоны дентина.

Материалы и методы: Экстрагированные зубы с сохранённой коронковой частью (n=15), гель для травления эмали (Владмива), адгезивная система V поколения Singlebond - 2 (3M ESPE), самопротравливающая адгезивная система Prime-Bond Universal (Dentsply Sirona), светоотверждаемый композиционный материал Мигрофил (Республика Беларусь). Исследование микроструктуры образцов со сформированными и запломбированными полостями I класса по Блэку проводили на аттестованном сканирующем электронном микроскопе высокого разрешения «Mira» фирмы «Tescan» (Чехия) Исследование микроэлементного состава границы «пломба-зуб» проводили методом рентгеноспектрального анализа, которое состояло из 2 блоков: с применением адгезивной системы V поколения и VII поколения адгезивной системы.

Выводы: 1. Компаративный анализ результатов использования адгезивной системы V поколения и самопротравливающей адгезивной системы показал, что при использовании техники тотального травления происходит миграция микроэлементов Са и Р из структуры дентина зуба в гибридную зону.

При использовании адгезивной системы VII миграции элементов не установлено, из-за отсутствия деминерализации структуры дентина и модификации смазанного слоя.

2. При качественной оценке планарных спектрограмм установлено повышение элемента углерода в модифицированном адгезивном слое. что обусловлено присутствием смазанного слоя после одонтопрепарирования твердых тканей зубов, деструктированных кариозным процессом

3. Миграция элемента Si свидетельствует о химическом взаимодействии адгезива и пломбировочного материала, а также пломбировочного материала и дентина зуба через слой адгезива.

4. Использование адгезивной системы V поколения обеспечивает более высокое качество краевого прилегания пломбировочного материала к поверхности дентина, чем при использовании самопротравливающей адгезивной системы.

DOI: 10.58240/1829006X-2023.19.4-12



ORIGINAL ARTICLE

PREVALENCE AND MORPHOLOGY OF MIDDLE MESIAL CANAL AND MIDDLE DISTAL CANAL IN MANDIBULAR FIRST MOLARS IN NORTH INDIAN SUBPOPULATION: A RETROSPECTIVE CBCT ANALYSIS

Harpreet Singh,¹ Urvashi Saggar,² Rishu Gautam,³ Rajiv K. Chugh^{4*}

- ¹ Dean Research, Professor and Head, Conservative Dentistry & Endodontics, Baba Jaswant Singh Dental College and Hospital, Ludhiana
- ² Post Graduate Student, Conservative Dentistry & Endodontics, Baba Jaswant Singh Dental College, Hospital and Research Institute, Ludhiana
- ³ Reader, Conservative Dentistry & Endodontics, Baba Jaswant Singh Dental College, Hospital and Research Institute, Ludhiana
- ⁴ Visiting Professor, Sibar Institute of Dental Sciences, Guntur, Private Practice, New Delhi

* Corresponding author: Dr. Rajiv K. Chugh, National President, Indian Dental Association Visiting Professor, Sibar Institute of Dental Sciences, India Section, Dr. Chugh's Dental Centre W-5 Greater Kailash Part I New

Delhi – 110048;

Tel: 01129233119, 01129233974;

e-mail: drchughs@gmail.com

Received: Oct. 2, 2023; **Accepted:** Oct. 27, 2023; **Published:** Nov. 5, 2023

Abstract

Aim: The aim of the study was to evaluate the prevalence and morphology of the middle mesial canal and middle distal canal in mandibular first molars in North Indian subpopulation using Cone Beam Computed Tomography.

Methodology: 60 Cone Beam Computed Tomography (CBCT) scans were retrospectively analyzed out of which 40 mandibular first molars were included in this study as per inclusion and exclusion criteria. The collected CBCT scans were observed for the presence of middle mesial and middle distal canal in mandibular first molars. The root canal configuration of the middle mesial and middle distal canals in the mandibular first molars was then observed in axial and coronal sections of CBCT scans.

Results: Out of total 40 examined mandibular first molars, the prevalence of middle mesial canal in mandibular first molar was found out to be 5% and the prevalence of middle distal canal in mandibular first molar was found out to be 10%. The confluent configuration was the most common root canal configuration type of both middle mesial and middle distal canal.

Conclusion: Locating middle mesial and middle distal canal is imperative in order to achieve good endodontic prognosis for mandibular first molars. CBCT analysis remains as a non-invasive and clinically effective tool for determining root canal morphology. Knowing the incidence of variations in root canal anatomy is crucial for alerting doctors to the possibility of encountering them in clinical practice.

Keywords: Cone beam computed tomography, Mandibular first molar, Middle mesial canal, Middle distal canal, Root canal anatomy.

Introduction

The main goal of endodontic therapy is to thoroughly debride the entire root canal system by the means of cleaning, shaping, and disinfection allowing for three-dimensional obturation of the root canal system.¹ However, the intricacy of root canal architecture creates clinical hurdles and problems that frequently jeopardize the fundamental purpose of endodontic therapy.² Knowledge of the variations in root canal anatomy can directly affect the success rate of root canal treatment, thus making it highly essential to understand such variations.

In the oral cavity, the mandibular first molar is the first permanent tooth to erupt at the age of 6-7 years, exposing it to earlier decay leading to the requirement of endodontic treatment.³ Various anatomic variations are present in mandibular first molars such as additional roots, extra canals, isthmuses, lateral canals and apical ramifications.³

The classic literature describes the presence of two canals in the mesial root of mandibular first molar, although the first evidence of an independent third mesial canal called as middle mesial canal (MMC) with its own access orifice and apical foramen was described by Vertucci and Williams⁴ and by Barker et al.⁵ Middle distal canal was first reported by Martinez Berna and Badanelli.⁶ Pomeranz et al. classified MMCs into three types (a) independent, (b) fin or (c) confluent as depicted in Figure 1.⁷

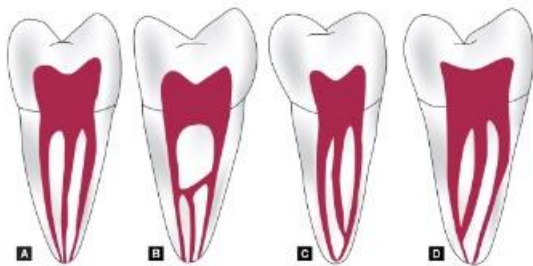


Figure 1. Pomeranz et al., middle mesial canal classification showing (a) independent configuration, (b) fin configuration, (c) confluent configuration to mesiobuccal canal and (d) to mesiolingual canal

Several methodologies have been used to study the root canal system configuration of the first mandibular molar. Cone Beam Computed Tomography (CBCT) scans have recently shown to be quite a valuable aid in various stages of endodontic treatment and in

identifying anatomical variations because close to accurate three-dimensional radiographic images can be obtained by this technique.^{8,9}

Therefore, the purpose of this study was to use CBCT radiographic imaging to find the prevalence and canal configuration of middle mesial and middle distal canal in mandibular first molars.

Methodology

60 Cone Beam Computed Tomography Scans were procured from Baba Jaswant Singh Dental College, Hospital and Research Institute. CBCT scans were performed with a CBCT Machine (Dentsply Sirona Orthophos S, Figure 2). Images were examined using SIDEXIS 4 viewer.



Figure 2. CBCT Machine (Dentsply Sirona Orthophos S)

CBCT scans having intact mandibular first molars with two roots, fully formed apices were included in the study. CBCT scans that lacks clarity and presence of scatter producing elements were excluded. Also, the CBCT scans having mandibular first molars with root surface caries, resorptive defects were excluded.

After applying inclusion and exclusion criteria, 40 mandibular first molars were included in the study and samples were numbered from 1 to 40. From the scans, the axial and coronal sections of mandibular first molars were observed for the presence of middle

mesial and middle distal canal. Morphological pattern was noted and classified using Pomeranz et al. classification.

Results

The total number of mandibular first molars examined were 40 and the middle mesial canal was found in sample number 5 and 33 (Figure 3), corresponding to a prevalence of 5% (Table 1) and middle distal canal was found in sample number 11,20,27 and 34 (Figure 5) corresponding to the prevalence of 10% (Table 1).

Table 1: Prevalence of Middle Mesial and Middle Distal canal in Mandibular first molars

Canal	Number of teeth
MIDDLE MESIAL CANAL (MMC)	02 (5%)
MIDDLE DISTAL CANAL (MDC)	04 (10%)

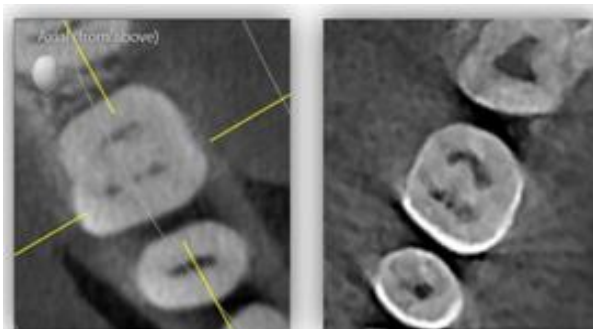


Figure 3. Middle mesial canal seen in axial section of CBCT scan

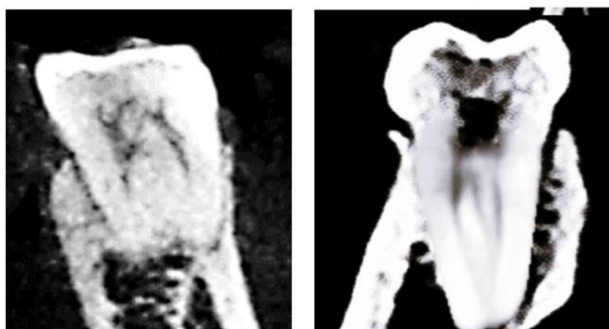


Figure 4. Middle mesial canal seen in coronal section of CBCT scan

While the canal configuration of middle mesial was observed to be a confluent configuration into mesiolingual canal (Figure 4), the canal configuration

of middle distal canal was found to be a confluent configuration into distolingual canal (Figure 6).

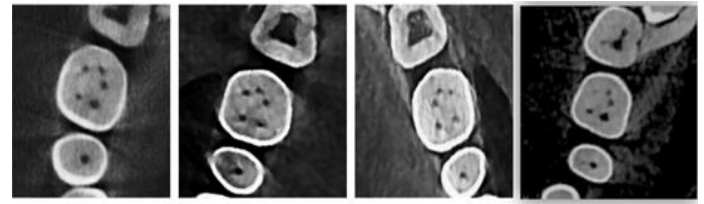


Figure 5. Middle distal canal seen in axial section of CBCT scan

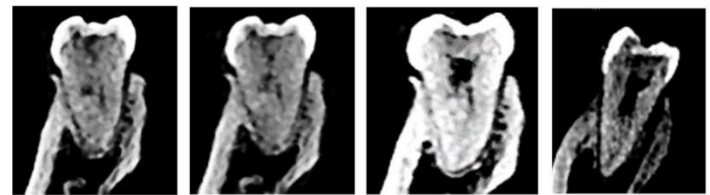


Figure 6. Middle distal canal seen in coronal section of CBCT scan

The prevalence of middle distal canal in mandibular first molar was higher as compared to the prevalence of middle mesial canal in the present study.

The canal configurations of middle mesial and middle distal canals are tabulated in Table 2 and Table 3 respectively.

Table 2: Morphology of Middle Mesial Canal in mandibular first molar

Sample Number	Morphology
MMC (05)	Confluent configuration to ML
MMC (33)	Confluent configuration to ML

Table 3: Morphology of Middle Distal Canal in mandibular first molar

Sample Number	Morphology
MDC (11)	Confluent configuration to DL
MDC (20)	Confluent configuration to DL
MDC (27)	Confluent configuration to DL
MDC (34)	Confluent configuration to DL

Discussion

Understanding the internal anatomy of the teeth holds paramount significance for the general dentist and more to an endodontist. Mandibular first molars

owing to its high incidence of carious involvement is commonly referred for an endodontic treatment. The most common cause of endodontic treatment failure in molars is missed canals, unable to recognize unusual canal configuration and incomplete instrumentation. Therefore, it is highly essential that the clinicians possess thorough knowledge of the root canal anatomy for the successful endodontic outcomes.

Conventional radiography presents with the limitation of being two dimensional in nature thus being of limited help in endodontic practice. With the advancement in research and technology, the introduction of three-dimensional imaging techniques has provided accurate visualization of the pulpal anatomy. CBCT provides an excellent, non-destructive, non-invasive imaging option with the potential to detect most anatomic variations, while creating an accurate representation of the external and internal dental anatomy.

The current study was done to evaluate the prevalence and root canal configuration of middle mesial and middle distal canal in mandibular first molars in North Indian subpopulation using cone beam computed tomography. In the present study the prevalence of the middle mesial canal was observed to be 5%. Among the anatomic variations, the presence of middle mesial canal in mandibular molars has been reported in the literature with the prevalence ranging from be 0.26% to 53.8%. [10] Costa et al. reported the prevalence of middle mesial canal in mandibular first molar to be 11.1% in Brazilian subpopulation.¹¹ Another study by Iqbal et al. reported the prevalence of middle mesial canal to be 29.7% which is quite higher as compared to the results of the present study.¹⁴

Also, in the present study, the prevalence of the middle distal canal was observed to be 10%. Tredoux et al. reported the prevalence of Middle distal canals in over 7% of mandibular first molars which is lower as compared to the results of the current study.¹² It is worth mentioning here that in the present study, the prevalence of MDC (10%) was found to be higher as compared to the prevalence of middle mesial canal (5%), which is bit unusual.

In the present study, the canal configuration of middle mesial canal was found out to be confluent into mesiolingual canal. While in a study by Costa et al., the most frequent canal configuration was

independent type,¹¹ Inaty et al. in their research work, reported the configuration of middle mesial canal to be confluent to mesiobuccal canal.¹⁴

The findings in our research work are a mixed observation with few things similar to the previous studies, while some findings are quite different from the ones observed and reported earlier.

Having said that, it is to be understood that there is a significant prevalence of middle mesial and middle distal canals in mandibular first molars. Thus, it is essential that the further studies be carried out with a larger sample size in order to obtain more data about this morphological variation, so as to help the clinicians understand better of the morphology of root canal system of mandibular first molars.

Conclusion

The presence of middle mesial canal and middle distal canal is a significant variation to be found in mandibular first molars. In our study a prevalence of 5% and 10% of middle mesial canal and middle distal canal was observed respectively. A better understanding of root canal morphology can significantly reduce the errors encountered in access cavity preparation, cleaning and shaping and obturation, of the root canal system, thereby enhancing the success rate of endodontic therapy.

Declarations

Conflict of interest and financial disclosure

The author declares that he has no conflict of interest and there was no external source of funding for the present study. None of the authors have any relevant financial relationship(s) with a commercial interest.

Ethical approval

Research protocol was approved by the local Ethical Committee (2018/23) and in accordance with those of the World Medical Association and the Helsinki Declaration.

Informed consent

Informed consent was obtained from all individual participants included in the study.

Source of Funding

Non funding.

Availability of Data and Materials

Not applicable.

REFERENCES

1. Schilder H. Filling Root Canals in Three Dimensions. *Journal of Endodontics*. 2006;32(4):281–290. doi:10.1016/j.joen.2006.02.007
2. Hess W. Formation of Root-Canals in Human Teeth. *The Journal of the National Dental Association*. 1921;8(9):704–734. doi:10.14219/jada.archive.1921.0179
3. Reyhani MF, Rahimi S, Shahi S. Root canal therapy of a mandibular first molar with five root canals: A case report. *Iran Endod J*. 2007;2(3):110-112
4. Vertucci FJ, Williams RG. Root canal anatomy of the mandibular first molar. *Journal of the New Jersey Dental Association*. 1974;45(3):27-8
5. Barker BCW, Lockett BC, Parsons KC. The demonstration of root canal anatomy. *Australian Dental Journal*. 1969;14(1):37–41. doi:10.1111/j.1834-7819.1969.tb03330.x
6. Martínez-Berná A, Badanelli P. Mandibular first molars with six root canals. *Journal of Endodontics*. 1985;11(8):348–352. doi:10.1016/s0099-2399(85)80043-1
7. Pomeranz HH, Eidelman DL, Goldberg MG. Treatment considerations of the middle mesial canal of mandibular first and second molars. *Journal of Endodontics*. 1981;7(12):565–568. doi:10.1016/s0099-2399(81)80216-6
8. Di Nardo D, Gambarini G, Piasecki L, Ropini P, Miccoli G, Testarelli L. Cone-beam computed tomographic analysis on root and canal morphology of mandibular first permanent molar among multiracial population in Western European population. *European Journal of Dentistry*. 2018;12(3):434. doi:10.4103/ejd.ejd_116_18
9. Erkan E, Olcay K, Eyuboglu TF, Sener E, Gundogar M. Assessment of the Canal Anatomy of the Mandibular Molars in a Group of Turkish Patients: A Cone-Beam Computed Tomography Study. *Van Sağlık Bilimleri Dergisi*. 2023;16(1):44-52. doi:10.52976/vansaglik.1162256
10. Bansal R, Hegde S, Astekar M. Morphology and prevalence of middle canals in the mandibular molars: A systematic review. *J Oral Maxillofac Pathol*. 2018;22(2):216-226. doi:10.4103/jomfp.JOMFP_194_17
11. Barros-Costa M, Ferreira MD, Costa FF, Freitas DQ. Middle mesial root canals in mandibular molars: prevalence and correlation to anatomical aspects based on CBCT imaging. *Dentomaxillofacial Radiology*. 2022;51(8):20220156. doi:10.1259/dmfr.2022015
12. Tredoux S, Warren N, Buchanan GD. Root and canal configurations of mandibular first molars in a South African subpopulation. *Journal of Oral Science*. 2021;63(3):252-256. doi:10.2334/josnusd.20-0651
13. Iqbal S, Kochhar R, Kumari M. Prevalence of middle mesial canal in the Indian subpopulation of Greater Noida and the related variations in the canal anatomy of mandibular molars using cone-beam computed tomography. *Endodontology*. 2022;34:50-4. doi:10.4103/endo.endo_108_21
14. Inaty E, Jabre C, Haddad G, et al. Anatomical investigation of middle mesial canals of mandibular molars in a middle eastern population: A cross-sectional cone-beam computed tomography study. *The Journal of Contemporary Dental Practice*. 2020;21(8):911

**ՄԻՋԻՆ ՄԵԳԻՎԼ ԱՐՄԱՏԱԽՈՂՈՎԱԿԻ և ՄԻՋԻՆ ՀԵՌԱՎՈՐ ԱՐՄԱՏԱԽՈՂՈՎԱԿԻ
ՏԱՐԱԾՎԱԾՈՒԹՅՈՒՆԸ և ՄՈՐՓՈԼՈԳԻԱՆ ՀՅՈՒՄԻՍԱՅԻՆ ՀՆԴԱԿԿԱՆ
ԵՆԹԱԳՈՊՈՒԼՅԱՑԻԱՅԻ ՍՏՈՐԻՆ ԾՆՈՏԻ ԱՌԱՋԻՆ ԱՂՈՐԻՔՆԵՐԻ ՄԵՉ. ՀԵՏԱՀԱՅԱՑ ՇՄՏ
ՎԵՐԼՈՒԾՈՒԹՅՈՒՆ**

Հարսիթ Մինգի,¹ Ուրվաշի Սագգար,² Ռիշու Գաութամ,³ Ռաջիվ Կ Չուղ⁴

- ¹ Հետազոտությունների Դեկան, պրոֆեսոր Պահպանողական ստոմատոլոգիա և էնդոդոնտիայի ամբիոնի վարիչ, Բարա Չասվանտ Մինգի ստոմատոլոգիական քոլեջ և հիվանդանոց, Լուդիանա
- ² Ասպիրանտ, Պահպանողական ստոմատոլոգիայի և էնդոդոնտիայի ամբիոն, Բարա Չասվանտ Մինգի ստոմատոլոգիական քոլեջ, հիվանդանոց և գիտահետազոտական ինստիտուտ, Լուդիանա:
- ³ Ընթերցող, Պահպանողական ստոմատոլոգիայի և էնդոդոնտիայի ամբիոն, Բարա Չասվանտ Մինգի ստոմատոլոգիական քոլեջ, հիվանդանոց և գիտահետազոտական ինստիտուտ, Լուդիանա:
- ⁴ Հրավիրիչ պրոֆեսոր, Միբար ստոմատոլոգիական գիտությունների ինստիտուտ, Գյունթուր, մասնավոր պրակտիկա, Նյու Դելի

Ամփոփում

Նպատակը. Հետազոտության նպատակն էր գնահատել մեդիալ արմատախողովակի և միջին հեռավոր արմատախողովակի տարածվածությունը և մորֆոլոգիան Հյուսիսային Հնդկական ենթապոպուլյացիայի ստորին ծնոտի առաջին աղորիքների մեջ՝ օգտագործելով կոնճառագայթային տոմոգրաֆիա (ՇՄՏ):

Մեթոդաբանություն. 60 ՇՄՏ սկանավորումներ հետահայաց վերլուծվել են, որոնցից 40-ը ստորին ծնոտի առաջին աղորիքները ներառվել են այս հետազոտության մեջ՝ ըստ ներառման և բացառման չափանիշների: Հավաքված ՇՄՏ սկանավորումները դիտվել են ստորին ծնոտի առաջին աղորիքների մեջ մեդիալ արմատախողովակի և միջին հեռավոր արմատախողովակի առկայության համար: Ստորին ծնոտի առաջին աղորիքների մեջ մեդիալ արմատախողովակի և միջին հեռավոր արմատախողովակի կոնֆիգուրացիան այնուհետև դիտարկվել է ՇՄՏ սկանավորման առանցքային և կորոնայ հատվածներում:

Արդյունքներ. Ստորին ծնոտի առաջին աղորիքների ընդհանուր 40 հետազոտվածից միջին հեռավոր արմատախողովակի տարածվածությունը ստորին ծնոտի առաջին աղորիքների մեջ պարզվել է 5%, իսկ միջին հեռավոր արմատախողովակի տարածվածությունը ստորին ծնոտի առաջին աղորիքների մեջ՝ 10%: Միաձուլվող կոնֆիգուրացիան արմատախողովակի կոնֆիգուրացիայի ամենատարածված տեսակն էր ինչպես միջին արմատախողովակի, այնպես էլ միջին հեռավոր արմատախողովակի մեջ:

Եզրակացություն. Միջին մեդիալ արմատախողովակի և միջին հեռավոր արմատախողովակի տեղորոշումը հրամայական է ստորին ծնոտի առաջին աղորիքների լավ էնդոդոնտիկ կանխատեսման հասնելու համար: ՇՄՏ անալիզը մնում է որպես ոչ ինվազիվ և կլինիկական արդյունավետ գործիք արմատախողովակի մորֆոլոգիան որոշելու համար: Արմատախողովակի անատոմիայի տատանումների հաճախականության իմացությունը շատ կարևոր է բժիշկներին զգուշացնելու համար դրանք կլինիկական պրակտիկայում հանդիպելու հնարավորության մասին:

**РАСПРОСТРАНЕННОСТЬ И МОРФОЛОГИЯ СРЕДНЕГО МЕЗИАЛЬНОГО КАНАЛА И
СРЕДНЕГО ДИСТАЛЬНОГО КАНАЛА ПЕРВЫХ МОЛЯРОВ НИЖНЕЙ ЧЕЛЮСТИ В
СУБПОПУЛЯЦИИ СЕВЕРНОЙ ИНДИИ: РЕТРОСПЕКТИВНЫЙ СВСТ АНАЛИЗ**

Харприт Сингх,¹ Урваши Саггар,² Ришу Гаутам,³ Раджив К. Чух⁴

- ¹ Декан Исследований, профессор, заведующий кафедрой консервативной стоматологии и эндодонтии, стоматологический колледж и больница Баба Джасвант Сингх, Лудхиана

- ² Аспирант, кафедра консервативная стоматология и эндодонтия, стоматологический колледж имени Бабы Джасванта Сингха, больница и научно-исследовательский институт, Лудхиана.
- ³ Читатель, кафедра консервативная стоматология и эндодонтия, стоматологический колледж имени Бабы Джасванта Сингха, больница и научно-исследовательский институт, Лудхиана.
- ⁴ Приглашенный профессор, Институт стоматологических наук Сибар, Гунтур, частная практика, Нью-Дели

Абстракт

Цель: Целью исследования было оценить распространенность и морфологию среднего мезиального канала и среднего дистального канала в первых молярах нижней челюсти в субпопуляции Северной Индии с помощью конусно-лучевой компьютерной томографии.

Методология: 60 сканированы конусно-лучевой компьютерной томографии (КЛКТ) были ретроспективно проанализированы, из которых 40 первых моляров нижней челюсти были включены в это исследование в соответствии с критериями включения и исключения. На собранных КЛКТ-сканах оценивали наличие среднего мезиального и среднего дистального каналов первых моляров нижней челюсти. Конфигурацию корневых каналов средних мезиальных и средних дистальных каналов первых моляров нижней челюсти затем наблюдали на аксиальных и корональных срезах КЛКТ-сканирований.

Результаты: Из 40 исследованных первых моляров нижней челюсти распространенность среднего мезиального канала в первом моляре нижней челюсти составила 5%, а распространенность среднего дистального канала в первом моляре нижней челюсти - 10%. Сливная конфигурация была наиболее распространенным типом конфигурации корневых каналов как среднего мезиального, так и среднего дистального канала.

Заключение: Определение среднего мезиального и среднего дистального каналов является обязательным условием для достижения хорошего эндодонтического прогноза для первых моляров нижней челюсти. КЛКТ-анализ остается неинвазивным и клинически эффективным инструментом для определения морфологии корневых каналов. Знание частоты изменений в анатомии корневых каналов имеет решающее значение для предупреждения врачей о возможности столкнуться с ними в клинической практике.

DOI: 10.58240/1829006X-2023.19.4-19



ORIGINAL ARTICLE

THE CLINICAL AND MORPHOLOGICAL LESIONS OF THE ORAL MUCOSA AND
PERIODONTIUM WITH VIRAL HEPATITIS C

Vahe Azatyan,^{1*} Lazar Yessayan,² Yuri Azbekyan³

- ¹ Associate professor Department of Therapeutic Stomatology, Yerevan State Medical University, Yerevan after M. Heratsi, Yerevan, Armenia
² Professor, Head of Department of Therapeutic Stomatology, Yerevan State Medical University after M. Heratsi, Yerevan, Armenia
³ Student, Faculty of Stomatology, Yerevan State Medical University after M. Heratsi, Yerevan, Armenia

* Corresponding author: Vahe Azatyan, PhD, DMS, Assistant Professor, Department of Therapeutic Stomatology, Yerevan State Medical University, Yerevan, Armenia;
e-mail: vahe.azatyan@gmail.com

Received: Oct. 2, 2023; **Accepted:** Oct. 27, 2023; **Published:** Nov. 5, 2023

Abstract

Background: Interest in the study of combined pathology has recently been explained by the accumulation of new facts, the emergence of new information about interorgan, intertissue and intercellular levels of interaction in the system of the whole organism. Studies of the oral cavity in chronic diffuse liver diseases are of great interest to clinicians, since pathological processes developing in the liver, as a rule, lead to organic and functional disorders in the oral mucosa.

The aim of this study was to study the clinical and morphological lesions of the oral mucosa and periodontium in viral hepatitis C.

Material and methods: 196 patients were examined, of which: the control group consisted of 100 patients with lesions of the oral mucosa (OM) and periodontal disease who were not diagnosed with HCV and 96 patients of the main study group. Dental status was studied. A pathological examination was carried out.

Results: HCV patients group included 96 (63.5% males) and non-HCV group - 100 subjects (62.0% males) with lesions of oral mucous membrane. The lesions of lips and oral mucosa were more frequent in HCV than in the non-HCV group – e.g. erosion (13.5% vs 1%), cracks in the mouth corners (42.7% vs 0%), changes of oral mucosa surface (89.6% vs 3.0%), hemorrhages - (78.1% vs 0%) etc.

Conclusion: Thus, during the clinical examination of patients with HCV, the average severity of periodontal damage prevailed. Numerous morphological features can be divided into those that are indicators of the severity and activity of inflammation.

Keywords: viral Hepatitis C, oral cavity, periodontium, pathological examination.

Introduction

Interest in the study of combined pathology has recently been explained by the accumulation of new facts, the emergence of new information about interorgan, intertissue and intercellular levels of interaction in the system of the whole organism. In this regard, the question of the connection between diseases of internal organs and oral cavity organs is relevant.^{1,2,3}

The last decades of the 20th century and the beginning of the 21st century were marked by a sharp increase in the number of viral liver diseases, especially parenteral viral hepatitis, characterized by a highly chronic course, the development of many complications and mortality, which determined the medical and social importance of the problem of viral hepatitis.^{4,5}

The WHO report “Global hepatitis report” (2017) noted that about 325 million people in the world suffer from viral liver diseases, and mortality from them, unlike HIV infection, tuberculosis and malaria, continues to rise [6]. According to WHO data in 1990-2015. Every year in the world, 1.3-1.5 million people died from infections associated with hepatitis B and C viruses, 96% of them from chronic viral hepatitis, including cirrhosis of the liver and hepatocellular carcinoma that developed against them.⁷

Worldwide, 71 million people suffer from chronic hepatitis C. It is most common in the WHO Eastern Mediterranean Region and the WHO European Region, where the prevalence of viral hepatitis C was estimated to be 2.3% and 1.5%, respectively, in 2015. In other WHO regions, prevalence rates of HCV infection range from 0.5% to 1%. In some countries, high rates of hepatitis C may occur among certain population groups. Thus, 23% of new cases of HCV infection and 33% of deaths from HCV are associated with injection drug use. However, national programs to combat HCV do not always cover injecting drug users and prisoners in prisons.⁷

A significant place in foreign literature is given to the study of the manifestation of chronic diffuse liver diseases in the oral cavity.⁸ Studies of the oral cavity in chronic diffuse liver diseases are of great interest to clinicians since pathological processes developing in the liver, as a rule,^{9,10,11} lead to organic and functional disorders in the oral mucosa.^{12,13}

In chronic diffuse liver diseases, changes are also observed in the periodontium.^{1,14,15,16}

An important discovery in hepatology was the establishment of the possibility of extrahepatic replication of hepatitis B and C viruses in the cells of the skin and mucous membranes;^{17,18} vascular intima; tissues of bone marrow, blood, lymph nodes and spleen. Particular attention is drawn to the evidence of active replication of the virus in circulating macrophages - monocytes. The possibility of extrahepatic replication of HBV and HCV hepatitis does not exclude the possibility of damage to the skin and mucous membranes, including the oral mucosa and periodontal tissue, as evidenced by the detection of HCV RNA in the minor salivary glands and saliva itself.¹⁹

In the available literature, insufficient attention is paid to such important problems as the influence of foci of chronic infection in the oral cavity on the general condition of patients with HCV. Despite the progress achieved in the treatment of periodontal tissue diseases and oral cavity in patients with HCV, many issues, including changes in the quality of life in these diseases, remain insufficiently studied.^{20,21,22} Considering the severity of diseases in which various organs and systems of the patient are involved in the pathological process, it is necessary to develop an integrated approach to the early diagnosis and treatment of diseases of the oral cavity in patients with HCV, defining the place and role of the dentist. Patients with HCV should be under regular joint supervision of doctors of various specialties, in particular, infectious disease specialists, dentists, etc.²³

Based on the above, the aim of this study was to study the clinical and morphological lesions of the oral mucosa and periodontium in viral hepatitis C.

Material and Methods

The main base for conducting this dissertation research was the CJSC Infectious Clinical Hospital “Nork”, the CJSC Clinical Center “Armenicum” and the Dental Clinic No. 1 of YSMU named after. M. Heratsi of Yerevan from 2011 to 2019 196 patients were examined, of which: the control group consisted

of 100 patients with lesions of the oral mucosa (OM) and periodontal disease who were not diagnosed with viral hepatitis C (HCV) and 96 patients of the main study group.

Patients underwent traditional methods of clinical and laboratory examination, including a general blood and urine test, biochemical blood tests: determination of total bilirubin and fractions, alanine aminotransferase (ALT), aspartate aminotransferase (AST), alkaline phosphatase (ALP), γ -glutamyltransferase (GGT), total protein and fractions, coagulograms.

The final diagnosis of HCV was established based on the detection of hepatitis C virus RNA in the blood using PCR.

100 patients in the control group were examined: 38 (38%) women and 62 (62%) men. The average age of patients in the control group was 37.99 ± 16.66 (SD \pm SD) and 96 patients with HCV: 35 (36.5%) women and 61 (63.5%) men. The average age of the patients was 50.05 ± 13.29 (SD \pm SD).

All patients' dental status was studied according to pre-developed criteria, which included an external examination of the lips and corners of the mouth, assessment of the condition of various parts of the oral cavity, the marginal and alveolar part of the gums. An index assessment of the condition of periodontal tissues was also carried out (PI, SBI, OHI-S indices). The OHI-S was used to determine the hygienic state of the oral cavity.

A pathological examination was also carried out. For the histological study of the oral cavity, the cheek area was selected as an example of tissue covered with stratified squamous epithelium and having a pronounced connective tissue subepithelial layer. Tissue pieces were fixed in 10% neutral formalin, dehydrated and embedded in paraffin, according to the standard histological scheme. A series of 5- μ m-thick sections were made from the blocks and stained with hematoxylin-eosin and picrofuchsin according to Van Gieson for a general assessment of the condition of the tissues under study. It is well known that the diagnosis and prognosis of the outcome of diseases is primarily based on the study of hematoxylin-eosin sections. Microspecimens were studied with a Primostar Zeiss trinocular microscope under 200, 400 and 1000x (immersion) magnification. Microphotographs were taken using Axio Cam ERc5s (Carl Zeiss - Germany).

All signs were studied in accordance with international standards, WHO recommendations and recognized research methods. The criteria for the main pathomorphological changes in HCV that we have studied are the following: inflammatory infiltration, circulatory disorders, ulceration of the mucous membrane with fibrinous deposits, fibrosis of the mucous membrane, dystrophic changes in the squamous epithelium, bone sequestration. Additional criteria included infiltration (lymphoplasmacytic and plasmacytic) and admixture of neutrophils.

Statistical analysis

Descriptive analysis (Mean \pm SD for continuous and frequencies/proportion for categorical variables) were computed for all variables of interest. Differences between two groups were evaluated using "chi-square" or "Fisher's exact" tests for categorical variables and "Wilcoxon signed rank test" for continuous variables. Spearman correlation was performed for determination of relationships between continuous variables. P-value was considered significant at <0.05 and <0.001 for highly significant results. Analyses were conducted using Excel 2013 and R software.

Results

To study the dental status, patients' complaints and data from a clinical examination of the oral cavity were taken into account, which included: external examination of the lips and corners of the mouth, assessment of the condition of various parts of the OM.

Patients complained of discomfort in the oral cavity, dry mouth, tightness of the lips, soreness in the corners of the mouth, burning and tingling sensations in the tongue, changes in taste, coated tongue, and roughness of the oral cavity.

In patients with HCV, upon objective examination of the lips, the frequency of erosions was 13.5% (13), the presence of cracks in the corners of the mouth was observed in 42.7% (41). The frequency of occurrence of these two indicators in the control group was 1%. Disturbances in the relief of the oral cavity in the examined population with HCV were detected in

89.6% (86), in the control group - in 3% (3). When analyzing the above-described indicators, the difference in data was statistically significant compared to the control group ($p < 0.001$).

HCV had some manifestations that were absent in the control group. Namely, hemorrhages on the buccal mucosa and hard palate were observed in 78.1% (75) of those examined, which was significantly different from the control group, where this sign of damage was not detected ($p < 0.001$). A similar picture was observed with telangiectasia on the buccal mucosa, which was also absent in the control group, and in the HCV, group was detected in 67.7% (65) of patients

($p < 0.001$). Obviously, these signs are pathognomonic for HCV.

In an objective study of the vestibule and the oral cavity itself in patients with HCV, a bluish mucous membrane was detected in 30.2% (29), which significantly and significantly exceeded the same indicator in the control group ($p < 0.001$), bright red - in 46, 9% (45) of those examined, where a statistically significant difference with the control group was also observed ($p < 0.001$). Pink color of the mucous membrane was noted in 12.5% (12) and pale pink in 10.4% (10), which did not differ significantly from the control group ($p > 0.168$) (Figure 1 a, b).

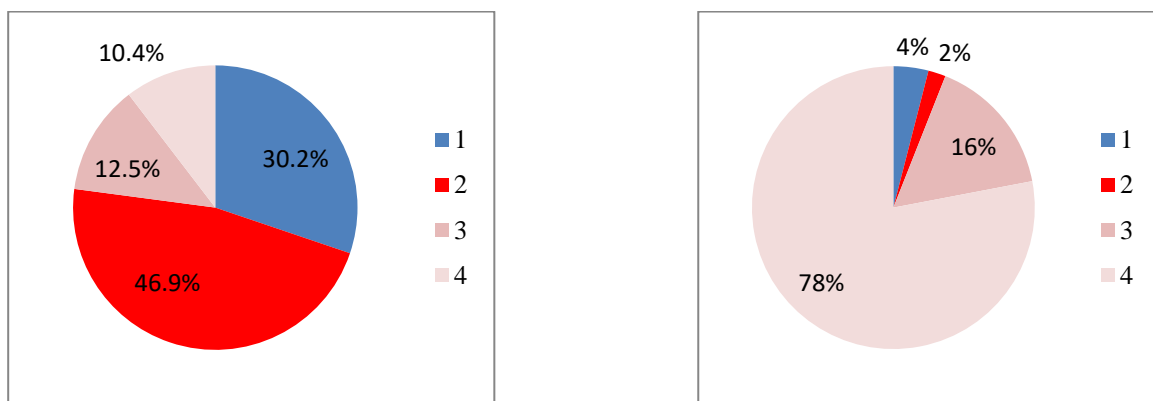


Figure 1 a, b. Color of OM in HCV (a) and in the control group (b) (1 - bluish, 2 - bright red, 3 - pink, 4 - pale pink)

The detection rate of inflammatory periodontal diseases (IPD) in the HCV patients we examined was 100%, which was manifested by the presence of a generalized inflammatory process in the area of the marginal and alveolar parts of the gums during an objective examination of the oral cavity. An objective examination of the oral cavity of patients with HCV revealed the following pathological changes in the gums: hyperemia was observed in 19.8% (19), cyanosis in 68.8% (66), swelling in 47.9% (46) of cases. When analyzing these symptoms, a statistically significant difference was determined compared to the control group ($p < 0.001$). Looseness of the gingival papillae was practically not detected either in the control group (only 1% of those examined) or in the group with HCV in 1% (1) ($p > 1$).

Gum atrophy was observed in 51% (49) of the population with HCV, which was statistically

significantly higher compared to the control group ($p < 0.001$), where this sign was absent. The noted changes were characterized by a decrease in the volume of tissue of the gingival papillae and gingival margin; limited atrophy was observed in the area of one or two teeth, which manifested itself visually as a V-shaped defect, roller-like thickened edges of the gums, exposure of the neck and root of the tooth, in particular in the frontal area with a predominant lesion incisors and canines.

Bleeding gums were detected in 49% (47) of the examined patients, and in the control group - in 11% (11) of patients. The difference in data was highly statistically significant ($p < 0.001$). Desquamation of the gum epithelium was observed in 2.1% (2) of those examined; this sign of damage was absent in the control group ($p > 0.239$). The described symptom

resembled the clinical picture of desquamative gingivitis with all the characteristic features.

To assess the degree of periodontal damage in patients with HCV, periodontal indices were

determined: PI according to Russel, SBI according to Mühlemann and Son, OHI-S according to J.C. Green - J.K. Vermillion (Table 1).

Table 1. Index assessment of the condition of periodontal tissues in patients with HCV and in the control group (SD ± SD)

Indicators	Control group	HCV group
PI, points	0.95 ± 0.48*	4.51 ± 0.64*
SBI, points	1.68 ± 1.66*	3.02 ± 0.1*
OHI-S, points	1.96 ± 0.59#	2.01 ± 0.51#

* p<0,001; #p>0,577

As can be seen from the table, in patients with HCV, the periodontal indices were statistically significantly different from the periodontal indices of patients in the control group. The PI index averaged 4.51 ± 0.64 points, which is 4.7 times higher than the value of the same index in patients in the control group.

The SBI index averaged 3.02 ± 0.1 points, which was also 1.8 times higher than the SBI index for patients in the control group. The difference in data is statistically significant with a high degree of confidence (p<0.001). The OHI-S index in patients with HCV averaged 2.01 ± 0.51 points, which is practically no different from that in the control group (p>0.577).

To determine the hygienic state of the oral cavity in the examined patients with HCV, a survey was conducted, which revealed that 9.4% (9) patients with HCV brushed their teeth 2 times a day - morning and evening, 12.5% (12) - 1 once a day, mainly in the morning after meals, 78.1% (75) of patients noted that they sometimes brush their teeth once a day before meals in the morning or every other day.

According to the OHI-S index in patients with HCV, the level of oral hygiene in 43.7% (42) was defined as bad, in 39.6% (38) - unsatisfactory, in 16.7% (16) - satisfactory. The OHI-S index value of 0 - 0.6, which characterizes good hygienic condition of the oral cavity, was not obtained in any patient with HCV (Table 2).

Table 2. Assessment of oral hygiene status according to OHI-S in patients with HCV and in the control group

Group	Hygiene level							
	Good (0.1 – 0.6)		Satisfied (0.7 – 1.6)		Unsatisfactory (1.7 – 2.5)		Bad (≥ 2.6)	
	abs.	%	abs.	%	abs.	%	abs.	%
Control group (n= 100)	25	25	48	48	15	15	12	12
Patients with HCV (n= 96)	-	-	16	16.7	38	39.6	42	43.7

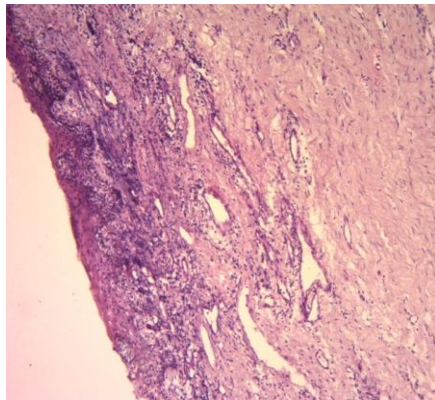
As can be seen from table. 2 in patients with HCV, a good level of oral hygiene was not detected with a high degree of reliability in any case (p<0.001),

satisfactory and unsatisfactory - almost 3 times less often, and bad - almost 4 times more often (p<0.001) compared to the control.

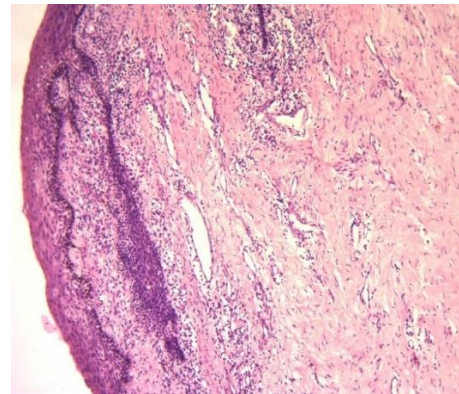
We identified 6 groups of main pathomorphological changes in the oral cavity in patients with HCV: 1. Inflammatory infiltration; 2. Circulatory disorders; 3. Ulcerations of the mucous membrane with fibrinous deposits; 4. Fibrosis of the mucous membrane; 5. Dystrophic changes in squamous epithelium; 6. Bone sequestration.

In addition to the main pathomorphological changes, we identified such criteria as lymphoplasmacytic infiltration and an admixture of neutrophils. In the oral cavity, the main localization of the pathological process was the mucous membrane of the cheek - in 55%, gums - in 45% of patients. Inflammatory infiltration was determined in the form of lymphoplasmacytic in 90% (18) of patients with

HCV, an admixture of neutrophils was noted in 20% (4) of patients with HCV, and ulceration of the mucous membrane was also noted. Circulatory disorders were manifested by edema, hemorrhage, stasis in the capillaries, plethora, and angiomas. Obliteration of the lumen of blood vessels, fibrinoid necrosis and fibrinoid swelling of the vessel walls were observed. Changes in the squamous epithelium were in the form of acanthosis, parakeratosis and thickening. The inflammatory infiltrate was represented mainly by lymphocytes, plasma cells and segmented leukocytes. This is a manifestation of both severe chronic inflammation and the participation of immune mechanisms in the development of the pathological process (Figure 2 a, b).



a



b

Figure 2. Angiomas and lymphoplasmacytic infiltration in the lamina propria of the mucous membrane. Lymphoplasmacytic infiltrate is located predominantly under the squamous epithelium (hematoxylin and eosin staining x 100)

As the inflammatory process in the oral cavity weakened, bleeding decreased and erosions became epithelialized. Changes due to the development of sclerosis (overgrowth of connective tissue) OM were

determined in 95% (19) of HCV. Healing of the oral mucosa occurred against the background of a higher density of newly formed vessels and the appearance of collagen fibers (Figure 3).

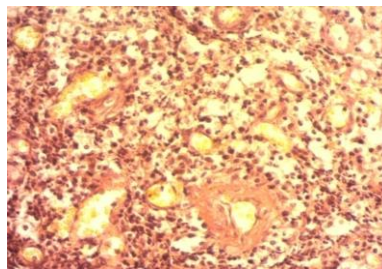


Figure 3. Severe angiomas in the phase of granulation tissue formation (Staining with picrofuchsin according to Van Gieson x400)

Discussion

There is practically no pathology that does not affect the condition of the OM. At the same time, the similarity of clinical manifestations in the oral cavity of diseases that differ in etiology and pathogenesis contributes to difficulties in making a final diagnosis.²⁴ Most researchers consider the periodontium as an integral component of the whole organism and recognize the close pathogenetic connection between periodontal diseases and somatic pathology. Patients with periodontitis with concomitant and background diseases require special attention, both in the diagnosis of concomitant pathology, and in treatment and prevention.²⁵ At the same time, dentists and doctors of other specialties do not pay due attention to the condition of the oral cavity in liver diseases.²⁶ The experience of dentists in infectious diseases departments has shown that the effectiveness of diagnosis and treatment of lesions of the oral cavity depends on the earliest possible examination of the admitted patient.²⁷ Dental care for patients, even with an established diagnosis of viral hepatitis, is provided mainly on the basis of referral due to acute pain. There are very few developments on dental tactics for managing patients with hepatitis. In countries with a high level of dental service, experience on this problem has also not been accumulated.^{13,28}

The data regarding the condition of the marginal and alveolar parts of the gums in patients with HCV are interesting. As can be seen, of the seven symptoms that we studied, which characterize the condition of the periodontium, five symptoms were reliably most often identified in HIV infection (with the exception of desquamation of the epithelium, which was found in the minimum number of patients in the three main groups of patients).³⁰ It should be noted that loose papillae were found almost only in patients with HIV infection. The difference in data regarding the frequency of detection of atrophy in the three studied groups is unreliable. Thus, only cyanosis was significantly more often detected with HCV. It is appropriate to note that according to Fedeli U. et al. (2017), who studied the characteristics of damage to the oral cavity and periodontal tissue in patients with chronic liver diseases of viral etiology, with chronic

hepatitis and liver cirrhosis caused by the hepatitis B virus, more severe degenerative and inflammatory changes are observed in the oral cavity and periodontal tissues compared to those caused by the hepatitis C virus.²⁹ Our data indicate that it is probably difficult to make an unambiguous conclusion regarding the comparison of the severity of damage to the oral cavity and periodontium in HCV, because some symptoms are significantly more often detected with HCV.

There are isolated works that describe a few individual signs in a small number of patients. A comparative analysis of data on the above characteristics in patients with viral hepatitis C has not been carried out. In our opinion, this is important, since the protocols for patient management and treatment regimens are different. I would like to note that the literature provides reviews on this problem, which describe in detail epidemiological data and pathophysiological mechanisms of extrahepatic lesions in viral hepatitis.^{17,31-33} However, there is little original research in this area. We will try to discuss and compare those isolated works that were found in the available literature.

Bagewadi S.B. et al. (2015) describe 3 clinical cases with a review of the literature, where, along with periodontal damage in the form of bleeding, swelling and friability of the gingival papillae, lichen planus was determined in 2 cases of hepatitis C.³⁴

Hepatitis C virus is a sialotropic virus. HCV-infected patients may often have signs of Sjögren's syndrome such as sialadenitis with mild or even absent clinical symptoms. The role of HCV in the pathogenesis of Sjögren's syndrome is not fully understood. However, in 57% of cases of chronic liver diseases associated with HCV, histological changes in the salivary glands' characteristic of Sjögren's syndrome were detected.³⁵ We did not set such a task for ourselves.

Conclusion

Thus, during the clinical examination of patients with HCV, the average severity of periodontal damage predominated, a mild degree was not detected, and

there were not enough patients with a severe degree for reliable conclusions. Numerous morphological signs can be divided into those that are indicators of the severity and activity of inflammation, and those that are associated with a long-term chronic course of inflammation in the oral cavity.

Declarations

Conflict of interest and financial disclosure

The author declares that he has no conflict of interest and there was no external source of funding for the present study. None of the authors have any relevant financial relationship(s) with a commercial interest.

Ethical approval

Research protocol was approved by the local Ethical Committee (2018/23) and in accordance with those of the World Medical Association and the Helsinki Declaration.

Informed consent

Informed consent was obtained from all individual participants included in the study.

Source of Funding

Non funding.

Availability of Data and Materials

Not applicable.

REFERENCES

1. Han P, Sun D, Yang J. Interaction between periodontitis and liver diseases. *Biomedical Reports*. 2016;5(3):267–276. doi:10.3892/br.2016.718
2. Kitamoto S, Kamada N. Periodontal connection with intestinal inflammation: microbiological and immunological mechanisms. *Periodontol* 2000. 2022;89(1):142-153. doi:10.1111/prd.12424
3. Kitamoto S, Nagao-Kitamoto H, Hein R, Schmidt TM, Kamada N. The bacterial connection between the oral cavity and the gut diseases. *J. Dent Res*. 2020;99(9):1021-1029. doi:10.1177/0022034520924633
4. Liu L, Zhang M, Hang L, et al. Evaluation of a new point-of-care oral anti-test for screening of hepatitis C virus infection. *Virol. J*. 2020;17(1):14. doi:10.1186/s12985-020-1293-7
5. Villar LM, de Paula VS, do Lago BV, et al. Epidemiology of hepatitis B and C virus infection in Central West Argentina. *Arch. Virol*. 2020;165(4):913-922. doi:10.1007/s00705-020-04540-7
6. Global Hepatitis Report 2017. World Health Organization (WHO), 2017. Available: <http://www.who.int/hepatitis/publications/global-hepatitisreport2017/en/>
7. World Health Organization (WHO). World Hepatitis Alliance. Hepatitis C. 2021. Available online: <https://www.who.int/news-room/fact-sheets/detail/hepatitis-c>. Accessed 20 May, 2022.
8. Franzè MS, Pollicino T, Raimondo G, Squadrito G. Occult hepatitis B virus infection in hepatitis C virus negative chronic liver diseases. *Liver Int*. 2022;42(5):963-972. doi:10.1111/liv.15233
9. Chilaka VN, Konje JC. Viral hepatitis in pregnancy. *Eur J Obstet Gynecol Reprod Biol*. 2021;256:287-296. doi:10.1016/j.ejogrb.2020.11.052
10. Cozzani E, Herzum A, Burlando M, Parodi A. Cutaneous manifestations of HAV, HBV, HCV. *Ital J Dermatol Venerol*. 2021;156:5-12. doi:10.23736/S2784-8671.19.06488-5
11. Elbatae H, Abdel-Razik A, Mousa E, Elshenaway M. Periodontal disease as predictor of chronic

- liver diseases. *Medical Journal of Viral Hepatitis*. 2020;4:57-61. doi:10.21608/mjvh.2020.80651
12. Barsetto D, Fussey J, Fabris L, et al. Infection and the risk of head and neck cancer: a meta-analysis. *Oral Oncol*. 2020;109:104869. doi:10.1016/j.oraloncology.2020.104869
13. Nayyar SS, Thiagarajan S, Malik A, et al. Head and neck squamous cell carcinoma in HIV, HBV and seropositive patients - prognosis and its predictors. *J. Cancer Res. Ther.* 2020;16(3):619-623. doi:10.4103/jcrt.JCRT_166_19.
14. Jervøe-Storm PM, Eberhard J, Needleman I, Worthington HV, Jepsen S. Full-mouth treatment modalities (within 24 hours) for periodontitis in adults. *Cochrane Database Syst Rev*. 2022;6(6):CD004622. doi:10.1002/14651858.CD004622.pub4
15. Kuraji R, Sekino S, Kapila Y, Numabe Y. Periodontal disease-related nonalcoholic fatty liver disease and nonalcoholic steatohepatitis: an emerging concept of oral-liver axis. *Periodontol 2000*. 2021;87(1):204-240. doi:10.1111/prd.12387
16. Xu W, Zhang Z, Yao L, et al. Exploration of shared gene signatures and molecular mechanisms between periodontitis and nonalcoholic fatty liver disease. *Front. Genet.* 2022;13:939751. doi:10.3389/fgene.2022.939751
17. Austria AM, Ninčević V, Wu GY, Smolic M, Vcev A, Wu GY. A brief update on the treatment of hepatitis C. Update on hepatitis C. *Intech Open*. 2017;3-16. doi:10.5772/intechopen.70685
18. Flores-Chávez A, Carrion JA, Fornis X, Ramos-Casals M. Extrahepatic manifestations associated with chronic hepatitis C virus infection. *Rev Esp Sanid Penit*. 2017;19:87-97. doi:10.4321/S1575-06202017000300004
19. Nagao Y, Kimura T, Nagao H. Analysis of hepatitis B and C virus infections amongst members of the dental national health insurance society in the Oita prefecture. *Biomedical Reports*. 2020. doi:10.3892/br.2020.1399.
20. Maruyama Y, Nishimoto Y, Umezawa K, et al. Comparison of oral metabolome profiles of stimulated saliva, unstimulated saliva, and mouth-rinsed water. *Sci Rep*. 2022;12(1):689. doi:10.1038/s41598-021-04612-x
21. Negro F, Forton D, Craxì A, Sulkowski MS, Feld JJ, Manns MP. Extrahepatic morbidity and mortality of chronic hepatitis C. *Gastroenterology*. 2015;149(6):1345-1360. doi:10.1053/j.gastro.2015.08.035
22. Nosratzahi T, Raiesi M, Shahryari B. Lack of Association between oral lichen planus and hepatitis B and C virus infection - a report from Southeast Iran. *Asian Pac J Cancer Prev*. 2018;19(6):1633-1637. doi:10.22034/APJCP.2018.19.6.1633
23. World Health Organization (WHO). Global oral health status report Towards universal health coverage for oral health by 2030. 2022. Available online: [https://www.who.int/news-room/fact-sheets/detail/oralhealth#:~:text=Periodontal%20\(gum\)%20disease&text=Severe%20periodontal%20diseases%20are%20estimated](https://www.who.int/news-room/fact-sheets/detail/oralhealth#:~:text=Periodontal%20(gum)%20disease&text=Severe%20periodontal%20diseases%20are%20estimated). Accessed 26 November, 2022
24. Takai S, Kuriyama T, Yanagisawa M. Incidence and bacteriology of bacteremia associated with various oral and maxillofacial surgical procedures. *Oral Surg Oral Med Oral Pathol Oral Radiol Endod*. 2015;99(3):292-298. doi:10.1016/j.tripleo.2004.10.022
25. Müller S. Oral lichenoid lesions: distinguishing the benign from the deadly. *Mod Pathol*. 2017;30(s1):S54-67. doi:10.1038/modpathol.2016.121
26. Ahmadi Gharaei H, Fararouei M, Mirzazadeh A, et al. The global and regional prevalence of hepatitis C and B co-infections among prisoners living with HIV: A systematic review and meta-analysis. *Infect Dis Poverty*. 2021;10(1):93. doi:10.1186/s40249-021-00876-7
27. Bagewadi SB, Arora MP, Mody BM, Krishnamoorthy B, Baduni A. Oral manifestations

- of hepatitis B and C: A case series with review of literature. *J Dent Specialities*. 2015;3(1):96-101.
28. Younossi Z, Park H, Henry L, Adeyemi A, Stepanova M. Extrahepatic manifestations of hepatitis C: A meta-analysis of prevalence, quality of life, and economic burden. *Gastroenterology*. 2016;150(7):1599-1608. doi:10.1053/j.gastro.2016.02.039
29. Fedeli U, Grande E, Grippo F, Frova L. Mortality associated with hepatitis C and hepatitis B virus infection: a nationwide study on multiple causes of death data. *World J Gastroenterol*. 2017;23(10):1866-1871. doi:10.3748/wjg.v23.i10.1866
30. Dubois VA, González MI, Martínez ME, et al. Enzyme production by *Candida albicans* and *Candida dubliniensis* in periodontal HIV-positive patients receiving and not receiving antiretroviral therapy. *Acta Odontol Latinoam*. 2020;33(2):104-111
31. El Howati A, Tappuni A. Systematic review of the changing pattern of the oral manifestations of HIV. *J Invest Clin Dent*. 2018;9(4):e12351. doi:10.1111/jicd.12351
32. Korbecki J, Szatkowska I, Kupnicka P, et al. The importance of CXCL1 in the physiological state and in noncancer diseases of the oral cavity and abdominal organs. *Int J Mol Sci*. 2022;23(13):7151. doi:10.3390/ijms23137151
33. Meer S. Human immunodeficiency virus and salivary gland pathology: an update. *Oral Surg Oral Med Oral Pathol Oral Radiol*. 2019;128(1):52-59. doi:10.1016/j.oooo.2019.01.001
34. Bagewadi SB, Arora MP, Mody BM, Krishnamoorthy B, Baduni A. Oral manifestations of hepatitis B and C: A case series with review of literature. *J Dent Specialities*. 2015;3(1):96-101.
35. Liao R, Yang HT, Heng Li H, et al. Recent advances of salivary gland biopsy in Sjögren's syndrome. *Front Med (Lausanne)*. 2022;8:792593. doi:10.3389/fmed.2021.792593

ԲԵՐԱՆԻ ԽՈՌՈՉԻ ԼՈՐՁԱԹԱՂԱՆԹԻ և ՊԱՐՕԴՈՆՏԻ ԿԼԻՆԻԿԱ-ՄՈՐՖՈԼՈԳԻԱԿԱՆ ԱԽՏԱՀԱՐՈՒՄՆԵՐԸ ՎԻՐՈՒՍԱՅԻՆ ՀԵՊԱՏԻՏ C-Ի ԴԵՊՐՈՒՄ

Վահե Ազատյան,¹ Լազար Եսայան,² Յուրի Ազրեկյան³

- ¹ Դոցենտ, Մ. Հերացու անվ. Երևանի Պետական Բժշկական Համալսարանի թերապևտիկ ստոմատոլոգիայի ամբիոն, Երևան, Հայաստան
- ² Պրոֆեսոր, Երևանի Մ. Հերացու անվան պետական բժշկական համալսարանի թերապևտիկ ստոմատոլոգիայի ամբիոնի վարիչ, Երևան, Հայաստան:
- ³ Երևանի Մ. Հերացու անվան պետական բժշկական համալսարանի ստոմատոլոգիական ֆակուլտետի ուսանող, Երևան, Հայաստան

Ամփոփում

Ներածություն. Համակցված պաթոլոգիայի ուսումնասիրության նկատմամբ հետաքրքրությունը վերջերս բացատրվում է նոր փաստերի կուտակմամբ, ամբողջ օրգանիզմի համակարգում միջօրգանական, միջհյուսվածքային և միջբջջային փոխազդեցության մակարդակների մասին նոր տեղեկությունների ի հայտ գալով: Լյարդի քրոնիկ դիֆուզ հիվանդությունների դեպքում բերանի խոռոչի ուսումնասիրությունները մեծ հետաքրքրություն են ներկայացնում բժիշկների համար, քանի որ լյարդում զարգացող պաթոլոգիական պրոցեսները, որպես կանոն, հանգեցնում են բերանի լորձաթաղանթի օրգանակ և ֆունկցիոնալ խանգարումների:

Հետազոտության նպատակն է ուսումնասիրել բերանի խոռոչի լորձաթաղանթի և պարօդոնտի կլինիկա-մորֆոլոգիական փոփոխությունները վիրուսային հեպատիտ C-ի դեպքում:

Նյութը և մեթոդները. Հետազոտվել է 196 բուժառու, որից՝ հսկիչ խումբը կազմել է 100 բուժառու, որոնց մոտ առկա էր բերանի խոռոչի լորձաթաղանթի և պարօդոնտի ախտահարումներով առանց Վիրուսային հեպատիտ C-ի, ինչպես նաև հիմնական խմբի 96 բուժառու: Ուսումնասիրվել է ստոմատոլոգիական ստատուսը: Կատարվել է հյուսվածաբանական հետազոտություն:

Արդյունքները. HCV-ով բուժառուների խումբը ներառում էր 96 մարդ (63,5% տղամարդիկ), առանց HCV խմբում ներառված էր 100 մարդ (62,0% տղամարդիկ) բերանի լորձաթաղանթի և պարօդոնտի ախտահարումներով: Շրթունքների և բերանի լորձաթաղանթի վնասվածքները ավելի հաճախ են նկատվել HCV-ով բուժառուների մոտ, քան առանց HCV խմբում: Էրոզիաներ (13,5%՝ 1%-ի դիմաց), բերանի անկյուններում ճաքեր (42,7%՝ 0%-ի դիմաց), բերանի լորձաթաղանթի մակերեսի փոփոխություններ (89,6%՝ 3,0%-ի դիմաց), արյունազեղումներ՝ (78,1%՝ 0%-ի դիմաց), և այլն:

Եզրակացություն. Այսպիսով, HCV-ով բուժառուների կլինիկական հետազոտության ընթացքում գերակշռում էր պարօդոնտի ախտահարման միջին ծանրությունը: Բազմաթիվ մորֆոլոգիական առանձնահատկությունները կարելի է բաժանել այն նշանների, որոնք հանդիսանում են բորբոքման ծանրության և ակտիվության ցուցանիշներ:

КЛИНИКО-МОРФОЛОГИЧЕСКИЕ ПОРАЖЕНИЯ СЛИЗИСТОЙ ОБОЛОЧКИ ПОЛОСТИ РТА И ПАРОДОНТА ПРИ ВИРУСНОМ ГЕПАТИТЕ С

Vage Azatyan,¹ Lazaryan Esayan,² Yuryy Azbekyan³

¹ Доцент кафедры терапевтической стоматологии, Ереванский государственный медицинский университет, им. М. Гераци, Ереван, Армения

² Профессор, заведующий кафедрой терапевтической стоматологии, Ереванский государственный медицинский университет им. М. Гераци, Ереван, Армения.

³ Студент стоматологического факультета Ереванского государственного медицинского университета имени М. Гераци, Ереван, Армения

Резюме

Введение: Интерес к изучению сочетанной патологии в последнее время объясняется накоплением новых фактов, появлением новых сведений о межорганном, межтканном и межклеточном уровнях взаимодействия в системе целостного организма. Исследования полости рта при хронических диффузных заболеваниях печени представляют большой интерес для клиницистов, поскольку развивающиеся в печени патологические процессы, как правило, приводят к органическим и функциональным нарушениям в слизистой оболочке полости рта.

Целью: Исследования было изучение клинико-морфологических поражений слизистой оболочки полости рта и пародонта при вирусном гепатите С.

Материал и методы: Обследовано 196 пациентов, из них: контрольную группу составили 100 пациентов с поражением слизистой оболочки полости рта (СО) и заболеваниями пародонта, у которых не был диагностирован ВГС и 96 пациентов основной группы исследования. Изучен стоматологический статус. Было проведено гистологическое исследование.

Результаты: В группу больных ВГС вошли 96 человек (63,5% мужчин), в группу без ВГС - 100 человек (62,0% мужчин) с поражением слизистой оболочки полости рта. Поражения губ и слизистой оболочки полости рта чаще наблюдались у пациентов с ВГС, чем в группе без ВГС. эрозии (13,5% против 1%),

трещины в углах рта (42,7% против 0%), изменения поверхности слизистой оболочки полости рта (89,6% против 3,0%), кровоизлияния - (78,1% против 0%) и др.

Заключение: Таким образом, при клиническом обследовании больных ВГС преобладала средняя степень тяжести поражения пародонта. Многочисленные морфологические признаки можно разделить на признаки, которые являются показателями тяжести и активности воспаления.

DOI: 10.58240/1829006X-2023.19.4-31



ORIGINAL ARTICLE

COEXISTENCE OF SJOGREN'S SYNDROME AND FAMILIAL MEDITERRANEAN FEVER:
A RARE COMBINATION

Ginosyan Knarik,^{1*} Ghazinyan Irina,² Nazaretyan Eduard,³ Eghiazaryan Nikolay,⁴ Efremidu Maritsa,⁵
Sevoyan Lilit,⁴ Osipyanyan Magda⁵

- ¹ Associate professor, Head of Department of Rheumatology, Yerevan State Medical University after M. Heratsi, “Heratsi” University Hospital, Yervan, Armenia
- ² Lecturer of Department of Propaedeutics of Internal Diseases, Yerevan State Medical University after M. Heratsi, Yervan, Armenia
- ³ Professor of Department of Propaedeutics of Internal Diseases, Yerevan State Medical University after M. Heratsi, Yervan, Armenia
- ⁴ Lecturer of Department of Rheumatology, Yerevan State Medical University after M. Heratsi, “Heratsi” University Hospital, Yervan, Armenia
- ⁵ Assistant Department of Rheumatology, Yerevan State Medical University after M. Heratsi, “Heratsi” University Hospital, Yervan, Armenia

* Corresponding author: Knarik Ginosyan, Head of the Department of Rheumatology, Yerevan State Medical University after M. Heratsi, Armenia;
e-mail: kginosyan@gmail.com

Received: Oct. 2, 2023; **Accepted:** Oct. 27, 2023; **Published:** Nov. 5, 2023

Abstract

Sjogren's syndrome is a chronic autoimmune disorder characterized by dry eyes, dry mouth and musculoskeletal involvement. Familial Mediterranean fever (FMF) is an autosomal recessive disease characterized by recurrent episodes of fever, peritonitis, synovitis, pleuritis, and erysipelas-like skin lesions. An increased prevalence of systemic autoimmune diseases has been reported in FMF. There are a lot of cases about coexistence of FMF-ankylosing spondylitis, vasculitis, Behcet's disease and others. In this article we present a rare combination of FMF and Sjogren's syndrome.

Keywords: *familial Mediterranean fever; Sjogren's syndrome; autoinflammation; autoimmunity.*

Introduction

Sjogren's syndrome (SS) is a chronic autoimmune disorder of exocrine glands with associated lymphocytic infiltrates of the affected glands

characterized by dry eyes, dry mouth, and musculoskeletal involvement.¹

Familial Mediterranean fever (FMF) is an autoinflammatory disorder which is caused by

mutations in Mediterranean fever (MEFV) gene which is located on the short (p) arm of chromosome 16. It's an autosomal recessive disease characterized by recurrent episodes of fever, peritonitis, synovitis, pleuritis, and erysipelas-like skin lesions. It is common in Turkish, Armenian, Arabic, and Sephardic Jewish populations.²

Diseases that have been proposed to be associated with FMF include Behcet's disease, inflammatory bowel disease, vasculitis, ankylosing spondylitis.³⁻⁸

In this article we report an unusual case of coexistence of FMF and Sjogren's disease.

Case report

A 58-year-old female with 35 years history of periodic severe attacks of abdominal and chest pain, accompanying by high fever 39-40°C with duration of 2 days admitted to our outpatient clinic. These attacks were repeated 1-2 times per month. In her medical history molecular-genetic examination of MEFV gene revealed 2 mutations in compound-heterozygote form – M694V/V726A and she was diagnosed with FMF. She had been on colchicine treatment for 30 years. In 2022 year, she noticed dryness of eyes and mouth and enlargement of salivary glands. High ESR and C-reactive protein levels, elevated levels of circulating immune complexes, rheumatoid factor, antinuclear, anti-SSA/Ro and anti-SSB/La antibodies were revealed in laboratory analysis. Other examinations such as complete blood count and biochemistry test results were unremarkable. Schirmer's test was < 5 mm. The lip biopsy of minor salivary glands was carried out. Histopathological findings were typical for Sjogren's syndrome. Taking into account clinical findings (dry mouth, dry eyes, enlargement of salivary glands), laboratory data (specific for SS anti-SSA/Ro and anti-SSB/La antibodies, also positive rheumatoid factor and elevated markers of inflammation), results of Schirmer's test (confirm dry eyes symptom) and histopathological findings the diagnosis of Sjogren's syndrome was established. She was prescribed prednisone-15 mg/day with tapering dosage to 5 mg/day, hydroxychloroquine 400 mg/day, colchicine 1.5 mg/day and lubricant eye drops.

Discussion

Autoinflammatory diseases, the typical representative of which is FMF, and autoimmune diseases such as Sjogren's syndrome have common features but different mechanisms of development.

While autoimmunity involves adaptive immune activation, autoinflammation involves innate immune activation. Both diseases share some characteristics: they start with the prefix "auto" to define a pathological process directed against self, they are systemic diseases, frequently involving the musculoskeletal system, gastrointestinal tract, kidneys, skin, both include monogenic and polygenic diseases.⁹ An increased prevalence of systemic autoimmune diseases has been reported in FMF. There is some evidence about the coexistence of FMF-ankylosing spondylitis, vasculitis, Behcet's disease and others.³⁻⁸

To our knowledge, three cases of the coexistence of FMF and SS have been reported in the literature. Tanaka et al. reported a 42-year-old female Japanese patient with FMF who complained of dry mouth and dry eye¹⁰. She had a homozygous M649I mutation and experienced recurrent attacks of chest pain, fever, and knee arthritis. Specific antibodies for SS (anti-Ro and anti-La) weren't detected, but the antinuclear antibody was positive at high titers. Schirmer's test was positive. Findings of sialography were consistent with SS.

Similarly, Kobak et al. reported a 42-year-old male Turkish patient with a 20-year history of FMF, who presented with complaints of dry eyes and mouth.¹¹ In this case anti-Ro and anti-La antibodies were negative, but the antinuclear antibody was positive at 1:160. Minor salivary gland biopsy showed grade IV sialoadenitis according to Chisholm grading criteria. His genetic analysis revealed compound heterozygosity for M694V mutation.

Dortbas et al. reported an unusual case of coexistence of FMF, SS and ankylosing spondylitis.¹² A 34-year-old female patient with a 14-year history of FMF with M694V and R202Q mutations of the MEFV gene complained of severe pain in the lower back and hips. The patient presented with a two-year history of inflammatory low back pain and morning stiffness lasting more than one hour. The patient reported that she was diagnosed with SS five years ago when she

complained of dry mouth and eyes. At the time, the antinuclear antibody was positive at 1:320 granular pattern. Anti-Ro/SSA, anti-La/SSB and anti-Ro52 antibodies were also positive. Salivary scintigraphy showed reduced concentration, which was consistent with the findings of SS. Physical examination revealed limitations in the lumbar spine. Flexion and external rotation of the left hip were limited in the mid-range of motion. Modified Schober test was 3 cm. Lumbosacral X-ray of the spine showed bilateral sacroiliitis: grade III on the right side and II-on the left.

Haznedaroglu et al. reported increased IL-18 levels in patients with FMF.¹³ They suggested that IL-18 might contribute to the cytokine network in the inflammatory cascade of FMF. Also, Tanaka et al. detected higher IL-18 levels in their patient with concomitant SS and FMF, and reported that FMF-related dysregulated IL-18 production and chronic inflammation might be linked with the occurrence of SS.¹⁰

Conclusion

A remarkable overlap was highlighted between autoinflammatory (FMF) and systemic autoimmune diseases of connective tissue: both diseases have such common features as arthralgia, myalgia, arthritis, fever, skin involvement, serositis, hepato-splenomegaly and renal involvement. MEFV

mutations appear to modify systemic connective tissue diseases phenotype. Further observations are needed to explain the role of MEFV mutations in developing systemic autoimmune disease.

Declarations

Conflict of interest and financial disclosure

The author declares that he has no conflict of interest and there was no external source of funding for the present study. None of the authors have any relevant financial relationship(s) with a commercial interest.

Ethical approval

Research protocol was approved by the local Ethical Committee (2018/23) and in accordance with those of the World Medical Association and the Helsinki Declaration.

Informed consent

Informed consent was obtained from all individual participants included in the study.

Source of Funding

Non funding.

Availability of Data and Materials

Not applicable.

REFERENCES

1. Ramos-Casals M, Brito-Zerón P, Bombardieri S, et al. EULAR recommendations for the management of Sjögren's syndrome with topical and systemic therapies. *Annals of the Rheumatic Diseases*. 2020;79:3-18. doi:10.1136/annrheumdis-2019-216114
2. Sari İ, Birlik M, Kasifoğlu T. Familial Mediterranean fever: An updated review. *Eur J Rheumatol*. 2014;1:21-33. doi:10.5152/eurjrheum.2014.006
3. Aksu K, Keser G. Coexistence of vasculitides with Familial Mediterranean fever. *Rheumat. Int*. 2011;31(10):1263-1274. doi:10.1007/s00296-011-1840-z
4. Watad A, Tiosano S, Yahav D, et al. Behçet's disease and familial Mediterranean fever: Two sides of the same coin or just an association? A cross-sectional study. *Eur J Intern Med*. 2017;39:75-78. doi:10.1016/j.ejim.2016.10.011

5. Yazici A, Cefle A, Savli H. The frequency of MEFV gene mutations in Behcet's disease and their relation with clinical findings. *Rheumatol Int.* 2012;32:3025-3030. doi:10.1007/s00296-011-2011-y
6. Seyahi E, Ugurlu S, Amikishiev Sh, et al. Behcet disease, familial Mediterranean fever and MEFV variations: more than just an association. *Clinical Immunology.* 2023;251:109630. doi:10.1016/j.clim.2023.109630
7. Akkoc N, Gul A. Familial Mediterranean Fever and Seronegative Arthritis. *Curr Rheumatol Rep.* 2011;13:388–394. doi:10.1007/s11926-011-0191-9
8. Kasifoglu T, Calisir C, Cansu DU, Korkmaz C. The frequency of sacroiliitis in familial Mediterranean fever and the role of HLA-B27 and MEFV mutations in the development of sacroiliitis. *Clin Rheumatol.* 2009;28:41–46. doi:10.1007/s10067-008-0980-3
9. Doria Z, Zen M, Bettio S, et al. Autoinflammation and autoimmunity: bridging the divide. *Autoimmune Rev.* 2012;12(1):22-30. doi:10.1016/j.autrev.2012.07.018
10. Tanaka M, Migita K, Miyashita T, et al. Coexistence of familial Mediterranean fever and Sjögren's syndrome in a Japanese patient. *Clin Exp Rheumatol.* 2007;25:792–792.
11. Kobak S, Kobak AC, Aksu K, Keser G, Oksel F. Coexistence of Sjogren's syndrome and familial Mediterranean fever. *APLAR Journal of Rheumatology.* 2007;10:244–245. doi:10.5606/ArchRheumatol.2016.5671
12. Dörtbaşı F, Garip Y, Güler T, Karci AA. Coexistence of Familial Mediterranean Fever with Ankylosing Spondylitis and Sjogren's Syndrome: A Rare Occurrence. *Arch Rheumatol.* 2015;31(1):87-90. doi:10.5606/ArchRheumatol.2016.5671
13. Haznedaroglu S, Oztürk MA, Sancak B, et al. Serum interleukin 17 and interleukin 18 levels in familial Mediterranean fever. *Clin Exp Rheumatol.* 2005;23:S77–S80.

ՇԵՂԵՆԻ ՀԱՄԱԽՏԱՐԱՆԱԿԱՆ ԵՎ ՊԵՏԱԿԱՆ ԲԺՇԿԱԿԱՆ ՀԱՄԱԿԱՐԱՆԻ ՆԵՐՔԻՆ ԻՎԱՆԴՈՒԹՅԱՆ ՀԱՉԿԱԳԻՊ ՀԱՄԱԿՑՈՒՄ

Գինոյան Զնարիկ,¹ Իրինա Ղազինյան,² Էդուարդ Նազարեթյան,³ Եղիազարյան Նիկոլայ,⁴ Էֆրեմիդու Մարիցա,⁵ Սևոյան Լիլիթ,⁴ Օսիայան Մազդա⁵

- ¹ Երևանի Մ.Հերացու անվան Պետական Բժշկական Համալսարանի ռևմատոլոգիայի ամբիոնի վարիչ, դոցենտ, Հերացի համալսարանական հիվանդանոց, Երևան, Հայաստան
- ² Երևանի Մ.Հերացու անվան Պետական Բժշկական Համալսարանի Ներքին հիվանդությունների պրոպեդևտիկայի ամբիոնի դասախոս, Երևան, Հայաստան
- ³ Երևանի Մ.Հերացու անվան Պետական Բժշկական Համալսարանի Ներքին հիվանդությունների պրոպեդևտիկայի ամբիոնի պրոֆեսոր, Երևան, Հայաստան
- ⁴ Երևանի Մ.Հերացու անվան Պետական Բժշկական Համալսարանի ռևմատոլոգիայի ամբիոնի դասախոս, «Հերացի» համալսարանական հիվանդանոց, Երևան, Հայաստան
- ⁵ Երևանի Մ.Հերացու անվան Պետական Բժշկական Համալսարանի ռևմատոլոգիայի ամբիոնի ասիստենտ, Հերացու անվան համալսարանական հիվանդանոց, Երևան, Հայաստան

Ամփոփում

Շեղենի համախտանիշը քրոնիկական աուտոիմուն հիվանդություն է, որը բնութագրվում է աչքերի և բերանի լորձաթաղանթների չորությամբ, ինչպես նաև հենաշարժիչ համակարգի ախտահարմամբ: Միջերկրածովյան ընտանեկան տենդը կամ նույն ինքը՝ Պարբերական հիվանդությունը (ՊՀ) աուտոսոմ-

նեցեսիվ աուտոբրոքրոբային հիվանդություն է, որը բնութագրվում է պարբերաբար կրկնվող տենդով, որովայնամզի բորբոքումով, սինովիտով, պլևրիտով և մաշկի երիզիպետիդ տիպի ախտահարումներով: ՊՀ-ի ժամանակ դիտվում է համակարգային աուտոիմուն հիվանդությունների հանդիպման հանախականության բարձրացում: Նկարագրված են պարբերական հիվանդության և աուտոիմուն հիվանդությունների գուգակցման բազմաթիվ կլինիկական դեպքեր, որտեղ ՊՀ-ն համակցված է անկիլոզացնող սպոնդիլոարթրիտի, վասկուլիտների, Բեխտեի հիվանդության հետ: Սույն հոդվածում ներկայացված է ՊՀ-ի և Շեգրենի համախտանիշի հազվադեպ գուգակցման կլինիկական դեպք:

РЕДКАЯ КОМБИНАЦИЯ СИНДРОМА ШЕГРЕНА И ПЕРИОДИЧЕСКОЙ БОЛЕЗНИ

Гиносян Кнарик,¹ Ирина Газинян,² Эдуард Назаретян,³ Егиазарян Николай,⁴ Ефремиду Марица,⁵
Севоян Лилит,⁴ Осипян Магда⁵

- ¹ Доцент, заведующий кафедрой ревматологии, Ереванский государственный медицинский университет имени М. Гераци, Университетская больница «Гераци», Ереван, Армения
- ² Преподаватель кафедры пропедевтики внутренних болезней, Ереванский государственный медицинский университет им. М. Гераци, Ереван, Армения
- ³ Профессор кафедры пропедевтики внутренних болезней, Ереванский государственный медицинский университет им. М. Гераци, Ереван, Армения
- ⁴ Преподаватель кафедры ревматологии, Ереванский государственный медицинский университет имени М. Гераци, Университетская больница «Гераци», Ереван, Армения
- ⁵ Ассистент кафедры ревматологии, Ереванский государственный медицинский университет имени М. Гераци, Университетская больница «Гераци», Ереван, Армения

Резюме

Синдром Шегрена - хроническое аутоиммунное заболевание, характеризующееся сухостью глаз и полости рта, а также поражением опорно-двигательного аппарата. Периодическая болезнь (ПБ) - аутосомно-рецессивное аутовоспалительное заболевание, характеризующееся периодически повторяющимися приступами лихорадки и серозитов: перитонитом, плевритом, синовитом и эризипелоид-подобной сыпью. При ПБ наблюдается увеличение частоты развития системных аутоиммунных заболеваний. Описано достаточно много сочетаний ПБ с анкилозирующим спондилоартритом, васкулитом, болезнью Бехчета и рядом других аутоиммунных заболеваний. В данной статье нами описан клинический случай редкого сочетания ПБ и синдрома Шегрена.

DOI: 10.58240/1829006X-2023.19.4-36



ORIGINAL ARTICLE

ENHANCEMENT OF SOFT TISSUE SURROUNDING DENTAL IMPLANTS – AN OVERVIEW OF LITERATURE

Komal K. Ghadge, Sharath K. Shetty,* Anita Kulloli, Ketan Deshetti, Dharmarajan Gopalakrishnan

Department of Periodontology and Oral Implantology, Dr. D.Y. Patil Dental College and Hospital, Pimpri, Pune-411018, Maharashtra, India

* Corresponding author: Sharath K. Shetty, Department of Periodontology and Oral Implantology, Dr. D.Y. Patil Dental College and Hospital, Pimpri, Pune-411018, Maharashtra, India;
email: ghadge.komal26@gmail.com

Received: Oct. 2, 2023; **Accepted:** Oct. 27, 2023; **Published:** Nov. 5, 2023

Abstract

Dental implants have traditionally been focused on bone quality and quantity to house the dental implant for successful restoration of the edentulous ridge. Rough surface implants provide predictable osseointegration but results in the development of peri-implantitis when exposed to the oral environment. The peri-implant mucosa provides protection to the underlying bone via its immune response and protection from apical biofilm migration. An adequate band of keratinized mucosa also improves comfort with performing oral hygiene, limit early marginal bone loss and improved aesthetic outcomes around implant prostheses. The purpose of this article is to provide a literature review on the importance of attached keratinized mucosa around dental implants. It also shares simple strategies to improve the peri-implant mucosa before, during and after implant placement.

Keywords: Bone remodelling; Dental implants; Implantology; Implant mucosa augmentation; Peri-implant mucosa; Soft tissue complications.

Introduction

Dental implantology emerged as a field after Branemark first discovered osseointegration in 1962 and subsequently placed the first dental implant in a human.¹ Significant developments during the following period resulted in more predictable treatment outcomes with shorter treatment duration. The first machined surface implants required a healing period of 3-6 months. The introduction of roughened surfaces had reduced the healing period to 3-4 months, with more osteogenic surface treatments advocating 6-

8 weeks and physiologically active hydrophilic surfaces further reducing it to 3-4 weeks.²

This development reflects an excellent understanding of the osseointegration process. It is estimated that 12- 18 million implants are placed annually with great survival rates across the world. (Bjorn 2018). Since the introduction and widespread utilization of rough surface implants, the incidence of peri-implantitis has been on the rise. The initial documentation of this occurrence was in 1987, specifically associated with rough surface titanium plasma sprayed implants.³

Soft Tissue Around Dental Implants

Peri-implantitis is a plaque-associated pathological disease that occurs in the tissues surrounding dental implants, characterized by inflammation of the peri-implant mucosa and consequent gradual loss of supporting tissue.⁴ As a result, it is essential to highlight that the inflammatory process originates in soft tissue and that bone resorption occurs as a direct result of this inflammation. At the implant level, the prevalence of peri-implantitis ranges from 9.6% to 22%.⁵⁻⁷

Peri-implantitis must be differentiated from physiological bone remodeling.⁸ Although both lead to bone loss surrounding the implant, the causes are distinct. Early marginal bone loss is a physiological phenomenon that occurs within the first year following implant the placement.⁹ The aetiology is complicated, with surgical and prosthetic variables such as bone overheating, implant insertion torque and depth, the number of abutment disconnections, and the implant abutment microgap all contributing. Early marginal bone loss is thus an adaptive response of the peri-implant tissues to these stimuli. Marginal bone loss higher than 0.44mm in the first 6 months following prosthetic loading acts as a risk indication for peri-implant bone loss progression at 18 months.¹⁰ Progression of crestal bone loss is rare around dental implant in the absence of inflammation therefore early bone remodeling may initiate peri-implantitis.⁴

Berglundh and Lindhe showed the peri-implant mucosa re-establishes itself as a “Biological Width” (now termed supra-crestal tissue height around implants.¹¹ In the presence of thin mucosa, bone resorption occurred surrounding the implant, resulting in an angular defect that allowed for an increase in soft tissue thickness. It was thus concluded a minimum thickness of soft tissue was required around implants to allow for healing. This minimum thickness is 3-4mm in humans with an epithelial coronal component that varies between 2.0 – 2.2mm and an apical zone of connective tissue adhesion between 1.1-1.7mm wide.^{12,13} The soft tissue vertical dimension around implants on average is 1-1.5mm more than around teeth.¹⁴ The epithelial component share similarities between the implant and tooth however the connective tissue shows histological differences. The orientation of the collagen fibers with the connective tissue is

parallel with the abutment body compared to natural teeth whereby fibers attach into the cementum at perpendicular and oblique angles.¹⁵ Supra-crestal tissue height is independent of implant design and restorative modality.¹⁶

The increased prevalence of peri-implant bone loss and more rapid progression of periodontal disease around implants compared to teeth has resulted in a paradigm shift emphasising the importance of the peri-implant soft tissue in protecting the underlying bone and limiting early marginal bone loss.¹⁷ Albrektsson recently coined this a new era of mucointegration.¹⁸

The 'peri-implant phenotype' was recently proposed by Avila-Ortiz's group. This term refers to both the soft tissue component (peri-implant keratinised mucosa, mucosa thickness, and supracrestal tissue height) and the hard tissue compartment (peri-implant bone thickness).¹⁶

The significance of keratinised mucosa has been controversial around teeth and implants alike.¹⁹ The 2017 World Workshop on the Classification of Periodontal and Peri-Implant Diseases and Conditions found equivocal evidence on the presence or absence of keratinized mucosa on the health of the peri-implant tissues. The consensus statement however states “keratinized mucosa may have advantages regarding patient comfort and ease of plaque removal”.⁸ There is growing evidence to support the minimum amount of 2mm of keratinized mucosa width to minimize the development of peri-implant disease especially in patients with poor maintenance compliance.²⁰

The peri-implant mucosa can be measured in thickness and height. Together they give volume to the tissue. Thickness relates to the horizontal dimension of the peri-implant soft tissue and height refers to the supra-crestal tissue height akin to the supra-crestal tissue attachment on teeth. The vertical dimension is significant due to its effect on early bone remodeling as discussed previously.

Mucosa thickness may contribute to the health of the implant with better maintenance of marginal bone heights.²¹ Most of the research investigating mucosal thickness examine its effect on aesthetics of the implant by its ability to mask the colour of the underlying restorative abutment. Tissue of 1.5mm thickness or less resulted in visible tissue colour

changes however, 2mm thick tissue was able to mask zirconia substrates and 3mm tissue thickness was able to mask all restorative materials.²²

Increased peri-implant mucosa increases extracellular matrix and collagen volume while also increasing vascularity, which promotes immune response, toxin clearance, and growth factor migration.²³ This immune response has been suggested to be more important than the tissue attachment to the implant to prevent apical biofilm migration.¹² Thicker tissue also responds favorably to flap management, wound healing, restorative trauma and less post prosthetic recession.²⁴

Mucosal thickness varies in the mouth with the maxilla generally thicker than the mandible. The mandibular edentulous molar ridge exhibits the thinnest soft tissue thickness and this area often poses the greatest challenge for the clinician.²⁵

When examining a site for dental implant placement, the current paradigm shift dictates that we must evaluate not just the availability of bone to house the implant but also the quality of the soft tissue at the site including the width of keratinized mucosa and the thickness and height of the mucosa.

Soft Tissue Augmentation Around Dental Implants

Soft tissue augmentations can be performed prior to implant placement, during implant placement, during second stage implant surgery. There appears to be no difference between staged and simultaneous soft tissue augmentation after implant insertion, and operations can greatly improve keratinized tissue width and mucosal tissue thickness, with tissue stability attained 3 months after augmentation.²⁶

Traditional mucogingival surgeries such as frenectomies, free gingival grafts, apical repositioning flaps and alveolar ridge augmentations are applicable to the peri-implant soft tissues. Autologous soft tissue grafts still considered as the gold standard to gain keratinized tissue and mucosal thickness compared to autologous substitutes.²¹ Soft tissue complications around dental implants in most cases fall into the category of volume deficiency, lack of attached

mucosa and recession around implants.

This article shall provide a summary of common augmentation procedures available to the implant clinician at different stages of implant therapy to address the above three soft tissue complications. It will assume the use of autologous soft tissue grafts however autologous substitutes can be readily substituted in many of the illustrated procedures.²⁷ The efficacy of these substitutes is not within the scope of this article.

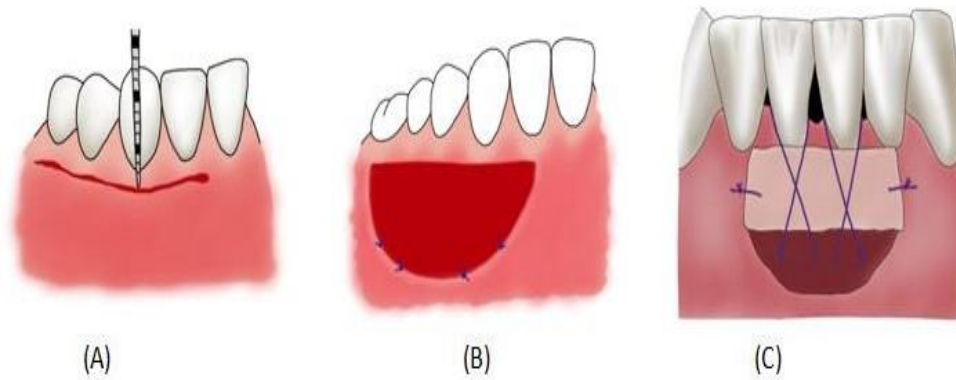
Soft Tissue Procedures before Implant Placement

As a part of a comprehensive implant treatment the soft tissue condition must be observed. This may be an edentulous ridge or dentate ridge with the compromised tooth still in situ. The assessment involves determination of any mucogingival defects such as frenulum, amount of attached mucosa and volume of soft tissue. Different methods of determining soft tissue phenotype have been suggested with visual inspection, radiographic assessment, using probes and calipers.^{28,29}

Having a clear understanding of the soft condition prior to implant placement allows for adoption of strategies to mitigate the risks associated with them.

Frenectomy may be performed prior to implant placement to improve the surgical outcomes. High frenum attachments can increase flap mobility and is a major cause of surgical wound opening. Apical positioned flaps (APF) (Figure 1A-B) can be performed to increase the band of attached keratinized tissue and increase the depth of the vestibule to facilitate oral hygiene and allow periosteal releasing incisions and flap advancement at later surgeries.

The APF approach offers various advantages, including the absence of a second surgical site, reduced postoperative bone loss, control of postoperative gingival margin status, and increased patient acceptability. When the soft tissue phenotype requires modification an APF with a free gingival graft can prepare the site for ideal implant placement at a later stage (Figure 1C).



(A) Submarginal incision for an APF (B) APF sutured to the periosteum (C) APF with free gingival graft with periosteal sling sutures

Figure 1

When an extraction and socket preservation is indicated for a delayed implant placement at a site with thin phenotype or loss of attached keratinized tissue then a socket sealing procedure is recommended to improve and modify the soft tissue at the extraction site. A punch biopsy can be used to harvest a free gingival graft from the palate or

maxillary tuberosity to be transferred to the extraction socket with or without bone graft substitute (Figure 2A-C). In cases where additional volume gain in soft tissue is desirable at the labial or lingual aspects then a saddle socket seal provides the softest tissue volume gain of all the socket preservation techniques (Figure 2D-E).^{30,31}

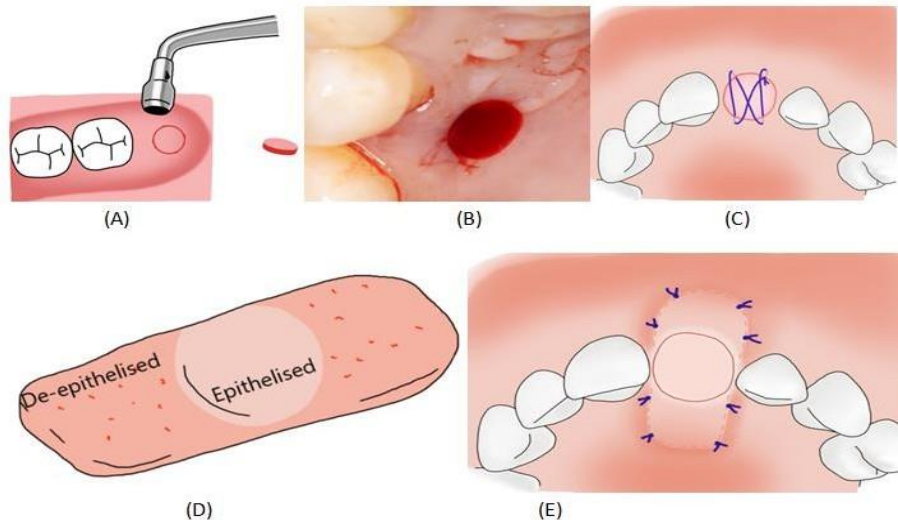


Figure 2: (A) Tissue biopsy punch is used to harvest a round free gingival graft from the palate or tuberosity; (B) Donor site after free gingival graft harvest; (C) Socket seal occlusion of extraction socket using free gingival graft secured with figure of 8 suture; (D) Rectangular free gingival graft partially de-epithelised to be used as a “Saddle” socket seal; (E) Saddle socket seal de-epithelised graft is tunneled under the buccal and palatal gingiva and secured with simple interrupted sutures.

In the anterior maxilla, extraction of a tooth in the presence of a thin buccal bone plate (<1mm) can result in the spontaneous thickening of the soft tissue by 7-fold after an 8-week healing period (Figure 3C).³²

With appropriate case selection which exhibit favorable sagittal root position and palatal and apical bone volume, this phenomenon affords the patient a “free” connective tissue graft when a Type II early

implant placement protocol is adopted. In these cases, no socket preservation is required at the time of tooth extraction and Type 2 placement with simultaneous buccal bone contour augmentation protocol has been shown to yield stable long term functional and cosmetic results.³³

Appropriate assessment of soft tissue prior to implant is essential to allow for correction of the deficiencies identified. Managing the soft tissue prior to implant placement prevents or reduces the risks of future complications which may be more difficult to manage once the implant has been placed into the site.

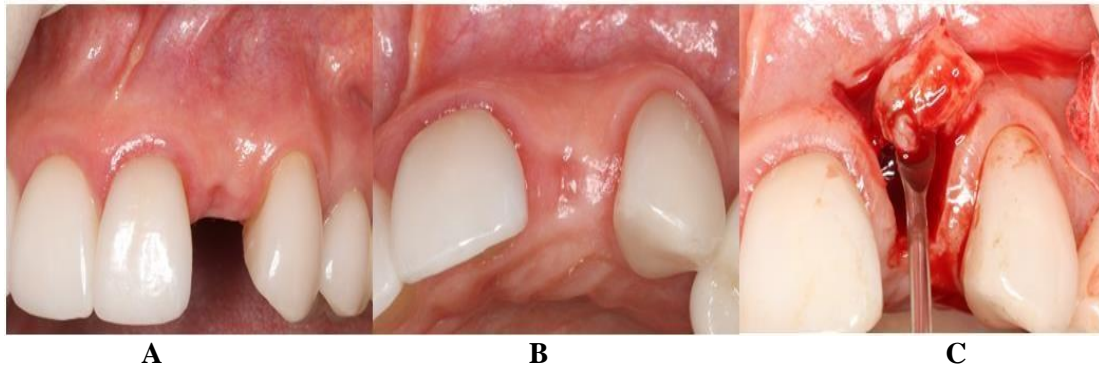


Figure 3: (A) & (B) 6 weeks after extraction of upper left lateral incisor without socket preservation the ridge appears to have maintained the original soft and hard tissue architecture; (C) Elevation of a papilla sparing flap reveals the ridge is maintained by a spontaneous thickening of soft tissue and there is complete loss of the buccal plate.

Soft Tissue Procedures During Implant Placement

Implant specific strategies are available to supplement vertical soft tissue deficiencies. These procedures include ridge flattening, subcrestal implantation, soft tissue tenting, and soft tissue mucogingival augmentation.³⁴ Less overall treatment times; fewer surgeries; simultaneous hard tissue and soft tissue healing; shorter healing time; less pain and discomfort; less stress; lower costs; and greater patient satisfaction are all advantages of soft tissue augmentation at the time of implant placement.³⁵ The risks result from the combination of many surgical operations at one location, which may damage vascularity and increase the possibility of post-operative problems. The surgery also becomes technically more challenging. Soft tissue augmentation can accompany implant surgery as one stage or stage procedure.

It has been proposed that free gingival grafts and subepithelial connective grafts are beneficial in improving soft tissue volume around implants.³⁶

Immediate Type 1 implant placements is associated with soft tissue recession and buccal plate loss regardless of surgical approach.³⁷ Even with the use of bone graft material in the jump gap the ridge width often diminishes.³⁸ Simultaneous connective tissue grafts at the time of implant placement in the aesthetic zone can counteract these dimension changes and maintain the ridge architecture regardless of the soft tissue phenotype at the site (Figure 4A-C).³⁹ These changes can be maintained long term and provide a better aesthetic result for the patient reducing the risk of recession.^{40,41}

As a two-stage implant surgery soft tissue grafts such as CTG can be placed and primary surgical closure can be achieved. This provides an excellent environment for graft revascularization and allows the operator a 'second' opportunity to further improve the soft tissue if required at the second stage implant surgery (Figure 4D-F). Soft tissue augmentation procedures for one stage implant placement are similar for strategies to gain soft tissue volume at the implant uncover stage which is described in the next section.

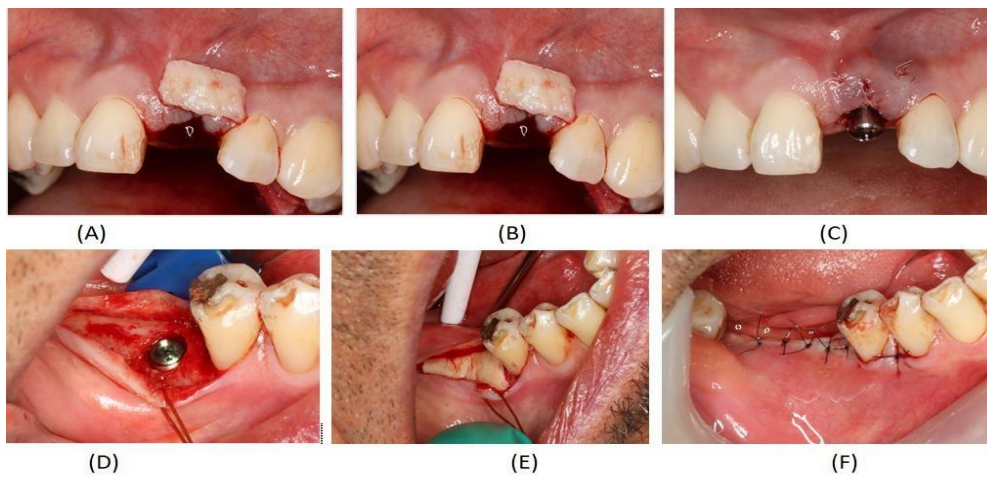


Figure 4: (A) Upper left central incisor crown fractured subgingival; (B) Upper left central incisor root has been extracted and a connective tissue graft has been harvested from the palate ready to place under the buccal gingiva; (C) Connective tissue graft has been secured under the buccal gingiva and immediate implant placed with healing abutment; (D) Implant placement at the lower right first molar site with cover screw; (E) An allograft soft tissue matrix (Alloderm RTM) has been used as an autologous soft tissue substitute; (F) The site is primary closed with the allograft soft tissue matrix buried.

Soft Tissue Procedures after Implant Placement

Implants which are placed with a two-stage approach offers opportunities to further improve the soft tissue at the implant second stage surgery. There are many procedures proposed by authors, each with their indications and desired outcomes. These procedures can be adopted for one stage implant placements. Where possible split thickness flaps are

recommended to limit the amount of bone resorption around the implants associated with lifting the periosteum.⁴²

The strategies to gain attached mucosa and tissue volume differs in the maxilla and the mandible. The maxilla is fortunate to have a large supply of attached keratinized tissue on the palate which can be readily mobilized during second stage surgery (Figure 5A-F) where the mandible may need a free graft to modify the tissue quality (Figure 5G-I).

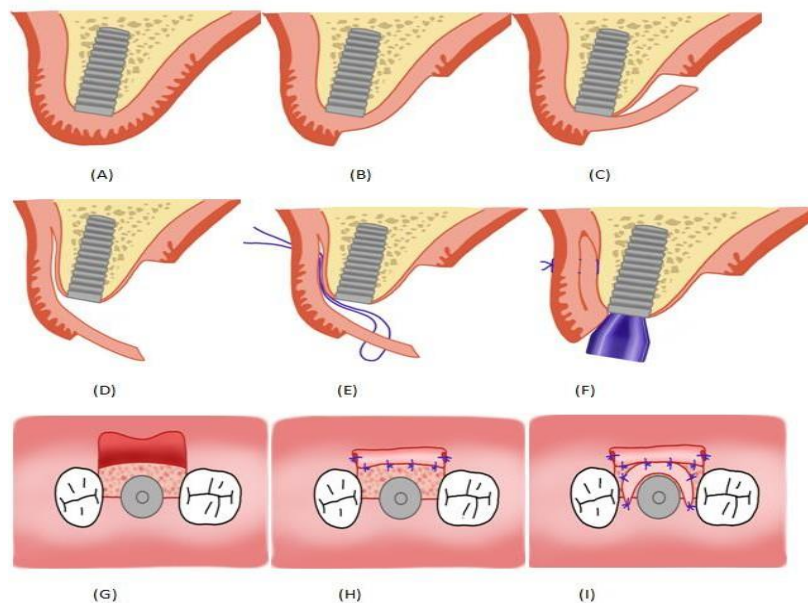


Figure 5: (A) An implant ready to uncover in the maxilla; (B) De-epithelising the palatal keratinised attached mucosa; (C) Split thickness flap elevation from the palate; (D) Split thickness flap extended to the buccal aspect; (E) Palatal aspect of the flap is folded on itself and secured with a horizontal mattress suture; (F) The roll flap is approximated next to the healing abutment; (G) & (H) Uncover of an implant in the mandible where there is limited tissue volume to mobilise from the lingual aspect. An APPTF is prepared and secured to the periosteum; (I) A free gingival graft is adapted around the implant healing abutment to enhance the tissue at the site.

An apically positioned partial thickness flap (APPTF) is indicated to achieve keratinized connected mucosa in the maxilla. AAPTf in the mandible with a free gingival graft in the lower jaw.⁴³ A roll envelope flap is advised in the maxilla to improve volume, and APPTF with a connective tissue graft is recommended in the mandible. In the aesthetic zone there is the

added challenge of creating tissue volume which recreates papilla form around the implant prosthesis. This aids in not just aesthetics but also removes potential food traps at the gingival embrasure. Two easily adopted techniques at second stage surgery are the split finger technique (Figure 6A-F)⁴⁴ and the Palacci flap (Figure 7(A-G)).⁴⁵

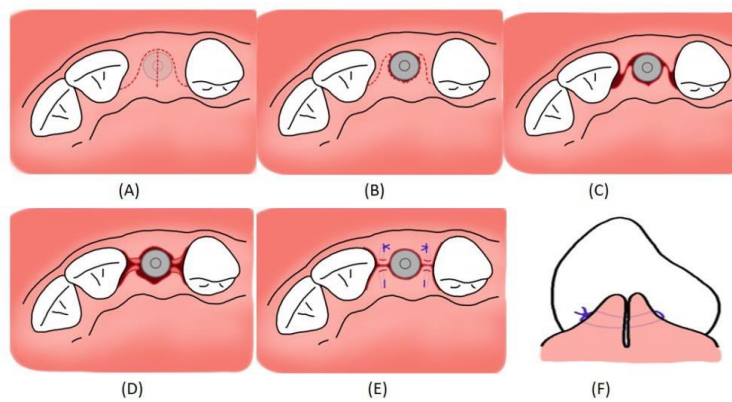


Figure 6: Split finger technique to create papillary soft tissue volume and gain of vertical tissue; (A), (B), (C) Schematic of the incision to be made in the crest to create the surgical papillas; (D) The surgical papillas are elevated and approximated buccal to palatal to form the new anatomic papilla; (E) & (F) Vertical mattress sutures are used to evert and secure the surgical papillas together creating volume and height.

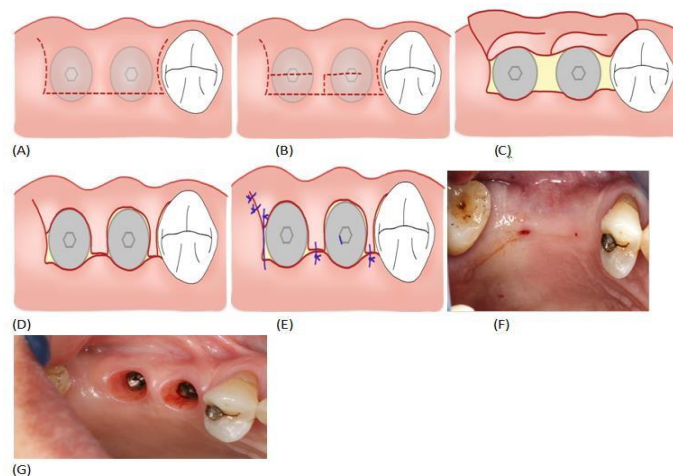


Figure 7: Palacci Flap for two adjacent implants; (A) & (B) Schematic for the incisions for Palacci flap showing the semilunar bevel incisions on the crest; (C) Flap is raised and healing abutments attached to the implants; (D) The semilunar bevels are pedicle flaps which can be rotated between the implants and the adjacent teeth; (E) Flap is sutured to hold the pedicles in place; (F) An edentulous ridge with two implants ready for uncover. Palacci flaps were raised and healing at 3 weeks shows excellent soft tissue volume gain on the buccal and between the implants.

Soft tissue augmentation around osseointegrated and restored implants are also possible. This is commonly performed to correct a recession defect which is an aesthetic or plaque retention concern. In these cases, a coronally advanced flap with a connective tissue graft yields the best result (Figure 8

A-D).⁴⁶ The use of connective tissue grafts sourced from the maxillary tuberosity tended to give better long-term stability and increase keratinized tissue gain compared to graft harvested from the lateral palate (Figure 9 A-D).⁴⁷⁻⁴⁹

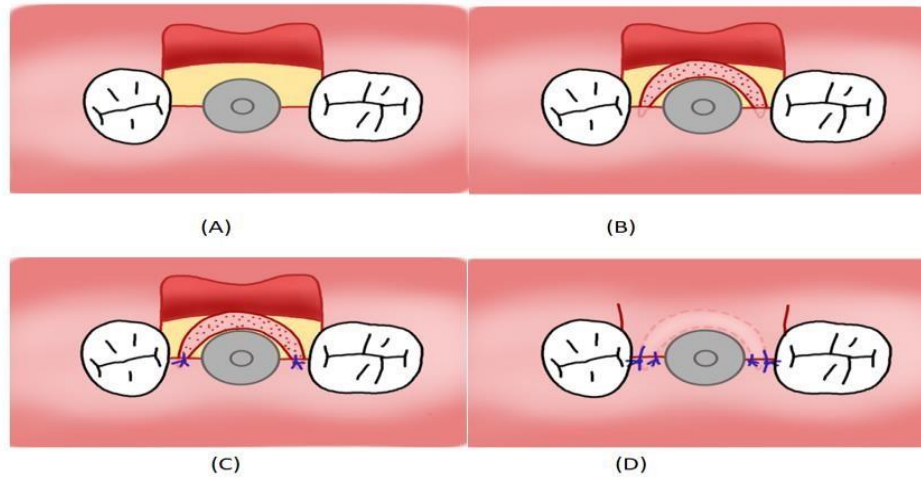


Figure 8: Schematic of a coronally advanced connective tissue graft around an implant with healing abutment; (A) Full thickness flap is raised on the buccal aspect requiring augmentation; (B) A connective tissue graft is shaped and approximated to the recipient site; (C) The connective tissue graft is secured to stable tissue with simple interrupted sutures; (D) The flap is primary closed over the connective tissue graft.

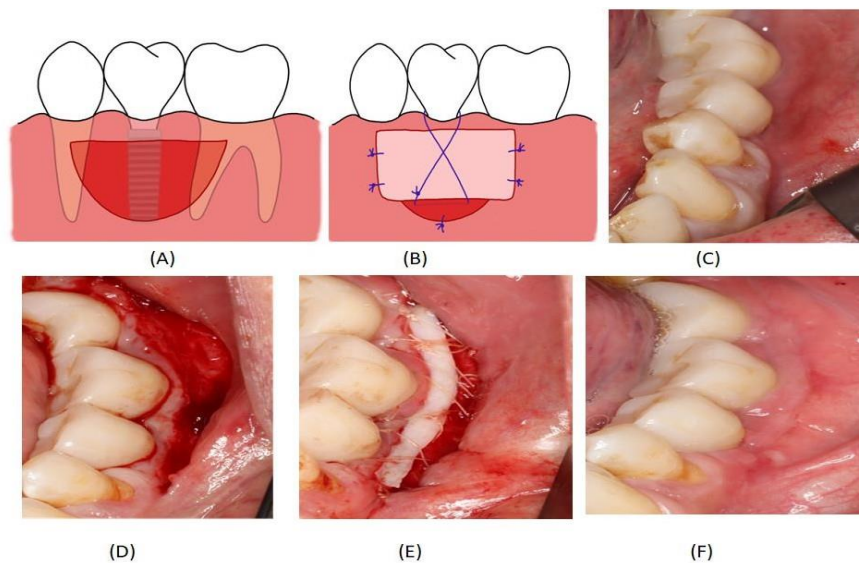


Figure 9: (A) & (B) Schematics of a submarginal free gingival graft with APF around a restored dental implant. A submarginal approach reduces the risks the procedure worsening soft tissue recession around the implant; (C) A case with implants in the lower right quadrant replacing teeth 35, 36 and 37. The site has no attached keratinized mucosa and is tender to oral hygiene and bleeds on probing; (D) Submarginal APTF; (E) FGG sutured to the periosteum bed; (F) 3-month review of the site showing an excellent band of attached keratinized mucosa. There is no more discomfort in performing oral hygiene and the site has healthy periodontal attached tissue with no bleeding on probing.

Conclusion

The increased awareness of the importance of the quantity and quality of the peri-implant soft tissue has resulted in a paradigm shift from a bone driven implant planning process to one that places equal importance to the soft tissue. As Jan Lindhe famously said, “the bone sets the tone but the soft tissue is the issue”. Soft tissue deficiencies can be predictable managed at multiple time points in the implant planning and surgical phases. Early management is recommended to improve the surgical and prosthetic outcomes of implant therapy.

Declarations

Conflict of interest and financial disclosure

The author declares that he has no conflict of interest and there was no external source of funding

for the present study. None of the authors have any relevant financial relationship(s) with a commercial interest.

Ethical approval

Research protocol was approved by the local Ethical Committee (2018/23) and in accordance with those of the World Medical Association and the Helsinki Declaration.

Informed consent

Informed consent was obtained from all individual participants included in the study.

Source of Funding

Non funding.

Availability of Data and Materials

Not applicable.

REFERENCES

1. Albrektsson T, Chrcanovic B, Jacobsson M, Wennerberg A. Osseointegration of implants: a biological and clinical overview. *JSM Dent Surg.* 2017;2(3):1-6.
2. Buser D, Broggini N, Wieland M, et al. Enhanced Bone Apposition to a Chemically Modified SLA Titanium Surface. *J Dent Res.* 2004;3(7):529-33. doi:10.1177/154405910408300704
3. Mombelli A, van Oosten MA, Schurch E, Jr, Land NP. The microbiota associated with successful or failing osseointegrated titanium implants. *Oral Microbiol Immunol.* 1987;2(4):145-51. doi:10.1111/j.1399-302x.1987.tb00298.x
4. Schwarz F, Derks J, Monje A, Wang HL. Peri-implantitis. *J Clin Periodontol.* 2018;20:246-66. doi:10.1111/jcpe.12954
5. Atieh MA, Alsabeeha NH, Faggion CM, Duncan WJ. The frequency of peri-implant diseases: a systematic review and meta-analysis. *J Periodontol.* 2013;84(11):1586-98. doi:10.1902/jop.2012.120592
6. Derks J, Tomasi C. Peri-implant health and disease. A systematic review of current epidemiology. *J Clin Periodontol.* 2015;16:158-71. doi:10.1111/jcpe.12334
7. Rakic M, Galindo-Moreno P, Monje A, et al. How frequent does peri-implantitis occur? A systematic review and meta-analysis. *Clin Oral Investig.* 2018;22(4):1805-16. doi:10.1007/s00784-017-2276-y
8. Berglundh T, Armitage G, Araujo MG, et al. Peri-implant diseases and conditions: Consensus report of workgroup 4 of the 2017 World Workshop on the Classification of Periodontal and Peri-Implant Diseases and Conditions. *J Periodontol.* 2018;1:313-18. doi:10.1111/jcpe.12957
9. Lombardi T, Berton F, Salgarello S, et al. Factors Influencing Early Marginal Bone Loss around Dental Implants Positioned Subcrestally: A

- Multicenter Prospective Clinical Study. *Journal of Clinical Medicine*. 2019;8(8):1168. doi:10.3390/jcm8081168
10. Galindo-Moreno P, León-Cano A, Ortega-Oller I, et al. Marginal bone loss as success criterion in implant dentistry: beyond 2 mm. *Clin Oral Implants Res*. 2015;26(4):28-34. doi:10.1111/clr.12324
11. Berglundh T, Lindhe J. Dimension of the periimplant mucosa. Biological width revisited. *J Clin Periodontol*. 1996;23(10):971-73. doi:10.1111/j.1600-051x.1996.tb00520.x
12. Tomasi C, Tessarolo F, Caola I, et al. Early healing of peri-implant mucosa in man. *J Clin Periodontol*. 2016;43(10):816-824. doi:10.1111/jcpe.12591
13. Tomasi C, Tessarolo F, Caola I, et al. Morphogenesis of peri-implant mucosa revisited: an experimental study in humans. *Clin Oral Implants Res*. 2014;25(9):997-03. doi:10.1111/clr.12223
14. Parpaiola A, Cecchinato D, Toia M, et al. Dimensions of the healthy gingiva and peri-implant mucosa. *Clin Oral Implants Res*. 2015;26(6):657-662. doi:10.1111/clr.12359
15. Ivanovski S, Lee R. Comparison of peri-implant and periodontal marginal soft tissues in health and disease. *Periodontol 2000*. 2018;76(1):116-130. doi:10.1111/prd.12150
16. Avila-Ortiz G, Gonzalez-Martin O, Couso-Queiruga E, Wang HL. The peri-implant phenotype. *J Periodontol*. 2020;91(3):283-88. doi:10.1002/JPER.19-0566
17. Heitz-Mayfield LJ, Lang NP. Comparative biology of chronic and aggressive periodontitis vs. peri-implantitis. *Periodontol 2000*. 2010;53:167-181. doi:10.1111/j.1600-0757.2010.00348.x
18. Albrektsson T. New implant designs and improved surface chemistry. *Clin Implant Dent Relat Res*. 2019;21(1):3-3. doi:10.1111/cid.12743
19. Lin GH, Chan HL, Wang HL. The Significance of Keratinized Mucosa on Implant Health: A Systematic Review. *J Periodontol*. 2013;84(12):1755-1767. doi:10.1902/jop.2013.120688
20. Monje A, Blasi G. Significance of keratinized mucosa/gingiva on peri-implant and adjacent periodontal conditions in erratic maintenance compliers. *J Periodontol*. 2019;90(5):445-53. doi:10.1002/JPER.18-0471
21. Thoma DS, Naenni N, Figuero E, et al. Effects of soft tissue augmentation procedures on peri-implant health or disease: A systematic review and meta-analysis. *Clin Oral Implants Res*. 2018;15:32-49. doi:10.1111/clr.13114
22. Jung RE, Sailer I, Hämmerle CH, Attin T, Schmidlin P. In vitro color changes of soft tissues caused by restorative materials. *Int J Periodontics Restorative Dent*. 2007;27(3):251-57
23. Nauta A, Gurtner G, Longaker MT. Wound healing and regenerative strategies. *Oral Dis*. 2011;17(6):541-49. doi:10.1111/j.1601-0825.2011.01787.x
24. Evans CD, Chen ST. Esthetic outcomes of immediate implant placements. *Clin Oral Implants Res*. 2008;19(1):73-80. doi:10.1111/j.1600-0501.2007.01413.x
25. Munakata M, Nagata K, Sanda M, et al. Variations in vertical mucosal thickness at edentulous ridge according to site and gender measured by cone-beam computed tomography. *Int J Implant Dent*. 2021;7(1):34. doi:10.1186/s40729-021-00319-w
26. Lin CY, Chen Z, Pan WL, Wang HL. Impact of timing on soft tissue augmentation during implant treatment: A systematic review and meta-analysis. *Clin Oral Implants Res*. 2018;29(5):508-21. doi:10.1111/clr.13148
27. Thoma DS, Buranawat B, Hämmerle CH, Held U, Jung RE. Efficacy of soft tissue augmentation around dental implants and in partially edentulous

- areas: a systematic review. *J Clin Periodontol.* 2014;15:77-91. doi:10.1111/jcpe.12220
28. Kan J, Morimoto T, Runcharassaeng K, Roe P, Smith D. Gingival Biotype Assessment in the Esthetic Zone: Visual Versus Direct Measurement. *Int J Periodontics Restorative Dent.* 2010;30(3):237-43.
29. Kloukos D, Koukos G, Doulis I, et al. Gingival thickness assessment at the mandibular incisors with four methods: A cross-sectional study. *J Periodontol.* 2018;89(11):1300-09. doi:10.1002/JPER.18-0125
30. Vanhoutte V, Rompen E, Lecloux G, et al. A methodological approach to assessing alveolar ridge preservation procedures in humans: soft tissue profile. *Clin Oral Implants Res.* 2014;25(3):304-9. doi:10.1111/clr.12144
31. Lambert F, Vincent K, Vanhoutte V, et al. A methodological approach to assessing alveolar ridge preservation procedures in humans: hard tissue profile. *J Clin Periodontol.* 2012;39(9):887-94. doi:10.1111/j.1600-051X.2012.01900.x
32. Chappuis V, Engel O, Reyes M, et al. Ridge Alterations Post-extraction in the Esthetic Zone: A 3D Analysis with CBCT. *J Dent Res.* 2013;92:195-201. doi:10.1177/0022034513506713
33. Jensen SS, Bosshardt DD, Gruber R, Buser D. Long-term stability of contour augmentation in the esthetic zone: histologic and histomorphometric evaluation of 12 human biopsies 14 to 80 months after augmentation. *J Periodontol.* 2014;85(11):1549-56. doi:10.1902/jop.2014.140182
34. Linkevicius T. Zero Bone Loss Concepts. *Quintessence.* 2019
35. Kadkhodazadeh M, Amid R, Kermani ME, Mirakhori M, Hosseinpour S. Timing of soft tissue management around dental implants: a suggested protocol. *Gen Dent.* 2017;65(3):50-6
36. Thoma DS, Mühlemann S, Jung RE. Critical soft-tissue dimensions with dental implants and treatment concepts. *Periodontol 2000.* 2014;66(1):106-18. doi:10.1111/prd.12045
37. Bakkali S, Rizo-Gorrita M, Romero-Ruiz MM, et al. Efficacy of different surgical techniques for peri-implant tissue preservation in immediate implant placement: A systematic review and meta-analysis. *Clin Oral Investig.* 2021;25(4):1655-75. doi:10.1007/s00784-021-03794-y
38. Sanz M, Lindhe J, Alcaraz J, Sanz-Sanchez I, Cecchinato D. The effect of placing a bone replacement graft in the gap at immediately placed implants: A randomized clinical trial. *Clin Oral Implants Res.* 2017;28(8):902-10. doi:10.1111/clr.12896
39. Kan JY, Rungcharassaeng K, Morimoto T, Lozada J. Facial gingival tissue stability after connective tissue graft with single immediate tooth replacement in the esthetic zone: consecutive case report. *J Oral Maxillofac Surg.* 2009;67:40-8. doi:10.1016/j.joms.2009.07.004
40. Migliorati M, Amorfini L, Signori A, Biavati AS, Benedicenti S. Clinical and Aesthetic Outcome with Post-Extractive Implants with or without Soft Tissue Augmentation: A 2-Year Randomized Clinical Trial. *Clin Implant Dent Relat Res.* 2015;17(5):983-95. doi:10.1111/cid.12194
41. Kan JY, Rungcharassaeng K, Lozada JL, Zimmerman G. Facial gingival tissue stability following immediate placement and provisionalization of maxillary anterior single implants: a 2- to 8-year follow-up. *Int J Oral Maxillofac Implants.* 2011;26(1):179-87
42. Fickl S, Kerschull M, Schupbach P, et al. Bone loss after full-thickness and partial-thickness flap elevation. *J Clin Periodontol.* 2011;38(2):157-62. doi:10.1111/j.1600-051X.2010.01658
43. Bassetti RG, Stähli A, Bassetti MA, Sculean A. Soft tissue augmentation procedures at second-stage surgery: A systematic review. *Clin Oral*

- Investig.* 2016;20(7):1369-87. doi:10.1007/s00784-016-1815-2
44. Misch CE, Al-Shammari KF, Wang HL. Creation of interimplant papillae through a split-finger technique. *Implant Dent.* 2004;13(1):20-7. doi:10.1097/01.id.0000116368.76369.78
45. Palacci P, Nowzari H. Soft tissue enhancement around dental implants. *Periodontol 2000.* 2008;47:113-32. doi:10.1111/j.1600-0757.2008.00256.x
46. Bassetti RG, Stähli A, Bassetti MA, Sculean A. Soft tissue augmentation around osseointegrated and uncovered dental implants: a systematic review. *Clin Oral Investig.* 2017;21(1):53-70. doi:10.1007/s00784-016-2007-9
47. Rojo E, Stroppa G, Sanz-Martin I, Gonzalez-Martín O, Nart J. Soft tissue stability around dental implants after soft tissue grafting from the lateral palate or the tuberosity area – A randomized controlled clinical study. *J Clin Periodontol.* 2020;47(7):892-99. doi:10.1111/jcpe.13292
48. Rojo E, Stroppa G, Sanz-Martin I, et al. Soft tissue volume gain around dental implants using autogenous subepithelial connective tissue grafts harvested from the lateral palate or tuberosity area. A randomized controlled clinical study. *J Clin Periodontol.* 2018;45(4):495-03. doi:10.1111/jcpe.12869
49. Roccuzzo M, Gaudio L, Bunino M, Dalmaso P. Surgical treatment of buccal soft tissue recessions around single implants: 1-year results from a prospective pilot study. *Clin Oral Implants Res.* 2014;25(6):641-46. doi:10.1111/clr.12149

ԱՏԱՄՆԵՐԻ ԻՄՊԼԱՆՏՆԵՐԻ ՇՈՒՐՉ ՓԱՓՈՒԿ ՀՅՈՒՄԱԿՆԵՐԻ ԲԱՐԵԼԱՎՈՒՄ - ԳՐԱԿԱՆՈՒԹՅԱՆ ԱԿՆԱՐԿ

Կոմալ Կ.Գաջ, Շարաթ Կ. Շեթթի, Անիտա Կուլոլի, Զեթան Դեշետտի, Դիարմարաջան Գոպալաքրիշնան

Պարոդոնտոլոգիայի և բերանի խոռոչի իմպլանտոլոգիայի բաժանմունք, Dr. D.Y. Patil Dental College and Hospital, Pimpri, Pune-411018, Maharashtra, Հնդկաստան

Ամփոփում

Ատամնարուժական իմպլանտները ավանդաբար կենտրոնացած են ոսկորների որակի և քանակի վրա՝ իմպլանտը տեղավորելու և հաջողությամբ վերականգնելու համար: Կոշտ մակերեսով իմպլանտներն ապահովում են կանխատեսելի օստեոինտեգրացիա, բայց բերանի միջավայրի ազդեցության դեպքում հանգեցնում են պերիիմպլանտիտի զարգացմանը: Պերիիմպլանտի լորձաթաղանթն ապահովում է հիմքում ընկած ոսկորի պաշտպանությունը իմունային պատասխանի միջոցով և պաշտպանում է գազաթային բիոֆիլմի միգրացիայից: Կերատինացված լորձաթաղանթի համապատասխան շերտը նաև բարելավում է բերանի խոռոչի հիգիենայի հարմարավետությունը, սահմանափակում է ոսկորի վաղ եզրային կորուստը և բարելավում է էպթետիկ արդյունքները իմպլանտների ատամնաշարի շուրջ: Այս հոդվածի նպատակն է տրամադրել գրականության վերանայում ատամնարուժական իմպլանտների շուրջ կերատինացված լորձաթաղանթի կցման կարևորության վերաբերյալ: Այն նաև նկարագրում է պարզ ռազմավարություններ՝ բարելավելու պերիիմպլանտային լորձաթաղանթի առողջությունը իմպլանտների տեղադրումից առաջ, ընթացքում և հետո:

УЛУЧШЕНИЕ МЯГКИХ ТКАНЕЙ ВОКРУГ ЗУБНЫХ ИМПЛАНТАТОВ – ОБЗОР ЛИТЕРАТУРЫ

Комал К. Гадж, Шарат К.Шетти, Анита Куллоли, Кетан Дешетти, Дхармараджан Гопалакришнан

Кафедра пародонтологии и оральной имплантологии, Стоматологический колледж и больница доктора Д.Й. Патила, Пимпри, Пуна-411018, Махараштра, Индия.

Абстракт

Зубные имплантаты традиционно ориентированы на качество и количество кости для размещения зубного имплантата и успешного восстановления беззубого гребня. Имплантаты с шероховатой поверхностью обеспечивают предсказуемую остеоинтеграцию, но приводят к развитию периимплантита при воздействии среды полости рта. Слизистая оболочка вокруг имплантата обеспечивает защиту подлежащей кости посредством иммунного ответа и защиты от миграции апикальной биопленки.

Адекватная полоса кератинизированной слизистой оболочки также повышает комфорт при выполнении гигиены полости рта, ограничивает раннюю потерю маргинальной костной ткани и улучшает эстетические результаты вокруг протезов на имплантатах.

Цель этой статьи — предоставить обзор литературы о важности прикрепления ороговевшей слизистой оболочки вокруг зубных имплантатов. В нем также описаны простые стратегии улучшения состояния слизистой оболочки вокруг имплантата до, во время и после установки имплантата.



ORIGINAL ARTICLE

APPLICATION OF THE METHOD OF FREQUENCY-RESONANCE ANALYSIS OF
IMPLANTS INSTALLED AFTER AUTOGENOUS BONE TRANSPLANTATION

Gagik Hakobyan,^{1*} Lazar Yessayan,² Hovhannes Karapetyan,³ Yuri Azbekyan,⁴ Davit Mathevosyan⁵

- ¹ Professor, Head of Department of Oral and Maxillofacial Surgery, Yerevan State Medical University after M. Heratsi, Armenia
² Professor, Head of Department of Therapeutic Stomatology, Yerevan State Medical University after M. Heratsi, Armenia
³ Center of Excellence in Dental Education Yerevan State Medical University after M. Heratsi, Armenia
⁴ Student, Faculty of Stomatology Yerevan State Medical University after M. Heratsi, Armenia
⁵ Assistant Professor, Department of Oral and Maxillofacial Surgery, Yerevan State Medical University after M. Heratsi, Armenia

* Corresponding author: Professor Gagik Hakobyan DMSc, PhD, Head of Department of Oral and Maxillofacial Surgery, University of Yerevan State Medical University, Yerevan, Armenia
e-mail: prom_hg@yahoo.com

Received: Oct. 2, 2023; **Accepted:** Oct. 27, 2023; **Published:** Nov. 5, 2023

Abstract

Background: Purpose of study determine the timing of prosthetic rehabilitation of patients after autograft and dental implantation of the jaw bone using resonance-frequency method (RFA).

Methods: The analysis of the treatment of 34 with vertical resorption of the lower jaws, and dental implant prosthetic rehabilitation performed for the period 2020-2023. All patients underwent a complex clinical, laboratory study, computed tomography (CT). At the first stage, the autogen bone grafting procedure, at the second stage, 4 months after autogen bone grafting implants were installed. 3 months later, after implants inserted to determine the timing of prosthetic rehabilitation, the method of RFA-Resonance Frequency Analysis method was used, if normal results were recorded, the prosthodontic phase began. Postoperative clinical and radiological monitoring was regularly conducted, and criteria for the success of implantation and success of prosthetics of implant-supported reconstructions were evaluated. Change in marginal bone levels was assessed by taking digital x-rays immediately after restoration fixation (base line for comparison), after 1 and 3, 5 years post operatively.

Results: No intra-operative or immediate post-operative complications were noted after autografting procedure. The postoperative of the patients was favorable, with the integration of the autografts. 3 months after autogenous bone grafting, the resorption of the graft in some transplant recipients is up to 10%. All of the patients presented with healthy soft tissue. Marginal bone loss data were recorded, mean marginal bone loss (MBL) was 1.2 ± 0.25 mm after 3 years. The mean RFA recordings of all 136 implants were 65 ISQ at implant placement respectively 73 ISQ after 3 months. The functional load on dental implants was performed with ISQ values above 65 (dental prosthetic rehabilitation was performed after 3-4 months of submerged healing). A total of 8 implant failures were recorded. After 5 years show survival rates 97.

Conclusions: RFA could serve as a noninvasive diagnostic tool for detecting implant stability during healing stages and subsequent routine follow ups. The method of resonance-frequency analysis allows us to determine the timing of the beginning of the prosthetic stage in each specific case.

Keywords: adhesive system, trace element composition, hybrid zone.

Introduction

The problem of orthopedic rehabilitation of patients with maxillofacial defects of the jaws is one of the most pressing problems of modern reconstructive maxillofacial surgery.

Acquired maxillofacial defects are usually accompanied by severe functional and aesthetic impairments, impaired socio-psychological adaptation of this category of patients.¹

These can be defects of a traumatic and inflammatory nature, flaws that arise as a result of the removal of pathological purulent foci.

Long-term tooth loss leads to significant bone resorption, which makes implant placement difficult, causing functional and aesthetic problems.²⁻⁴ Particularly difficult problems arise with pronounced vertical bone resorption, since the use of osteoplastic materials does not provide the necessary restoration of bone tissue parameters.⁵⁻⁸

In case of insufficient quantitative parameters of the jaws in patients, various bone-growth operations are performed to prepare for implantation.⁹⁻¹²

The use of bone grafts is the standard for atrophied bone repair, as they contain both osteogenic cells and an osteoconductive mineralized extracellular matrix where they can grow.

For the restoration of bone tissue in such clinical situations, the use of autogenous grafts is highly effective in comparison with other methods.¹¹⁻¹⁴

According to many authors, the two-stage method is more predictable and reliable, since during this period the autograft matures and has good blood circulation,

In the case of serious defects, there is a risk of resorption of the autograft volume before implant placement or after orthopedic rehabilitation.^{15,16}

Radiographic diagnostic data assessing the condition of bone tissue after reconstructive surgery show that the bone tissue undergoes changes over time after surgery, gradually increasing in density, reaching a maximum within six months.¹⁷ Based on the above, it should be noted that this period is the most expedient for the placement of implant.

Usually, implant stability and osseointegration have been assessed using various techniques, including insertion torque, percussion testing and radiographic analysis.^{18,19} Loading protocols and

healing time for individual patients are often empirically calculated based on clinical research studies evaluating implant stability and osseointegration over time.

Analysis of scientific publications shows that the most modern and reliable clinical method for assessing the stability of dental intraosseous implants is the method of resonance frequency analysis (RFA).²⁰

The method is based on the registration of resonant electromagnetic oscillations of the implant surrounding the bone when exposed to an electromagnetic field by means of an electronic sensor. RFA-Resonance Frequency Analysis developed by N. Meredith²¹ is widely used to objectively assess the quality of bone tissue.

This test records the resonant spectrometric vibrations of a Smart peg post attached to an implant under the influence of an electromagnetic field. Performed by the device Osstell-mentor ISQ (Integration Diagnostics, Gothenburg, Sweden) is an objectively informative method for assessing the osseointegration of an implant. RFA allows you to determine the timing of the load on the implant and for the early diagnosis of complications. The Implant Stability Index (ISQ) is recorded on the screen of the device, the higher the index, the stronger the implant fixation. Higher bone density has been positively correlated with higher RFA values. According to N. Meredith, the index of primary stability of the implant in the upper jaw is -58 ISQ, and in the lower jaw - 66 ISQ.²²

Despite numerous scientific studies using this method, there are few publications in which the method of resonance frequency analysis is used to determine the time of the functional load of implants installed in an autologous bone graft.²³

Considering the above, this method was included in our study, among other diagnostic methods, for an objective assessment of the stability of the implant and to determine the optimal timing of orthopedic treatment in the area of bone regeneration. All of the above confirms the urgency of the problem and determined the purpose of this study.

Purpose of study determine the timing of orthopedic rehabilitation of patients after autograft reconstructive operations on the jaw using the method

of dental implantation using resonance-frequency method.

Materials and methods

The analysis of the treatment of 34 patients (men-14, women-12, age from 28 to 63 years) with vertical resorption of the lower jaws, performed for the period 2020-2023. The following criteria were with drawn from this study the presence of somatic, endocrine, oncological, infectious diseases, blood diseases, pregnancy.

All patients provided written consent to be included in this study and to use facial images for the purposes of the study. All patients underwent a complex clinical, X-ray, laboratory study, computed tomography (CT). The treatment was planned taking into account the parameters of the bone tissue in the area of the missing teeth. After research and diagnosis, a treatment plan was drawn up, including an implant surgery followed by prosthodontic treatment.

At the first stage, auto-transplantation was carried out in the chewing areas of the lower jaw, at the second stage, after four months further implantation. The treatment plan was agreed with the patient. The autograft was taken from the chin or retromolar areas of the mandible. The operation was performed under premedication and local anesthesia. The autograft was adapted and fixed in the donor area with titanium screws, the empty space in the donor area was filled with bone material and then closed with resorbable membrane Bio Oss. After reposition of the mucous membrane, sutures were applied. Prophylactic anti-inflammatory therapy and local antiseptic measures were carried out. The postoperative period was calm, without complications.

136 dental implants were installed in the edentulous arches using surgical guides. Implants were installed 3 months after autogenous bone grafting. After implant insertion, preventive complex anti-inflammatory therapy was performed, the patient was under dynamic control. 4 months later, the implant closure screws were removed, the smart peg pin was fixed to the implants and determine the timing of prosthetic rehabilitation, the method of RFA-

Resonance Frequency Analysis method was used, if normal results were recorded, the prosthodontic phase began.

Digital technologies were included in the workflow with the laboratory scanning of the master casts and CAD/CAM manufacturing software. The orthopedic treatment was performed using metal-ceramic implant-based fixed orthopedic structures.

Postoperative clinical and radiological monitoring was regularly conducted, and criteria for the success of implantation and success of prosthetics of implant-supported reconstructions were evaluated. Outcome measures were: graft success, implant success; complications and marginal bone levels, prosthesis success. Change in implants marginal bone levels was assessed by taking digital x-rays immediately after restoration fixation (base line for comparison), after 1, 3- and 5-years post after one and three years post operatively.

Statistical analysis

Statistical analysis was performed using the statistical software package SPSS 23 (Statistical Package for Social Science 23).

Results

No intra-operative or immediate post-operative complications were noted and no flap failure occurred. The postoperative of the patients was favorable, with the integration of the autografts. Complete engraftment of bone autografts and wound healing was obtained in all observations. 3 months after autogenous bone grafting, the resorption of the graft in some transplant recipients is up to 10%. 6-month follow-up period evaluation of CT scan revealed implants demonstrated to integrate normally. All of the patients presented with healthy soft tissue. Marginal bone loss data were recorded, mean marginal bone loss (MBL) was 1.2 ± 0.25 mm. After 5 years show survival rates 97.6% The mean RFA recordings of all 104 implants were 65 ISQ at implant placement respectively 73 ISQ after 3 months. The functional load on dental implants was performed with

ISQ values above 65 (dental prosthetic rehabilitation was performed after 3-4 months of submerged healing) (Figure 1-10). According to the given computed tomography, patients, who underwent autograft surgery of the vertical resorption, had an average height of 6.2mm and after graft surgery 12.8mm.

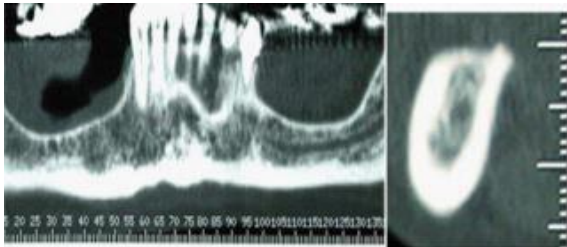


Figure 1 (a, b). CT scan before autograft

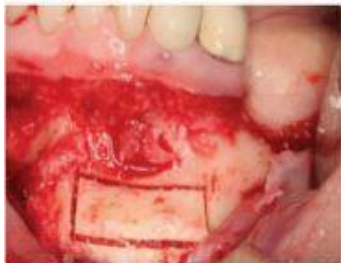

Figure 2. The autograft from the chin areas

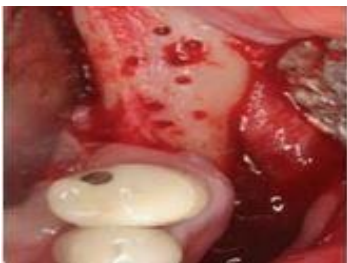

Figure 3. Recipient area before autograft surgery with round bar

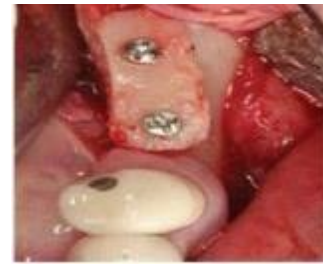

Figure 4. The autograft was adapted and fixed in the donor area with titanium screws

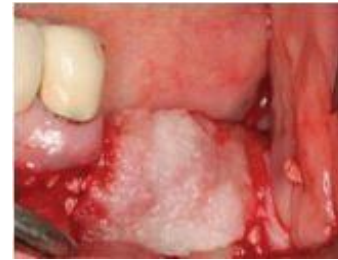

Figure 5. Intraoral clinical view, the empty space in the donor area was filled with bone material Bio Oss and then closed with resorbable membrane

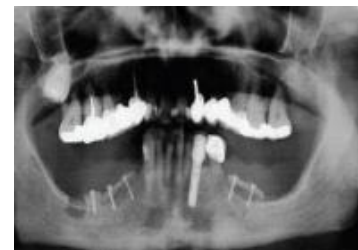

Figure 6. CT scan after autograft surgery, the autograft was adapted and fixed in the donor area with titanium screws

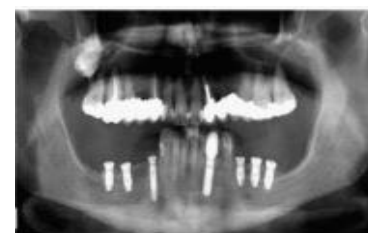

Figure 7. CT scan after implants insertion

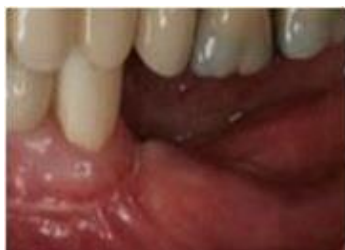

Figure 8. Intraoral clinical view before implant screws removed

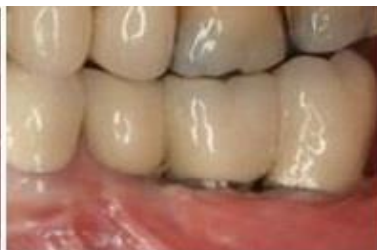

Figure 9. Intraoral view after prosthetic rehabilitation

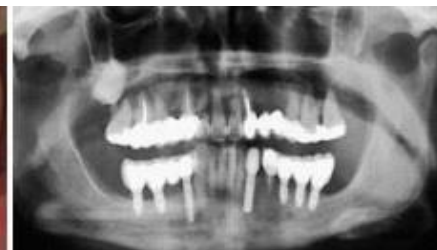

Figure 10. CT scan after prosthetic rehabilitation

Discussion

Dental implants are a predictive and reliable treatment option, provided there is a sufficient quantity and quality of bone to achieve the desired functional and aesthetic results.²⁴ When using implants, jaw atrophy is sharply slowed down to the physiological level, which undoubtedly plays an important role in implant placement. For effective implantation, sufficient parameters of the bone tissue in the implantation zone are required. However, unfavorable conditions, due to oral infections, bone atrophy after dental extractions, and long term edentulism, may result in insufficient available bone, making implant placement impossible. In case of bone deficiency, bone grafting is performed using Guided bone regeneration, autogenous bone grafting, distraction osteogenesis, ridge-split. Autogenous bone transplants are the gold standard for bone grafting, but the difficulty of obtaining the graft and the soreness of the donor part of the jaw hinders their use.²⁵⁻³²

Currently, after bone grafting, however resorption of bone materials after surgery and complications limits their use, which is especially important for vertical resorption, in which vertical bone augmentation is effective only during autogenous plastic surgery.^{33,34}

The timing of implant insertion after bone grafting is important for the effectiveness of osteointegration in the area of bone grafting, taking into account the risk of resorption of the graft and according to numerous reports, the percentage after autogenous grafting is 20-30 percent.³⁵⁻³⁷

The degree of maturity of the autograft and the readiness of implant insertion in the area is determined according to the data of the catheter and according to certain bones.^{37,38}

In the literature, there are few publications on the determination of the timing of the functional load of implants installed in the area of bone grafting, which prompted this study.³⁹

ISQ readings can be used to determine different healing phases and the stability of dental implants.^{40,41}

The results of a clinical study prove the reliability of autologous bone grafts for pre-prosthetic reconstruction of the alveolar ridge before implant placement. High graft success rate (95.6%) and implant failure rate (2,4% periimplantitis). Our

observations of patients treated with this technique prove that intraoral and extraoral autologous bone grafts should be considered the gold standard for preprosthetic dentoalveolar reconstruction. This study demonstrates that the reconstruction of atrophic jaws using bone grafts from intraoral donor sites is a predictable technique for the dental rehabilitation of patients with crestal atrophy associated with high bone survival and implantation success. Currently, despite the fact that there are many bone substitutes, autologous bone is considered as the most effective material for two-stage preprosthetic augmentation for oral implantation. Intraoral autologous grafts can be a reliable option for restoring the resorbed mandible with further implant placement. Autologous overhead grafts from the ramus of the mandible, symphysis, offer sufficient bone volume to restore an atrophic jaw and are excellent treatment alternatives for patients when reconstruction is required prior to implant placement. In addition to the successful reconstruction of the alveolar ridge with the correct choice of the donor site, the pain of the procedure should be minimal, this study presents results of treatment effectiveness 26 patients with lower jaw edentulous and with vertical atrophy. 104 implants were installed for arch reconstructions after autograft and dental implant and 4 months later, the implant closure screws were removed, the smart peg pin was fixed to the implant. The resonance frequency analysis method (RFA-) use to determine the timing of the beginning of the prosthetic stage, if normal results were recorded, the prosthodontic phase began. ISQ gradually increases after implant placement, and in case of a decrease in the index due to implant overload, timely therapeutic and preventive measures are taken to prevent loss of the implant.

Conclusions

The results of this study indicated the prosthetic rehabilitation of patients after autograft and dental implant at prosthetic rehabilitation of the jaw bone can provide good esthetic and functional results. RFA could serve as a noninvasive diagnostic tool for detecting implant stability during healing stages and subsequent routine follow ups. The method of resonance-frequency analysis allows us to determine

the timing of the beginning of the prosthetic stage in each specific case.

Declarations

Conflict of interest and financial disclosure

The author declares that he has no conflict of interest and there was no external source of funding for the present study. None of the authors have any relevant financial relationship(s) with a commercial interest.

Ethical approval

Research protocol was approved by the local Ethical Committee (2018/23) and in accordance with

those of the World Medical Association and the Helsinki Declaration.

Informed consent

Informed consent was obtained from all individual participants included in the study.

Source of Funding

Non funding.

Availability of Data and Materials

Not applicable.

Acknowledgements

Not applicable.

REFERENCES

1. Dings JPI, Merckx MAW, de Clonie Maclennan-Naphausen MTP, van de Pol P, Maal TJJ, Meijer GJ. Maxillofacial prosthetic rehabilitation: A survey on the quality-of-life Affiliations expand. *J Prosthet Dent.* 2018;120(5):780-786. doi:10.1016/j.prosdent.2018.03.032
2. Ahmed W, Adil Asim M, Ehsan A, Abbas Q. Non-Vascularized Autogenous Bone Grafts for Reconstruction of Maxillofacial Osseous Defects. *J Coll Physicians Surg Pak.* 2018;28(1):17-21. doi:10.29271/jcpsp.2018.01.17
3. Buser D, Dula K, Belser UC, Hirt HP, Berthold H. Localized ridge augmentation using guided bone regeneration. II. Surgical procedure in the mandible. *Int J Periodontics Restorative Dent.* 1995;15(1):10-29
4. Chiapasco M, Casentini P, Zaniboni M. Bone Augmentation Procedures in Implant Dentistry. *The International Journal of Oral & Maxillofacial Implants.* 2009;24:237-259
5. Bak MM, Jacobson AS, Buchbinder D, et al. Contemporary Reconstruction of the Mandible. *Oral Oncology.* 2010;4:71-76. doi:10.1016/j.oraloncology.2009.11.006
6. Falisi G, Galli M, Velasquez PV, Rivera JCG, Di Paolo C. Implant stability evaluation by resonance frequency analysis in the fit lock technique. A clinical study. *Ann Stomatol (Roma).* 2013;4(2):196-203
7. Cassetta M, Ricci L, Iezzi G, Dell'Aquila D, Piattelli A, Perrotti V. Resonance frequency analysis of implants inserted with a simultaneous grafting procedure: a 5-year follow-up study in man. *Int J Periodontics Restorative Dent.* 2012;32(5):581-589
8. Aloja ED, Ricci M, Caso G, et al. The use of bone block allografts in sinus augmentation, followed by delayed implant placement: Case Series. *Clinical Dentistry.* 2013;4(1):175-185. doi:10.4103/0976-237X.111587
9. Buser D, Dula K, Belser UC, Hirt HP, Berthold H. Localized ridge augmentation using guided bone regeneration. II. Surgical procedure in the mandible. *Int J Periodontics Restorative Dent.* 1995;15(1):10-29

10. Cebrian-Carretero JL, Guiñales-Díaz de Cevallos J, Sobrino JA, Yu T, Burgueño-García M. Predictable dental rehabilitation in maxillomandibular reconstruction with free flaps. The role of implant guided surgery. *Med Oral Patol Oral Cir Bucal*. 2012;19(6):605- 611. doi:10.4317/medoral.19116
11. Kim YK, Ku JK. Ridge augmentation in implant dentistry. *Journal of the International Clinical Dental Research Organization*. 2015;7(1):95-112. doi:10.5125/jkaoms.2020.46.3.211
12. Harshakumar K, Varghese NM, Ravichandran R, Lylajam S. Alveolar Ridge Augmentation using Autogenous Block Bone Grafts Harvested from Mandibular Ramus to Facilitate Implant Placement: A Case Report. *International Journal of Scientific Study*. 2014;2(1):46-50
13. Assoumane A, Liu K, Shao Z, Shang ZJ. Double Barrel Fibula Flap with Immediate Dental Implant Insertion for Reconstruction of Mandibular Defects. *Global Journal of Otolaryngology*. 2018;14(1):121-26. doi:10.19080/GJO.2018.13.555876
14. Dawood A, Susan T, Hutchison I. Computer Guided Surgery for Implant Placement and Dental Rehabilitation in a Patient Undergoing Sub-Total Mandibulectomy and Microvascular Free Flap Reconstruction. *Jour. of Oral Implant*. 2013;35(4):497-502. doi:10.1563/AAID-JOI-D-11-00142
15. van der Meij AJ, Baart JA, Prahl-Andersen B, Valk J, Kostense PJ, Tuinzing DB. Computed tomography in evaluation of early secondary bone grafting. *Int J Oral Maxillofac Surg*. 1994;23:132-136. doi:10.1016/s0901-5027(05)80286-3
16. Swami V, Vijayaraghavan V, Swami V. Current trends to measure implant stability. *J Indian Prosthodont Socv*. 2016;16(2):124–130. doi:10.4103/0972-4052.176539
17. Mall N, Dhanasekar B, Aparna IN. Validation of implant stability: A measure of implant permanence. *Indian J Dent Res*. 2011;22(3):462-7. doi:10.4103/0970-9290.87071
18. Quesada-García MP, Prados-Sánchez E, Olmedo-Gaya MV, Muñoz-Soto E, González-Rodríguez MP, Vallecillo-Capilla M. Measurement of dental implant stability by resonance frequency analysis: A review of the literature. *Med Oral Patol Oral Cir Bucal*. 2009;14(10):538-46. doi:10.4317/medoral.14.e538
19. Meredith N. Assessment of implant stability as a prognostic determinant. *Int J Prosthodont*. 1998;11(5):491-501
20. Meredith N, Alleyne D, Cawley P. Quantitative determination of the stability of the implant- tissue interface using resonance frequency analysis. *Clin Oral Implants Res*. 1996;7:261–267. doi:10.1034/j.1600-0501.1996.070308.x
21. Vallecillo-Rivas M, Reyes-Botella C, Vallecillo C, Lisbona-González MJ, Vallecillo-Capilla M, Olmedo-Gaya MV. Comparison of Implant Stability between Regenerated and Non-Regenerated Bone. A Prospective Cohort Study. *J Clin Med*. 2021;10(15):3220. doi:10.3390/jcm10153220
22. Montero J. A Review of the Major Prosthetic Factors Influencing the Prognosis of Implant Prosthodontics. *J Clin Med*. 2021;10:816. doi:10.3390/jcm10040816
23. Titsinides S, Agrogiannis G, Karatzas T. Bone grafting materials in dentoalveolar reconstruction: A comprehensive review. *Jpn Dent Sci Rev*. 2019;55(1):26-32. doi:10.1016/j.jdsr.2018.09.003
24. Stricker A, Schramm A, Marukawa E, Lauer G, Schmelzeisen R. Distraction osteogenesis and tissue engineering-new options for enhancing the implant site. *Int J Periodontics Restorative Dent*. 2003;23(3):297-302.
25. Buser D, Dula K, Hirt HP, Schenk RK. Lateral ridge augmentation using autografts and barrier membranes: Clinical study with 40 partially edentulous patients. *J Oral Maxillofac Surg*. 1996;54:420-432. doi:10.1016/S0278-2391(96)90113-5

26. Moses O, Nemcovsky CE, Langer Y, Tal H. Severely resorbed mandible treated with iliac crest autogenous bone graft and dental implants: 17-year follow-up. *Int J Oral Maxillofac Implants*. 2007;22:1017-1021
27. Sakkas A, Wilde F, Heufelder M, Winter K, Schramm A. Autogenous bone grafts in oral implantology - is it still a “gold standard”? A consecutive review of 279 patients with 456 clinical procedures. *Int J Implant Dent*. 2017;3:23. doi:10.1186/s40729-017-0084-4
28. Von Arx T, Buser D, Horizontal ridge augmentation using autogenous block grafts and the guided bone regeneration technique with collagen membranes: A clinical study with 42 patients. *Clinical Oral Implants Research*. 2006;17(4):359-366. doi:10.1111/j.1600-0501.2005.01234.x
29. Cordaro L, Amadè DS, Cordaro M. Clinical results of alveolar ridge augmentation with mandibular block bone grafts in partially edentulous patients prior to implant placement. *Clinical Oral Implants Research*. 2002;13(1):103-111. doi:10.1034/j.1600-0501.2002.130113.x
30. Sheikh Z, Corneliu Sima C, Glogauer M. Bone Replacement Materials and Techniques Used for Achieving Vertical Alveolar Bone Augmentation *Materials (Basel)*. 2015;8(6):2953–2993. doi:10.3390/ma8062953
31. Gultekin BA, Bedeloglu E, Emre Kose T, Mijiritsky E. Comparison of Bone Resorption Rates after Intraoral Block Bone and Guided Bone Regeneration Augmentation for the Reconstruction of Horizontally Deficient Maxillary Alveolar Ridges. *Clinical Study*. 2016;4987437. doi:10.1155/2016/4987437
32. Jensen AT, Jensen SS, Worsaae N. Complications related to bone augmentation procedures of localized defects in the alveolar ridge. A retrospective clinical study. *Oral Maxillofac Surg*. 2016;20(2):115-122. doi:10.1007/s10006-016-0551-8
33. Sakkas A, Wilde F, Heufelder M, Winter K, Schramm A. Autogenous bone grafts in oral implantology—is it still a “gold standard”? A consecutive review of 279 patients with 456 clinical procedures. *Int J Implant Dent*. 2017;3:23. doi:10.1186/s40729-017-0084-4
34. Nkenke E, Neukam FW. Autogenous bone harvesting and grafting in advanced jaw resorption: morbidity, resorption and implant survival. *Eur J Oral Implantol*. 2014;7(2):203-17
35. Maiorana C, Beretta M, Salina S, Santoro F. Reduction of autogenous bone graft resorption by means of Bio-Oss coverage: A prospective study. *Int J Period Rest Dent*. 2005;1:19–25.
36. Alérico FA, Bernardes SR, Fontão FN GK, Diez GF, Alérico JHS, Claudino M. Prospective tomographic evaluation of autogenous bone resorption harvested from mandibular ramus in atrophic maxilla. *Journal of Craniofacial Surgery*. 2014;25(6):543–546. doi:10.1097/SCS.0000000000001045
37. Meenakshi S, Raghunath N, Raju SN, Srividya S, Indira PN. Implant stability a key determinant in implant integration. *Trends Prosthodont Dent Implantol*. 2013;4:28–48
38. Ersanli S, Karabuda C, Beck F, Leblebicioglu B. Resonance frequency analysis of one-stage dental implant stability during the osseointegration period. *J Periodontol*. 2005;76(7):1066-71. doi:10.1902/jop.2005.76.7.1066
39. Andreotti AM, Goiato MC, Nobrega AS, et al. Relationship Between Implant Stability Measurements Obtained by Two Different Devices: A Systematic Review. *Periodontol*. 2017;88(3):281-288. doi:10.1902/jop.2016.160436. Epub 2016 Oct 21

ԱՌՏՏՈՒՄԵՆ ՈՍԿՐԱՅԻՆ ՓՈԽՊԱՏՎԱՍՏՈՒՄԻՑ ՀԵՏՈՍ ՏԵՂԱԴՐՎԱԾ ԻՄՊԼԱՆՏՆԵՐԻ ՀԱՃԱԽԱԿԱՆ-ՌԵԶՈՆԱՆՍԱՅԻՆ ՎԵՐԼՈՒԾՈՒԹՅԱՆ ՄԵԹՈԴԻ ԿԻՐԱՐՈՒՄ

Գազիկ Հակոբյան,¹ Լազար Եսայան,² Հովհաննես Կարապետյան,³ Ազբեկյան Յուրի,⁴ Դավիթ Մաթևոսյան⁵

- ¹ Պրոֆեսոր, Երևանի Մ. Հերացու անվան պետական բժշկական համալսարանի վիրաբուժական ստոմատոլոգիայի և դիմաձնոտային վիրաբուժության ամբիոնի վարիչ, Հայաստան
- ² Պրոֆեսոր, Երևանի Մ. Հերացու անվան պետական բժշկական համալսարանի թերապևտիկ ստոմատոլոգիայի ամբիոնի վարիչ, Հայաստան
- ³ Երևանի Մ. Հերացու անվան պետական բժշկական համալսարանի Ստոմատոլոգիական կրթության գերազանցության կենտրոն, Հայաստան
- ⁴ Երևանի Մ. Հերացու անվան պետական բժշկական համալսարանի Ստոմատոլոգիական ֆակուլտետի ուսանող, Հայաստան
- ⁵ Երևանի Մ. Հերացու անվան պետական բժշկական համալսարանի վիրաբուժական ստոմատոլոգիայի և դիմաձնոտային վիրաբուժության ամբիոնի ասիստենտ

Ամփոփում

Նպատակ. Հետազոտության նպատակը որոշել է հիվանդների պրոթեզային վերականգնման ժամկետները ծնոտի ոսկորների ավտոփոխպատվաստումից և իմպլանտացիայից հետո՝ օգտագործելով ռեզոնանսային հաճախականության մեթոդը (RFA):

Մեթոդներ. Ստորին ծնոտների ուղղահայաց ռեզորբցիայով 34 հիվանդների բուժման վերլուծությունը և ատամների իմպլանտների պրոթեզավորումը իրականացվել է 2020-2023 թվականներին: Բոլոր հիվանդներն անցել են համալիր կլինիկական, լաբորատոր հետազոտություն, համակարգչային տոմոգրաֆիա (CT): Առաջին փուլում աուտոգեն ոսկրային փոխպատվաստման պրոցեդուրան, երկրորդում՝ աուտոգեն ոսկրային պատվաստման իմպլանտների տեղադրումից 4 ամիս անց: 3 ամիս անց, օրթոպեդիկ վերականգնման ժամկետները որոշելու համար իմպլանտների տեղադրումից հետո, կիրառվել է RFA-ռեզոնանսային հաճախականության վերլուծության մեթոդը, նորմալ արդյունքների գրանցման ղեպքում սկսվել է պրոթեզավորման փուլը: Պարբերաբար անցկացվել է հետվիրահատական կլինիկական և ռենտգենաբանական մոնիտորինգ, գնահատվել է իմպլանտացիայի հաջողությունը և իմպլանտի վրա հիմնված վերակառուցումների պրոթեզավորման հաջողությունը: Մարզինալ ոսկրային մակարդակի փոփոխությունը գնահատվել է վերականգնողական ֆիքսացիայից անմիջապես հետո թվային ռենտգենյան ճառագայթների միջոցով (համեմատության բազային գիծ), վիրահատությունից 1 և 3, 5 տարի հետո:

Արդյունքներ. Աուտոգեն ոսկրային փոխպատվաստումից հետո ներվիրահատական կամ անմիջական հետվիրահատական բարդություններ չեն արձանագրվել: Հիվանդների հետվիրահատական շրջանը բարենպաստ է եղել՝ ավտոփոխպատվաստների ինտեգրմամբ: Աուտոգեն ոսկրային փոխպատվաստումից 3 ամիս հետո որոշ ռեցիպիենտների մոտ փոխպատվաստման ռեզորբցիան հասնում է 10%-ի: Բոլոր հիվանդները ներկայացրել են առողջ փափուկ հյուսվածքներ: Արձանագրվել են սահմանային ոսկրային կորստի տվյալները, միջին սահմանային ոսկրային կորուստը (MBL) եղել է $1,2 \pm 0,25$ մմ 3 տարի հետո: Բոլոր 136 իմպլանտների միջին RFA ձայնագրությունները եղել են 65 ISQ իմպլանտների տեղադրման ժամանակ, համապատասխանաբար 73 ISQ 3 ամսից հետո: Իմպլանտների ֆունկցիոնալ ծանրաբեռնվածությունը կատարվել է 65-ից բարձր ISQ արժեքներով (ատամի պրոթեզային վերականգնումը կատարվել է ջրի տակ ապաքինումից 3-4 ամիս հետո): Ընդհանուր առմամբ գրանցվել է իմպլանտի 8 կորուստ: 5 տարի անց իմպլանտների գոյատևման մակարդակը 97,6%:

Եզրակացություններ. RFA-ն կարող է ծառայել որպես ոչ ինվազիվ ախտորոշիչ գործիք՝ ապաքինման փուլերում իմպլանտի կայունությունը հայտնաբերելու և հետագա բարդությունները կանխելու համար: Ռեզոնանսային-հաճախական վերլուծության մեթոդը թույլ է տալիս յուրաքանչյուր կոնկրետ ղեպքում որոշել պրոթեզավորման փուլի սկզբի ժամանակը:

ПРИМЕНЕНИЕ МЕТОДА ЧАСТОТНО-РЕЗОНАНСНОГО АНАЛИЗА ИМПЛАНТАТОВ,
УСТАНОВЛЕННЫХ ПОСЛЕ АУТОГЕННОЙ ТРАНСПЛАНТАЦИИ КОСТИ

Гагик Акопян,¹ Лазар Есяян,² Оганес Карапетян,³ Юрий Азбекян,⁴ Давит Матевосян⁵

- ¹ Профессор, заведующий кафедрой хирургической стоматологии и челюстно-лицевой хирургии, Ереванский государственный медицинский университет им. М. Гераци, Армения
- ² Профессор, заведующий кафедрой терапевтической стоматологии, Ереванский государственный медицинский университет им. М. Гераци, Армения
- ³ Стоматологический образовательный центр превосходства, Ереванский государственный медицинский университет им. М. Гераци, Армения
- ⁴ Студент Факультета стоматологии, Ереванский государственный медицинский университет им. М. Гераци, Армения
- ⁵ Преподаватель кафедры хирургической стоматологии челюстно-лицевой хирургии, Ереванский государственный медицинский университет им. М. Гераци, Армения

Абстракт

Цель исследования: Определить сроки протезной реабилитации пациентов после аутотрансплантата и дентальной имплантации кости челюсти с использованием резонансно-частотного метода.

Методы: Проведен анализ лечения 34 пациентов с вертикальной резорбцией нижних челюстей и дентальной имплантологической реставрацией, проведенной за период 2020-2023 гг. Всем пациентам проведено комплексное клинично-лабораторное исследование, компьютерная томография (КТ). На первом этапе проведена процедура аутогенной костной пластики, на втором этапе через 4 месяца после аутогенной костной пластики установлены имплантаты. Через 3 месяца после установки имплантатов для определения сроков ортопедической реабилитации применяли метод резонансно-частотного анализа, при регистрации нормальных результатов начинали этап протезирования. Регулярно проводился послеоперационный клинично-рентгенологический контроль, определялись критерии, оценивалась успешность имплантации и успешность протезирования реконструкций с опорой на имплантаты. Изменение уровня маргинальной кости оценивали с помощью цифровой рентгенографии сразу после фиксации реставрации (базовая линия для сравнения), через 1 и 3, 5 года после операции.

Результаты: После процедуры аутотрансплантации не было отмечено никаких интраоперационных или ближайших послеоперационных осложнений. Послеоперационный период у пациентов был благоприятный, с приживлением аутотрансплантатов. Через 3 мес после аутогенной костной пластики резорбция трансплантата у некоторых реципиентов трансплантата достигает 10%. У всех пациентов были здоровые мягкие ткани. Были записаны данные о потере маргинальной костной массы, средняя потеря маргинальной костной массы (MBL) составила $1,2 \pm 0,25$ мм через 3 года. Средний показатель RFA для всех 136 имплантатов составил 65 ISQ при установке имплантата и соответственно 73 ISQ через 3 месяца. Функциональную нагрузку на дентальные имплантаты осуществляли при значениях ISQ выше 65 (протезирование зубов осуществляли через 3-4 месяца погруженного приживления). Всего было зарегистрировано 8 отказов имплантата. Через 5 лет показатель выживаемости составляет 97,6%.

Выводы: Резонансно-частотный анализа может служить неинвазивным диагностическим инструментом для определения стабильности имплантата на этапах заживления и последующих плановых осмотрах. Метод резонансно-частотного анализа позволяет определить сроки начала ортопедического этапа в каждом конкретном случае.

DOI: 10.58240/1829006X-2023.19.4-59



Case Report

MAXILLOFACIAL REHABILITATION IN PATIENT WITH NEOPLASMS USING ZYGOMATIC IMPLANT-SUPPORTED PROSTHESES

Sergo Hovhannisyanyan PhD,^{1*} Karen Mashinyan PhD,¹ Levon Khachatryan PhD,² Edgar Karapetyan,³ Artavazd Kharazyan,⁴ Mikayel Ordoyan,⁵ Aram Badalyan⁶

¹ Associate professor, Department of Prosthodontics, Yerevan State Medical University after M. Heratsi, Yerevan, Armenia

² Maxillofacial surgeon, Head of Modern Implant Medicine, Yerevan, Armenia

³ Maxillofacial surgeon, Modern Implant, Yerevan, Armenia

⁴ Maxillo-facial prosthodontist, Anaplastologist, Clinical Anaplastology Service, National Medical Research Center of Otorhinolaryngology, Moscow, Russia

⁵ Lecturer, Department of Prosthodontics, Yerevan State Medical University after M. Heratsi, Yerevan, Armenia

⁶ Head of Head and Neck Surgery Service of "NAIRI" Medical Center, Yerevan, Armenia

* Corresponding author: *Sergo Hovhannisyanyan Associate professor, Department of Prosthodontics, Yerevan State Medical University after M. Heratsi, Yerevan, Armenia;*
e-mail: hovhansergo@gmail.com

Received: Oct. 2, 2023; **Accepted:** Oct. 27, 2023; **Published:** Nov. 5, 2023

Abstract

Objective: The aim of this study was to report the clinical results of the use of the zygomatic implants for prosthetic rehabilitation in patients with maxillectomy due to upper jaw tumors.

Materials and Methods: The study included 12 patients who underwent prosthetic rehabilitation using a zygomatic implant after maxillectomy for the treatment of upper jaw tumors in the period from 2021 to 2023. There were 8 male patients and 4 female patients with an average age of 53.2 years old. The type of tumors was determined by CT, MRT methods and histopathological examination. The distribution of lesions was the following: benign 4 and malignant 8.

7 patients have undergone radiation therapy before or after implant placement. After the tumor was removed, immediate surgical obturators were placed. Main prosthetic rehabilitation performed 6-12 months after tumor removal, but before that, a temporary obturator had made and used. 6-12 months after tumor resection, 1-4 zygomatic implants were inserted into the zygomatic bone unilaterally or bilaterally. A total of 36 zygomatic implants were installed, 2 of which were unsuccessful and were removed in 1 patient. The implant systems used Zygoma TiUnite (Nobel Biocare, Zurich, Switzerland) and multi-unit abutments (MUA). The implants were placed using the surgical guide, which was planned and prepared digitally. After which they loaded immediately using prefabricated complete dentures. They verified, adapted and screwed by titanium bases onto the zygomatic implants. The palatal part of these prostheses is a separate unit, which attach to the main part of the prostheses with magnets. By detaching the palatal part of the prostheses, through the created opening, doctor or patient can keep track of the upper tissues, hygiene and antiseptic cleansing (irrigation, rinsing). Evaluation of functional efficiency of the treatment was assessed before and after prosthetic rehabilitation with zygomatic implants using the Oral Health Impact Profile (OHIP-14) and the masticatory functional index. QOL was evaluated using the University of Washington Quality of Life version 4 (UW-QOLv4) questionnaire.

Results: No postsurgical complications were seen, and the patients were discharged from the hospital after 7-10 days. The patients were able to return to a normal diet (hard) after just 7 days following surgery, with no further complaints regarding function or pain, apart from the residual swelling caused by the intervention. Patients' health-related quality of life (HR-QOL) before treatment was $\geq 48.3\%$. HR-QOL and overall quality of life after rehabilitation increased to 76.8%, and assessed as good. The improvement of chewing function was also the most important goal for the patients (pre- 26,4% and post- 67,3%), masticatory function scores increased after prosthetic treatment with implants.

Conclusions: The use of prostheses fixed on zygomatic implants for patients with maxillary defects is an effective method of prosthodontic rehabilitation in complex clinical cases after maxillectomy.

Keywords: zygomatic implants, prosthetic rehabilitation, upper jaw tumors, maxillectomy.

Hovhannisyanyan S, Mashinyan K, Khachatryan L, et al. Maxillofacial Rehabilitation In Patient With Neoplasms Using Zygomatic Implant-Supported Maxillary Prostheses. *Bulletin of Stomatology and Maxillofacial Surgery*. 2023;19(4):59-71. doi: 10.58240/1829006X-2023.19.4-59

Introduction

Defects resulting from resection of the upper jaw, in malignant maxillofacial areas, often lead to loss of dentition, defects, sudden changes in the anatomical shape of the face and require radical surgical reconstruction and prosthetic rehabilitation.¹

In patients after maxillectomy for a malignant tumor, the resulting defect in the upper jaw often leads to serious dysfunction of the oral cavity leading to serious problems in mastication, swallowing, speech, and facial aesthetics.²

Prosthetic rehabilitation of patients after oncological resection of the upper jaw is a complex problem associated with the physiological and anatomical separation between the oral cavity and the nasal/paranasal region.³⁻⁵

In a number of clinical situations, rehabilitation was mainly carried out using a removable obturator prosthesis, which was effective.⁶ However, this decision was difficult due to clinical limitations when the resection affected most of the soft palate, more than a third of the hard palate and the upper jaw; it was technically difficult to fix the prostheses. Prosthetic rehabilitation of this category of patients using traditional fixation of dentures may be ineffective in restoring oral function. Due to insufficient bone tissue, the installation of conventional dental implants after resection of a malignant tumor of the upper jaw to fix prostheses is often difficult.⁷

Maxillectomy is not limited to tumor removal but also includes restoring the function of the oronasal cavity and facial contours, as failure to do so can lead to psychosocial and functional problems.

In patients who have undergone a complete or partial maxillectomy, the use of zygomatic implants is one of the main methods to help support obturators and/or removable dentures.⁸⁻¹⁰

Zygomatic implants provide a predictable solution for restoring dentition and facial structures affected by malignant diseases of the upper and midface. Combined use of dental and zygomatic implants may help restore oral function in patients with severe maxillary defects.¹¹⁻¹³

The concept of using zygomatic implants has been introduced since the present time; this technique is used both separately and in combination, and in combination with microvascular transfer of free tissue

in prosthetics and prosthodontic treatment of cancer patients. Over the past 10 years, zygomatic implants have become an integral part in the treatment of patients with neoplasms of various etiologies of the upper jaw and midface that require radical resection to achieve cure.^{14,15}

Zygomatic implants are an effective solution for the treatment of jaw bone defects of the upper jaw after maxillectomy. Zygomatic implants have been used since the late 1980s and have a long history of success.

First proposed by Branemark et al. In 1998, zygomatic implants were intended for the rehabilitation of patients with severe atrophy of the posterior maxilla, partially and completely edentulous, in patients with maxillectomy.¹⁶

Zygomatic implants have been used for dental rehabilitation in patients with insufficient bone tissue in the posterior maxilla due to severe bone resorption (atrophy), after resection of tumors and extensive trauma to the midface.¹⁷ Zygomatic is an alternative to bone grafting procedures for severe atrophy in the upper jaw and consists of dental implants that are fixed in the lower part of the cheekbones through the sinuses. These implants are inserted at the back and can be combined with several conventional implants (root forms) at the front of the jaw.¹⁸⁻²⁰

The zygomatic bone has joints with the sphenoid bone, superior bone, frontal bone and temporal bone, forms the lateral wall of the orbital floor and, characterized by trabecular and cortical components, is a reliable bed for zygomatic implants.²¹

Zygomatic implants are installed in different ways: bilateral two implants, bilateral with one implant, unilateral with one or two implants and in combination with conventional dental implants.²²

With zygomatic implants, the post-implantation period is associated with less severe morbidity compared to bone grafting options and an increase in the overall duration of treatment.

Over the past period, zygomatic implants have demonstrated a scientifically based surgical and prosthetic solution with their widespread use in various clinical situations in procedures for treatment of severe maxillary atrophy, alternatives to failed cases of traditional implants, in cases trauma and oral cancer rehabilitation upper jaw.

Many literature publications report varying success rates from 98.5% to 96.1% after more than 5 years, so the overall effectiveness and predictability of such rehabilitation is still a matter of debate. The most common complications were soft tissue dehiscence, rhinosinusitis, and prosthetic failure.²³

The effectiveness of zygomatic implants has been enhanced by the use of digital technologies (virtual planning based on computed tomography with the creation of individual surgical templates), which allows the final dental prostheses to be precisely created with maximum precision and in the safest possible conditions.²⁴

Effective use of dentures supported by zygomatic implants and dental implants can provide complete functional and aesthetic rehabilitation in patients with post-resection severe defects of the upper jaw.²⁵⁻²⁸

Treatment of patients with cancer of the upper maxilla and hard palate is a difficult task for specialists, and untimely prosthetic rehabilitation leads to significant functional and aesthetic consequences. Considering the relevance of this problem, in this clinical series we show the effectiveness of an interdisciplinary approach in the complex rehabilitation of patients in this category.

In patients undergoing maxillectomy, quality of life involves reconstruction of the maxilla and restoration of the function of the orofacial cavity and facial contours, since orofacial deformities can lead to severe psychological and social consequences²⁹. Changes in anatomy after maxillectomy lead to functional and cosmetic impairments, which can lead to reduction in quality of life (QoL).^{30,31}

The aim of the present study was to report the clinical results of the use of zygomatic implants for prosthetic rehabilitation in patients with maxillectomy for tumors of the maxilla.

Material and Methods

During the period from 2021 to 2023, 12 patients took part in this study and underwent prosthetic rehabilitation using a zygomatic implant after maxillectomy for the treatment of upper jaw tumors. In order to clarify the diagnosis and later plan and choose a surgical method, a complex of diagnostic methods performed.

The type of tumors was determined by CT, MRT methods and histopathological examination.

Out of 12 patients there were 8 male and 4 female with an average age of 53.2 years. Test results clarified the tumor types: 4 benign (ameloblastoma 2, osteoblastoclastoma 2) and 8 malignant (mainly minor salivary gland tumors 2, adenoid cystic carcinoma 2, cancer of the mucous membrane 4).

Surgical defect classified using Brown classification of maxillectomy.³²

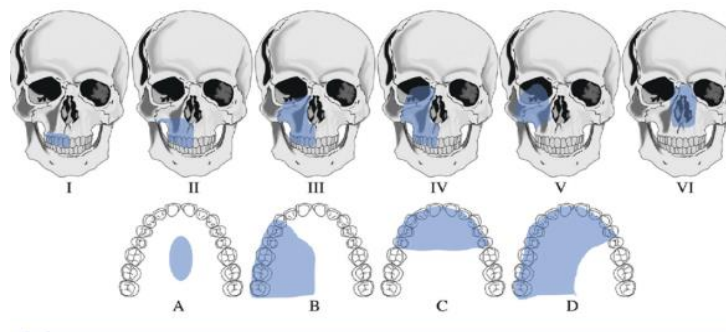
Surgical defect classified according to vertical dimension of the maxillectomy, class 1–4.

Class 1: no oro-nasal or oro-antral fistula or only resection of palatal bone leaving dental-bearing part of maxilla intact.

Class 2: not including orbital floor or rim.

Class 3: including orbital floor with or without skull base.

Class 4: orbital exenteration. Class 2–4 is qualified by addition of a letter (a–c) which refers to the horizontal aspect: a, less than or equal to the midline of the hard palate; b, bilateral alveolar maxilla and hard palate; c, entire alveolar maxilla and hard palate (figure 1).



Brown and Shaw Maxilla and Midface Defect Classification

The patients were operated under general anesthesia. Some underwent either partial or total maxillectomy, others needed procedures that extending beyond the maxilla. Hemimaxillectomy was the most common surgical procedure. 7 patients received radiation therapy before or after maxillectomy.

After the tumor was removed, immediate surgical obturators were placed. Main prosthetic rehabilitation performed 6-12 months after tumor removal, but before that, a temporary obturator had made and used. 6-12 months after tumor resection, 1-4 zygomatic implants were inserted into the zygomatic bone unilaterally or bilaterally. A total of 36 zygomatic implants were installed, 2 of which were unsuccessful and were removed in 1 patient. The implant systems used Zygoma TiUnite (Nobel Biocare, Zurich, Switzerland) and multi-unit abutments (MUA). The implants were placed using the surgical guide, which was planned and prepared digitally. After which they loaded immediately using prefabricated complete dentures. They verified, adapted and screwed by titanium bases onto the zygomatic implants. The palatal part of these prostheses is a separate unit, which attach to the main part of the prostheses with magnets. By detaching the palatal part of the prostheses, through the created opening, doctor or patient can keep track of the upper tissues, hygiene and antiseptic cleansing (irrigation, rinsing).

This case report describes the management of patients with severe maxillary defects following ablative cancer surgery who were rehabilitated with maxillary removable dentures supported by 3 zygomatic implants and magnetic fixation.

Case report

On 05/14/2023 64 years old male patient AA, was admitted to the clinic with a diagnosis of a condition after a maxillectomy of the left side. From the anamnesis it turned out that on 03/30/2015 a maxillectomy of the left side was performed for cancer of the left maxillary sinus mucous membrane (T4N0M0). The patient received preoperative and postoperative radiation therapy.

At the time of admission, the general condition was stable, a defect in the oral cavity in the area of the left half of the upper jaw was detected, the mucous membrane was normal without visible changes. The patient was wearing a removable denture.

Completed general laboratory research showcased that laboratory parameters were normal, according to CT the condition after maxillectomy of the left side, complete adentia, bone absorption. It was planned to install 2 zygomatic implants on the left side, 1 on the right and immediate rehabilitation with complete dentures, which immediately would be connected to the multiunit abutments of the zygomatic implant. After 6 months final prostheses were placed. Treatment plan was agreed with the patient beforehand. The installation of the zygomatic implant was carried out under general anesthesia according to the plan and after the operation a temporary prosthesis was installed and screwed on implants. After 6 months the final rehabilitation was carried out with a removable prosthesis connecting to the multi-unit abutment of the zygomatic implant. In the palatal part of the removable prostheses a movable window was formed for hygiene: this movable part of the plate was fixed to the main fixed part of the denture with magnets. After rehabilitation, the patient was satisfied with the results of the treatment, chewing functions were restored and the quality of life improved (figures 2-18).

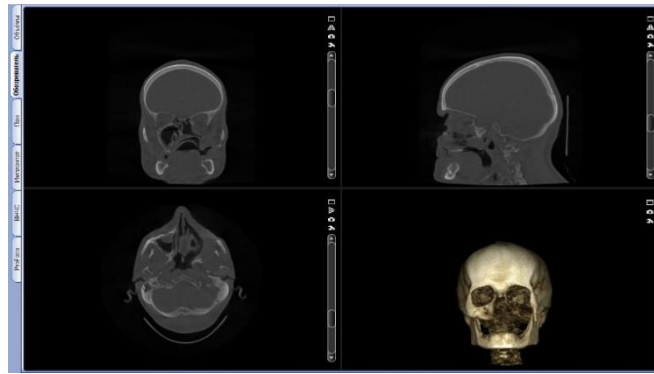


Figure 1. Condition 8 years after maxillectomy of the left side

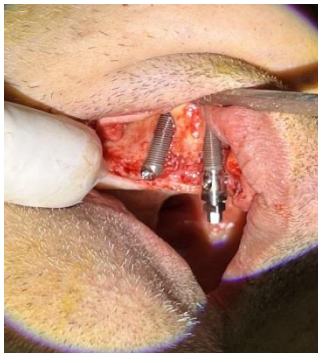

Figure 3. 8 years after tumor resection, 2 zygomatic implants into the right zygomatic bone

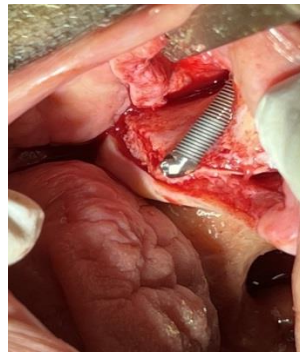


Figure 4. 1 zygomatic implant into the left zygomatic bone

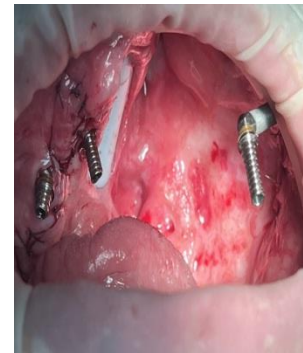


Figure 5. Condition after installation of implants and multi-unit abutments

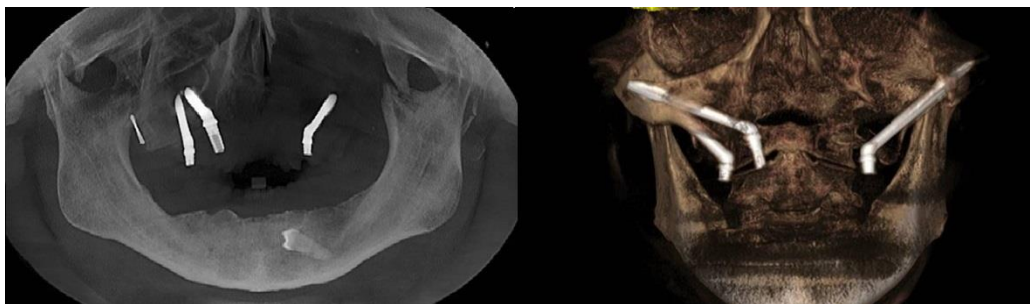

Figure 6, 7. Postoperative CT after installation of 2 zygomatic implants on the right side and 1 on the left side and connection of multi-unit abutments



Figure 8. After 6 months an impression was taken for final rehabilitation

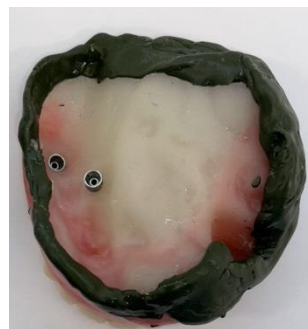

Figure 9. An individual tray was made in the laboratory




Figure 10. Impression was taken using an individual tray

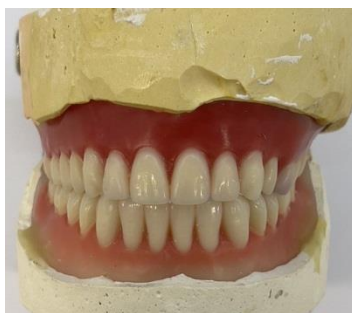
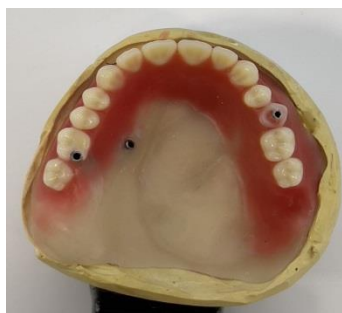
Figure 11, 12. A temporary seminal prosthesis was made in the laboratory

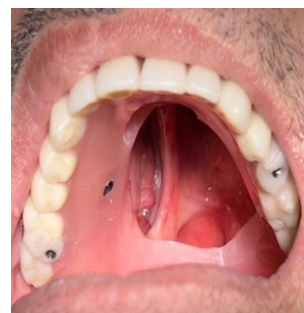

Figure 13. Intraoral view with the prosthesis in place

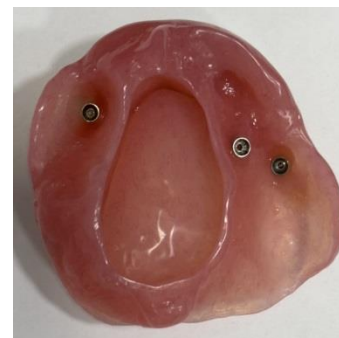
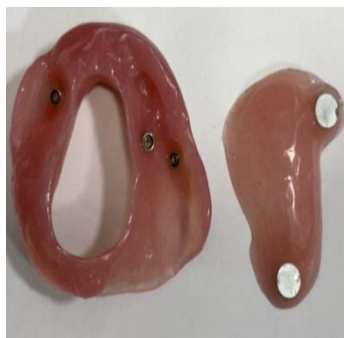
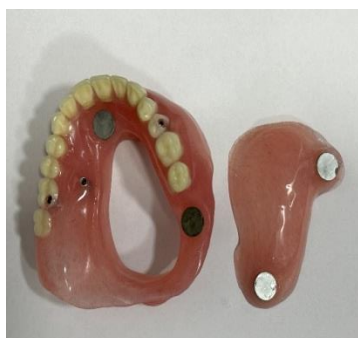Figure 13, 14, 15. The final prosthetics. In the new part of the removable prostheses a movable window was formed for hygiene

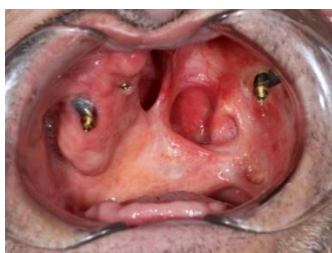

Figure 16. Intraoral state before prosthetics

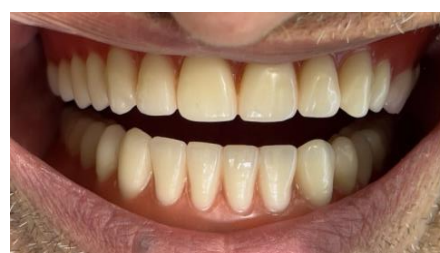

Figure 17. Intraoral view after prosthetics

Evaluation of functional effectiveness of the treatment was assessed before and after prosthetic rehabilitation with zygomatic implants using the Oral Health Impact Profile (OHIP-14) and the masticatory functional index. QOL was evaluated using the University of Washington Quality of Life version 4 (UW-QOLv4) questionnaire. The entire Quality of Life Assessment questionnaire consists of 12 domains, questions, each of which has from 3 to 6 answer options, which are scaled from 0 (worst) to 100 (best) in accordance with the hierarchy of answers. Domains: pain, appearance, activity, rest, swallowing, chewing, speech, taste, saliva, mood and anxiety. Quality of life scores were divided into satisfactory (60 points), good (80 points) and very good (100

points)³³. Data was analyzed using statistics. Masticatory function was assessed using the Masticatory Function Score Sheet.

Results

A total of 36 zygomatic implants were installed, 2 of which were unsuccessful and were removed in 1 patient.

No post-operative complications were reported and the patients were discharged from the hospital after 10 days. The patients were able to return to a normal diet (solid) after just 7 days from surgery, with no further complaints regarding function or pain, apart from the residual swelling caused by the intervention.

Prosthetic rehabilitation began after tumor removal and an immediate temporary obturator was made.

Patients' health-related quality of life (HR-QOL) before treatment was $\geq 48.3\%$. HR-QOL and overall quality of life after rehabilitation was rated good by 76.8%, respectively. In all cases chewing was also the most important function for the patients, (pre implantation 26,4% and post 67,3%) masticatory function scores increased after prosthodontics treatment with implants.

Evaluation on OHIP-14 and functional chewing score

Questionnaire	OHIP-14		Functional chewing score	
	Pre	Post	Pre	Post
Patients 12	$\geq 48.3\%$	76.87%	26.4%	67.3%

Discussion

The treatment complex for neoplasms includes maxillectomy - surgical removal of part or all of the upper jaw, it results in a defect that can significantly affect a person's function, aesthetics, and quality of life.³⁴

Malignant neoplasms account for almost half of the pathologies that are indications for resection of the maxilla. Maxillectomy for malignancy often results in a maxillary defect and severe oral dysfunction.

In patients who have undergone a complete or partial maxillectomy, the use of zygomatic implants is one of the main methods to help support obturators and/or removable dentures.^{35,36}

There is no clear consensus in the scientific literature on the number of dental and zygomatic implants required for prosthetic rehabilitation of the maxilla in patients with post-resection defects of the maxilla supported by implants. Some authors recommend using 2-4 zygomatic implants or a combination of two dental implants and 2 zygomatic implants for functional and aesthetic rehabilitation in patients after maxillectomy.³⁷ Sato et al reported that the mean scores of complete denture wearers were: “satisfied” was 58.7, “somewhat satisfied” was 48.5,

and “not satisfied” was 32.4. These assessments provide a ready explanation that the assessment of masticatory function is closely related to chewing satisfaction.³⁸

In patients with a resection maxillary defect, the load on the prostheses and transfer to the implant may increase during occlusion compared to traditional implant-supported dentures without a maxillary defect. For the prostheses, a favorable position and angle of installation of the implant are important. It is expected that rigid retention between the prostheses and the implant may increase the risk of prosthetic complications, including fracture of the prostheses, abutment and implant. Based on this, the use of magnetic can be optimal since with this type of fastening they resist only vertical force and do not resist lateral force, which is low compared to lateral force.

The use of computer-aided design/computer-aided manufacturing (CAD/CAM) technologies can help in the prosthodontics rehabilitation of patients with post-resection oncological defects of the maxilla.³⁹

Maxillectomy for malignancy often results in a maxillary defect and severe oral dysfunction. The effective use of dental and zygomatic implants can help restore oral function in patients with severe maxillary defects.

The risk of prosthodontics complications, including fracture of the prostheses, abutment and implant, can be increased during rehabilitation using removable dentures on implants due to rigid retention between the prostheses and the implant.

For removable dentures on implants, various fastening systems (telescopic crowns, rods, locators, balls and magnets) are successfully used.⁴⁰ Since magnetic mounts only resist vertical force and do not resist lateral force, retention is considered to be low relative to lateral force compared to other mounts. Consequently, the abutment and implant body appear to be protected better.

This case report describes the management of 12 patients with severe maxillary defects following ablative surgery for cancer who were rehabilitated

using fixed maxillary prostheses supported by dental and zygomatic implants. In our clinical case, a magnetic fastening system was preferred to keep track of the upper tissues, hygiene and antiseptic cleansing. Prosthetic rehabilitation was carried out using removable dentures supported by 1 or 3 implants and screw fixation. Oral function was assessed before and after implant prosthetics using the Oral Health Impact Profile (OHIP-14) and the Masticatory Functional Index. These results indicate that quality of life (QoL) and oral function improved. The results showed improvement in all cases. This approach will provide a number of advantages. First, in many cases, additional maxillary reconstruction procedures will not be required. Secondly, the installation of implants and the manufacture of prostheses become easier. Finally, the time required for surgery is reduced, and the reduced number of implants reduces cost. The effective use of dental and zygomatic implants can help restore oral function in patients with severe maxillary defects. The prognosis for this treatment was acceptable.

Declarations

Conflict of interest and financial disclosure

The author declares that he has no conflict of interest and there was no external source of funding for the present study. None of the authors have any relevant financial relationship(s) with a commercial interest.

Ethical approval

Research protocol was approved by the local Ethical Committee (2018/23) and in accordance with those of the World Medical Association and the Helsinki Declaration.

Informed consent

Informed consent was obtained from all individual participants included in the study.

Source of Funding

Non funding.

Availability of Data and Materials

Not applicable.

REFERENCES

1. Volpato M, Costa GM, dos S Lara L, Volpato LER. Maxillofacial and Oral Rehabilitation of an Oncologic Patient: Case Report. *International Journal of Prosthodontics & Restorative Dentistry*. 2022;12(3):1-3
2. Geethu RM, Anilkumar S, Rajesh C, et al. Prosthetic rehabilitation of a lateral midfacial defect combined with hemimandibulectomy using multiple/sectional prosthesis. *Int J Prosthodont Restor Dent*. 2014;4(4):131–137. doi:10.5005/jp-journals-10019-1120
3. Kumar Y, Bharate V, Babu D, et al. Prosthetic rehabilitation of continuous maxillary and orbital defect. *Int J Prosthodont Restor Dent*. 2017;7(2):77–80. doi:10.5005/jp-journals-10019-1181
4. Nayar S. Current concepts and novel techniques in the prosthodontic management of head and neck cancer patients. *British Dental Journal*. 2019;226(10):725–737. doi:10.1038/s41415-019-0318-3
5. Vosselman N, Alberga J, Witjes MHJ, et al. Prosthodontic rehabilitation of head and neck cancer patients-Challenges and new developments. *Oral Dis*. 2021;27(1):64-72. doi:10.1111/odi.13374
6. Corsalini M, Barile G, Catapano S, et al. Obturator Prosthesis Rehabilitation after Maxillectomy: Functional and Aesthetical Analysis in 25 Patients. *Int J Environ Res Public Health*. 2021;18(23):12524. doi:10.3390/ijerph182312524

7. El Fattah H, Zaghloul A, Pedemonte E, Escuin T. Pre-prosthetic surgical alterations in maxillectomy to enhance the prosthetic prognoses as part of rehabilitation of oral cancer patient. *Med Oral Patol Oral Cir Bucal*. 2012;17(2):262-70. doi:10.4317/medoral.17482
8. Rosenstein J, Dym H. Zygomatic Implants: A Solution for the Atrophic Maxilla: 2021 Update. *Dent. Clin. N. Am.* 2021;65:229–239. doi:10.1016/j.cden.2020.09.015
9. Varghese KG, Gandhi N, Kurian N, et al. Rehabilitation of the severely resorbed maxilla by using quad zygomatic implant-supported prostheses: A systematic review and meta-analysis. *J. Prosthet. Dent.* 2023;130(4):543-552. doi:10.1016/j.prosdent.2021.11.007
10. Andre A, Dym H. Zygomatic Implants: A Review of a Treatment Alternative for the Severely Atrophic Maxilla. *Atlas. Oral Maxillofac. Surg. Clin. N. Am.* 2021;29(2):163-172. doi:10.1016/j.cxom.2021.04.001
11. Aparicio C, Manresa C, Francisco K, et al. Zygomatic implants: indications, techniques and outcomes, and the zygomatic success code. *Periodontol 2000*. 2014;66(1):41-58. doi:10.1111/prd.12038
12. Di Cosola M, Ballini A, Zhurakivska K, et al. Retrospective Analysis of Clinical and Radiologic Data Regarding Zygomatic Implant Rehabilitation with a Long-Term Follow-Up. *Int. J. Environ. Res. Public Health*. 2021;18(24):12963. doi:10.3390/ijerph182412963
13. Aparicio C, Manresa C, Francisco K, et al. Zygomatic implants: indications, techniques and outcomes, and the zygomatic success code. *Periodontol 2000*. 2014;66(1):41-58. doi:10.1111/prd.12038
14. Di Cosola M, Ballini A, Zhurakivska K, et al. Retrospective Analysis of Clinical and Radiologic Data Regarding Zygomatic Implant Rehabilitation with a Long-Term Follow-Up. *Int. J. Environ. Res. Public Health*. 2021;18(24):12963. doi:10.3390/ijerph182412963
15. Hackett S, El-Wazani B, Butterworth C. Zygomatic implant-based rehabilitation for patients with maxillary and mid-facial oncology defects: A review. *Oral Dis*. 2021;27(1):27-41. doi:10.1111/odi.13305
16. Brånemark P, Gröndahl K, Öhrnell L, et al. Zygoma Fixture in the Management of Advanced Atrophy of the Maxilla: Technique and Long-Term Results. *Scand. J. Plast. Reconstr. Surg. Hand Surg.* 2004;38:70–85. doi:10.1080/02844310310023918
17. Solà Pérez A, Pastorino D, Aparicio C, Pegueroles Neyra M, Khan RS, Wright S. Success Rates of Zygomatic Implants for the Rehabilitation of Severely Atrophic Maxilla: A Systematic Review. *Dent. J.* 2022;10(8):151. doi:10.3390/dj10080151
18. Chana H, Smith G, Bansal H, et al. A Retrospective Cohort Study of the Survival Rate of 88 Zygomatic Implants Placed Over an 18-Year Period. *Int. J. Oral Maxillofac. Implant.* 2019;34:461–470. doi:10.11607/jomi.6790
19. Balan I, Di Girolamo M, Lauritano D, Carinci F. Treatment of severe atrophic maxilla with zygomatic implants: A case series. *Oral Implantol.* 2017;10:317–324. doi:10.11138/orl/2017.10.3.317
20. Esposito M, Davó R, Marti-Pages C, et al. Immediately Loaded Zygomatic Implants vs Conventional Dental Implants in Augmented Atrophic Maxillae: 4 Months Post-Loading Results from a Multicentre Randomised Controlled Trial. *Eur. J. Oral Implantol.* 2018;11:11–28.
21. Bedrossian E. Rehabilitation of the edentulous maxilla with the zygoma concept: A 7-year prospective study. *Int. J. Oral Maxillofac. Implant.* 2010;25:1213–1221.
22. Chana H, Smith G, Bansal H, et al. A Retrospective Cohort Study of the Survival Rate of 88 Zygomatic Implants Placed Over an 18-Year

- Period. *Int. J. Oral Maxillofac. Implant.* 2019;34:461–470. doi:10.11607/jomi.6790
23. Solà Pérez A, Pastorino D, Aparicio C, et al. Success Rates of Zygomatic Implants for the Rehabilitation of Severely Atrophic Maxilla: A Systematic Review. *Dent J (Basel)*. 2022;10(8):151. doi: 0.3390/dj10080151
24. Hackett S, El-Wazani B, Butterworth C. Zygomatic implant-based rehabilitation for patients with maxillary and mid-facial oncology defects: A review. *Oral Dis*. 2021;27(1):27-41. doi:10.1111/odi.13305
25. Boyes-Varley JG, Howes DG, Davidge-Pitts KD, Brånemark I, McAlpine JA. A protocol for maxillary reconstruction following oncology resection using zygomatic implants. *Int J Prosthodont*. 2007;20(5):521–31
26. Hu YJ, Hardianto A, Li SY, Zhang ZY, Zhang CP. Reconstruction of a palatomaxillary defect with vascularized iliac bone combined with a superficial inferior epigastric artery flap and zygomatic implants as anchorage. *International Journal of Oral and Maxillofacial Surgery*. 2007;36(9):854–857. doi:10.1016/j.ijom.2007.04.011
27. Ozaki H, Sakurai H, Yoshida Y, Yamanouchi H, Iino M. Oral Rehabilitation of Oral Cancer Patients Using Zygomatic Implant-Supported Maxillary Prosthesis with Magnetic Attachment: Three Case Reports. *Case Rep Dent*. 2018;2018:1694063. doi:10.1155/2018/1694063
28. Ozaki H, Ishikawa S, Kitabatake K, Yusa K, Sakurai H, Iino M. Functional and aesthetic rehabilitation with maxillary prosthesis supported by two zygomatic implants for maxillary defect resulting from cancer ablative surgery: A case report/technique article. *Odontology*. 2016;104(2):233–238. doi:10.1007/s10266-015-0222-5
29. Slade GD. Derivation and validation of a short-form oral health impact profile. *Community Dentistry and Oral Epidemiology*. 1997;25(4):284–290. doi:10.1111/j.1600-0528.1997.tb00941.x
30. Akinmoladun VI, Akinyamoju CA, Olaniran FO, Olaopa OI. Maxillectomy and Quality of Life: Experience from a Nigerian Tertiary Institution. *Niger J Surg*. 2018;24(2):125-130. doi:10.4103/njs.NJS_6_18
31. Laraway DC, Lakshmiah R, Lowe D, Roe B, Rogers SN. Quality of life in older people with oral cancer. *Br J Oral Maxillofac Surg*. 2012;50(8):715-20. doi:10.1016/j.bjoms.2012.01.010
32. Brown JS, Rogers SN, McNally DN, Boyle M. A modified classification for the maxillectomy defect. *Head & Neck*. 2000;22(1):17–26. doi:10.1002/(sici)1097-0347(200001)22:1<17::aid-hed4>3.0.co;2-2
33. The World Health Organization quality of life assessment (WHOQOL): Position paper from the World Health Organization. *Soc Sci Med*. 1995;41(10):1403-9. doi:10.1016/0277-9536(95)00112-k
34. Between 2021 and 2023, 24 patients with maxillary defects following resection of malignant tumor were recruited
35. Polido WD, Machado-Fernandez A, Lin WS, et al. Indications for zygomatic implants: a systematic review. *Int J Implant Dent*. 2023;9:17. doi:10.1186/s40729-023-00480-4
36. Singh A, Kumar N, Singh V, Singh SK. Transitional prosthesis for a dentulous hemimaxillectomy patient. *Natl J Maxillofac Surg*. 2010;1:173–5. doi:10.4103/0975-5950.79224
37. Ozaki H, Ishikawa S, Kitabatake K, Yusa K, Sakurai H, Iino M. Functional and aesthetic rehabilitation with maxillary prosthesis supported by two zygomatic implants for maxillary defect resulting from cancer ablative surgery: A case report/technique article. *Odontology*. 2016;104(2):233–238. doi:10.1007/s10266-015-0222-5

38. Sato Y, Minagi S, Akagawa Y, Nagasawa T. An evaluation of chewing function of complete denture wearers. *The Journal of Prosthetic Dentistry*. 1989;62(1):50–53. doi:10.1016/0022-3913(89)90047-4
39. Schmidt BL, Pogrel MA, Young CW, Sharma A. Reconstruction of extensive maxillary defects using zygomatic implants. *Journal of Oral and Maxillofacial Surgery*. 2004;62(2):82–89. doi:10.1016/j.joms.2004.06.027
40. Savabi O, Nejatidanesh F, Yordshahian F. Retention of implant-supported overdenture with bar/clip and stud attachment designs. *The Journal of Oral Implantology*. 2013;39(2):140–147. doi:10.1563/AAID-JOI-D-11-00016

ՎԵՐԻՆ ԾՆՈՏԻ ՆՈՐԱԳՈՅԱՑՈՒԹՅՈՒՆՆԵՐՈՎ ՀԻՎԱՆԳՆԵՐԻ ԴԻՄԱԾՆՈՏԱՅԻՆ ՎԵՐԱԿԱՆԳՆՈՒԲԱՆ ԶԻԳՈՄԱՏԻԿ ԻՄՊԼԱՆՏՆԵՐԻ ՎՐԱ ՀԵՆՎՈՂ ՊՐՈԹԵԶՆԵՐԻ ՄԻՋՈՑՈՎ

Սերգո Հովհաննիսյան,¹ Կարեն Մաշինյան,¹ Լևոն Խաչատրյան,² Էդգար Կարապետյան,³ Արտավազ Խարազյան,⁴ Միքայել Օրդոյան,⁵ Արամ Բաղայան⁶

- ¹ Երևանի Մ. Հերացու անվան պետական բժշկական համալսարանի Օրթոպեդիկ ստոմատոլոգիայի ամբիոնի դոցենտ, Երևան, Հայաստան
- ² Modern Implant Medicine-ի ղեկավար (Դիմաձևոտային և պլաստիկ վիրաբուժության բժշկական կենտրոն), Երևան, Հայաստան
- ³ Modern Implant Medicine-ի Դիմաձևոտային վիրաբույժ (Դիմաձևոտային և և պլաստիկ վիրաբուժության բժշկական կենտրոն), Երևան, Հայաստան
- ⁴ Դիմաձևոտային պրոթեզաբան, անապլաստոլոգ. Կլինիկական անապլաստոլոգիայի ծառայություն, Օտորինոլարինգոլոգիայի ազգային բժշկական գիտահետազոտական կենտրոն, Մոսկվա, Ռուսաստան
- ⁵ Երևանի Մ. Հերացու անվան պետական բժշկական համալսարանի Օրթոպեդիկ ստոմատոլոգիայի ամբիոնի դասախոս, Երևան, Հայաստան
- ⁶ «ՆԱԻՐԻ» բժշկական կենտրոնի գլխի և պարանոցի վիրաբուժության ծառայության ղեկավար, Երևան, Հայաստան

Ամփոփում

Նպատակը. Այս հետազոտության նպատակն էր վերին ծնոտի ուռուցքների պատճառով վիրահատված հիվանդների մոտ գնահատել զիգոմատիկ իմպլանտների օգտագործմամբ օրթոպեդիկ վերականգնման կլինիկական արդյունքները:

Նյութեր և մեթոդներ. Հետազոտությունը ներառում էր վերին ծնոտի ուռուցքներով 12 հիվանդներ, ովքեր 2021-ից 2023 թվականներին ուռուցքների վիրահատական բուժումից հետո ենթարկվել էին պրոթեզային վերականգնման՝ օգտագործելով զիգոմատիկ իմպլանտներ: Նրանց թվում են եղել 8 տղամարդ և 4 կին հիվանդներ, միջին տարիքը՝ 53.2 տարեկան: Ուռուցքների տեսակը որոշվել է CT, MRI և հիստոպաթոլոգիական հետազոտությամբ: Նորագոյացությունների բաշխվածությունը եղել է բարորակ՝ 4-ում, չարորակ՝ 8-ում: Ուռուցքի հեռացումից առաջ և հետո 7 հիվանդ ստացել է ճառագայթային թերապիա: Ուռուցքի հեռացումից անմիջապես հետո տեղադրվել են վիրաբուժական անհապաղ օբտուրատորներ: Վերքերի ապաքինումից հետո, ուռուցքի հեռացումից 6-12 ամիս հետո մեկ կամ երկու այտուցներում տեղադրվել են 1-4 զիգոմատիկ իմպլանտներ: Ընդհանուր առմամբ տեղադրվել է 36 զիգոմատիկ իմպլանտ, որից 2-ը անհաջող են եղել և հեռացվել են 1 հիվանդի մոտ: Օգտագործվել են Zygoma TiUnite (Nobel Biocare, Յյուրիխ, Շվեյցարիա) իմպլանտներ և Multi-unit (MUA) արաթմենտներ: Իմպլանտները տեղադրվել են

թվային եղանակով պլանավորված և պատրաստված վիրաբուժական ուղղորդիչի միջոցով: Այտույններում իմպլանտների տեղադրումից հետո նրանք անմիջապես ծանրաբեռնվել են նախորոք պատրաստված թիթեղային ժամանակավոր պրոթեզներով, որոնք փորձարկումից և հարմարեցումից հետո ժամանակավոր պտուտակվել են զիգոմատիկ իմպլանտներին տիտանային հենքով: 6 ամիս հետո տեղադրվել են իմպլանտների վրա հենվող վերջնական պրոթեզները: Այս պրոթեզների քմային հատվածը իրենից ներկայացնում է առանձին միավոր և մագնիսների միջոցով միանում է պտուտակներով իմպլանտներին ամրացված պրոթեզի հիմնական մասին: Պրոթեզի քմային հատվածի անջատման միջոցով առաջացած անցքով իրականացվում է վերադիր հատվածների հյուսվածքների դիտարկում, խնամք, անտիսեպտիկ մշակում և հիգիենային ուղղված գործառնություններ (իրիգացիաներ, ողողում):

Բուժման ֆունկցիոնալ արդյունավետությունը գնահատվել է զիգոմատիկ իմպլանտների կիրառմամբ պրոթեզավորումից առաջ և հետո՝ օգտագործելով բերանի խոռոչի առողջության վրա ազդեցության պրոֆիլը (OHIP-14) և ծամողական ֆունկցիոնալ ինդեքսը: Կյանքի որակը գնահատվել է Վաշինգտոնի համալսարանի կյանքի որակի հարցաշարի 4-րդ տարբերակով (UW-QOLv4):

Արդյունքներ. Հետվիրահատական բարդություններ չեն եղել, և 7-10 օր հետո հիվանդները դուրս են գրվել հիվանդանոցից: Վիրահատությունից ընդամենը 7 օր հետո հիվանդները կարողացել են վերադառնալ նորմալ սննդակարգի (սինդ)՝ առանց որևէ ֆունկցիոնալ կամ ցավային զանգատների, բացի վիրահատության հետևանքով առաջացած մնացորդային այտուցից: Հիվանդների առողջության հետ կապված կյանքի որակը (HR-QOL) մինչև բուժումը $\geq 48.3\%$ էր: HR-QOL-ը և վերականգնումից հետո կյանքի ընդհանուր որակը գնահատվել են որպես լավ համապատասխանաբար 76.8%-ով: Բոլոր դեպքերում, ծամելու ֆունկցիայի բարելավումը, նաև բուժառուների համար, ամենակարևոր նպատակն էր (մինչև իմպլանտացիան 26,4% և հետո 67,3%): Ծամելու ֆունկցիայի ցուցանիշներն աճել են իմպլանտներով օրթոպեդիկ բուժումից հետո:

Եզրակացություններ. Զիգոմատիկ իմպլանտների վրա ֆիքսված պրոթեզի օգտագործումը դիմաձնոտային արատներով հիվանդների մոտ օրթոպեդիկ վերականգնման արդյունավետ մեթոդ է դիմաձնոտային վիրահատությունից հետո բարդ կլինիկական դեպքերում:

ЧЕЛЮСТНО-ЛИЦЕВАЯ РЕАБИЛИТАЦИЯ БОЛЬНЫХ С НОВООБРАЗОВАНИЯМИ ВЕРХНЕЙ ЧЕЛЮСТИ С ИСПОЛЬЗОВАНИЕМ ПРОТЕЗОВ НА СКУЛОВЫХ ИМПЛАНТАТАХ

Серго Оганесян,¹ Карен Машинян,¹ Левон Хачатрян,² Эдгар Карапетян,³ Артавазд Харазян,⁴ Микаел Ордоян,⁵ Арам Бадалян⁶

¹ Доцент кафедры Ортопедической стоматологии Ереванского государственного медицинского университета им. М. Гераци, Ереван, Армения

² Челюстно-лицевой хирург, руководитель Медицинского центра МИМ, Ереван, Армения

³ Челюстно-лицевой хирург Медицинского центра МИМ, Ереван, Армения

⁴ Челюстно-лицевой стоматолог-ортопед, анапластолог, Служба клинической анапластологии, Национальный медицинский исследовательский центр оториноларингологии, Москва, Россия

⁵ Преподаватель кафедры Ортопедической стоматологии Ереванского государственного медицинского университета им. М. Гераци, Ереван, Армения

⁶ Руководитель службы хирургии головы и шеи медицинского центра «НАИРИ», г. Ереван, Армения

Резюме

Цель: Целью настоящего исследования было оценить клинические результаты ортопедической реабилитации пациентов с использованием скуловых имплантатов, перенесших челюстно-лицевую операцию по поводу опухолей верхней челюсти.

Методы и материалы: В исследование включены 12 пациентов, проходивших протезную реабилитацию с использованием скуловых имплантатов после челюстно-лицевой операции по поводу опухолей верхней челюсти в период с 2021 по 2023 годы. Среди них было 8 пациентов мужского пола и 4 пациентки женского пола, средний возраст 53,2 года. Тип опухолей определялся методами КТ, МРТ и гистопатологического исследования. Распределение образований доброкачественное - у 4 пациентов, злокачественное - у 8 пациентов. 7 пациентов получали лучевую терапию до или после удаления опухоли. Сразу после удаления опухоли были поставлены хирургические имедиат obturаторы. После заживления ран, от 6-и до 12-и месяцев после резекции опухоли в односторонние или двусторонние скуловые кости устанавливали 1-4 скуловых имплантата. Всего установлено 36 скуловых имплантатов, из них 2 оказались неудачными и были удалены у 1 пациента. Использовались Zygoma TiUnite (Nobel Biocare, Цюрих, Швейцария) и мульти юнит абатменты. Имплантаты были установлены с помощью хирургического шаблона, который был заранее спланирован и изготовлен цифровым методом. После установки имплантатов в скуловую кость, они сразу были нагружены предварительно изготовленными пластиночными временными протезами, которые после примерки и приспособления титановыми колпачками были временно ввинчены к имплантатам. Постоянные протезы были установлены 6 месяцев спустя. Небная часть этих протезов из себя представляет как отдельный элемент и с помощью магнитов присоединяется к основной части протеза, который прикручен к имплантатам. Через отверстие, созданное при отсоединении небной части протеза, осуществляется наблюдение, уход, антисептическая обработка и выполнение гигиенических процедур (ирригация, полоскание). Оценку функциональной эффективности лечения проводили до и после протезирования со скуловыми имплантатами с использованием профиля воздействия на здоровье полости рта (ОНП-14) и жевательного функционального индекса. Качество жизни оценивалось с использованием опросника качества жизни Вашингтонского университета версии 4 (UW-QOLv4).

Полученные результаты. Послеоперационных осложнений не наблюдалось, и через 7-10 дней пациент был выписан из стационара. Пациенты смогли вернуться к нормальной диете (твердой) всего через 7 дней после операции, без дальнейших жалоб на функционирование или боль, за исключением остаточного отека, вызванного вмешательством. Качество жизни пациентов, связанное со здоровьем (HR-QOL), до лечения составляло $\geq 48,3\%$. HR-QOL и общее качество жизни после реабилитации были оценены как хорошие 76,8% соответственно. Во всех случаях жевание также было наиболее важной функцией для пациентов (до имплантации 26,4% и после 67,3%), показатели жевательной функции увеличились после ортопедического лечения с помощью имплантатов.

Выводы: Применение протеза с фиксацией на скуловых имплантатах у пациентов с дефектами верхней челюсти является эффективным методом ортопедической реабилитации в сложных клинических случаях после челюстно-лицевой операции.

DOI: 10.58240/1829006X-2023.19.4-72



ORIGINAL ARTICLE

ACCURACY OF A ROBOTIC DENTAL IMPLANT NAVIGATION SYSTEM IN DENTAL IMPLANT PRACTICE

Karen Grigoryan DDS, PhD*

Associate Professor Yerevan State Medical University after M. Heratsi, Founder-Chairman of the Avanta Center for Innovative Medicine, Yerevan, Armenia

* Corresponding author: Associate Professor Karen Grigoryan, Avanta Center for Innovative Medicine, Yerevan, Armenia;
e-mail: kardent@gmail.com

Received: Oct. 2, 2023; **Accepted:** Oct. 27, 2023; **Published:** Nov. 5, 2023

Abstract

Objective: To evaluate the implant positioning accuracy using a robotic implant navigation system in dental implant practice.

Methods: The analysis of the treatment of 16 patients using a robotic implant navigation system in stages implant surgery and dental implant prosthetic rehabilitation performed for the period 2022-2023. All patients underwent a complex clinical, laboratory study, computed tomography (CT).

A total of 46 implants were installed using the Navident (ClaroNav) navigation system a flapless or minimal flap approach. 25 implants were completely edentulous and 21 implants were installed in a partially edentulous area.

To assess the accuracy of dental implant placement using preoperative plan cone beam computed tomography (CBCT), deviations between the planned and installed implant positions were analyzed. The coronal deviation was measured as the distance between the centers of the implant coronal platform. Apical deviation was measured as the distance between the centers of the implant apical. Angular deviation was measured as the angle of the axis of the implant center.

Success of implantation and success of prosthetics of implant-supported reconstructions were evaluated. Data were statistically analyzed with.

Results: No intra-operative or immediate post-operative complications were noted after procedure. The postoperative of the patients was favorable.

For all implants, the mean deviations were: 0.21 mm at the entry point (lateral) and 0.27 mm at the apex. The average angle deviation from the actual and planned implant position was 1.32 degrees. Patients were satisfied with the functional and aesthetic results of implantation.

Conclusion: Robotic implant navigation system allows for precise implant placement, the level of experience of the surgeon and the location of the implant do not affect the accuracy of placement and the timing of the procedure.

Keywords: digital technologies, artificial intelligence, guided implant surgery, dental implant, navigation system.

Introduction

To eliminate surgical risks in implant treatments, it is very important to have detailed preoperative planning to ensure correct placement of the implant, taking into account the characteristics of the alveolar bone (bone quality, thickness and height) and the anatomical changes in the surgical site (e.g. nasal fossa, mandibular canal, mental foramen) and sinuses).¹

However, various complications arise at different stages of implantation, such as damage to adjacent structures, aesthetic problems, peri-implant inflammation and even implant rejection.²

Along with the development of digital technologies, in the last decade, implantology has gained a lot of popularity guided implant surgery (GIS), which allows the planned restorative design to be transferred directly to the surgical field.³

These methods include the use of surgical templates that can be produced using conventional computer-aided design / computer-aided manufacturing (CAD/CAM) technologies (milling or stereolithography).

Thus, the use of a surgical template makes the operation less invasive, reduces the risk of complications and has great prospects for development.⁴

Although there are reports comparing the use of a surgical template and a freehand implant, it is not entirely clear whether a surgical template can actually increase the accuracy of the implant. In that direction, many studies are conducted to evaluate the effectiveness of the method.⁵

In recent years, the use of artificial intelligence has also become widespread in oral implantology.⁶

Artificial intelligence (AI) - imitates human intelligence and improves its characteristics, using deep analysis methods, this model

Computer science, aimed at performing various specific functions that require human intelligence.⁷

There are studies in the literature in which this method was used to interpret anatomical. The use of artificial intelligence systems in the interpretation of CT images provides the doctor with many advantages and can help in detailed implantation planning.⁸

Robotics is a breakthrough technology that will change diagnostic and treatment protocols in dentistry

while improving the overall quality and scope of patient care.⁹

Artificial intelligence has been used in various fields of medicine, but its integration in dentistry has occurred quite recently, it is obvious that it will make a great contribution to the development of dentistry, will lead to much better treatment results.¹⁰

The term "artificial intelligence" was coined by John McCarthy, mathematician, in 1955 and is widely known as the father of artificial intelligence.¹¹

In the last decade, the introduction of artificial naturalness (AI) and robotic technologies in implant dentistry has opened up new vistas for the development of the field, ushering in a new era of development of this advanced treatment method. Artificial intelligence (AI) and robotic systems increase the accuracy of implant placement, reducing human error and ensuring high treatment efficiency.¹²

The field of dental implantology has seen tremendous progress in recent years thanks to the integration with robotic technology and artificial intelligence (AI).¹³

AI suites are equipped with algorithms that analyze extensive patient data to aid in diagnosis, treatment planning, optimizing the implant placement process, and increasing implant survival rates.

Along with all these benefits, the balance of trust between human factor and robotic technologies must be addressed while maintaining the highest standards of ethical norms.

Artificial intelligence (AI) algorithms make it possible to analyze a huge amount of data, helping doctors to choose optimal and treatment plans by combining it with the clinical anatomical features of the patients and adapting it to the needs of the individual patient.¹⁴

Artificial intelligence is used to screen, diagnose and treat patients and has also been used in the research of new drugs and vaccines, monitoring and tracking important indicators, symptoms and other data to help identify potential health problems at an early stage.¹⁵

However, there is little research data on the reliability and accuracy of autonomous robots.

Despite the progress reported in this field, there are challenges and ethical considerations that need to be reviewed and a new approach is needed.

Navigated implant surgery based on CT image data has been introduced in dental implantology to improve the accuracy of implant placement and prevent potential complications. Surgical navigation systems for implant placement, determine virtual location in real time, track implant drills and the patient throughout the operation.

Surgical navigation systems for implant placement, determine virtual location in real time, track implant drills and the patient throughout the operation

One of the main advantages of robotic technology in implant dentistry is its accuracy and precision, as robotic systems can offer optimal solutions among complex anatomical structures with exceptional precision, reducing the risk of errors and complications.¹⁶

Several successful case studies published in the literature have demonstrated the effectiveness of robotic and artificial intelligence-assisted implant dentistry.¹⁷

For example, robotic systems have been used to perform complex implant surgeries with high precision, resulting in improved implant survival rates and patient satisfaction.

AI algorithms have helped accurately identify bone quality and quantity, facilitating optimal implant placement and reducing the risk of implant failure. These advances have allowed for shorter operative times, improved aesthetic outcomes, and improved patient comfort.

For example, robotic systems have been used to perform complex implant surgeries with high precision, resulting in improved implant survival rates and patient satisfaction. AI algorithms have helped accurately identify bone quality and quantity, facilitating optimal implant placement and reducing the risk of implant failure.¹⁸ These advances have allowed for shorter operative times, improved aesthetic outcomes, and improved patient comfort.

Disadvantage of robotic Surgical navigation systems is the ability to determine the torque when inserting the implant.

Despite the many benefits, there are also challenges and ethical considerations associated with the integration of robotics and artificial intelligence in implant dentistry.¹⁹ One of the primary concerns is the proper balance between human expertise and reliance on technology.

In 2017, the FDA approved YOMITM (Neotiss, Miami, Florida, USA), which became the world's first computerized navigation robotic system to improve the clinical accuracy of dental implant surgery.²⁰

The YOMI navigation system provided control of drill depth, orientation and position, thereby avoiding custom fabrication of a surgical template and operator hand deviation, providing high predictability and accuracy in preparation for dental implant osteotomy.

Artificial intelligence algorithms help accurately determine the quality and quantity of bone, promoting optimal implant placement and reducing risk, reducing surgical time, improving aesthetic results and increasing patient comfort.²¹

While robots provide precision and artificial intelligence promotes analytical prowess, the human element in dentistry remains.

However, most navigation studies are in vitro studies, so it is important to obtain the results of applying this technique on clinical material

Material and Methods

The analysis of the treatment of 16 patients using, using a robotic implant navigation system in stages implant surgery and dental implant prosthetic rehabilitation performed for the period 2022-2023. All patients underwent a complex clinical, laboratory study, cone beam computed tomography (CT).

The inclusion criteria for this study were as follows:

- (1) patients with total or partial defect of dentition,
- (2) absence of uncontrolled systemic diseases contraindicated for implantation,
- (3) good oral health.

Exclusion criteria were as follows: limited mouth opening, presence of untreated periodontitis, significant resorption in the implantation site, presence of systemic disease that makes the patient unsuitable for implants.

A total of 46 implants were installed using the Navident (ClaroNav) navigation system a flapless or minimal flap approach. 25 implants were completely edentulous and 21 implants were installed in a partially edentulous area

To assess the accuracy of dental implant placement using preoperative plan cone beam computed

tomography (CBCT), deviations between the planned and installed implant positions were analyzed. The coronal deviation was measured as the distance between the centers of the implant coronal platform. Apical deviation was measured as the distance between the centers of the implant apical. Angular

deviation was measured as the angle of the axis of the implant center.

The DICOM CBCT file was imported into the Navident system for treatment planning with design of implant placement, future crown and abutment design (figure 1-7).

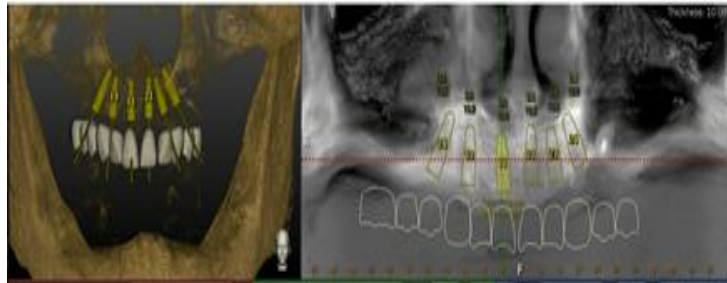


Figure 1. Upper jaw complete edentulous recovery 6 implants

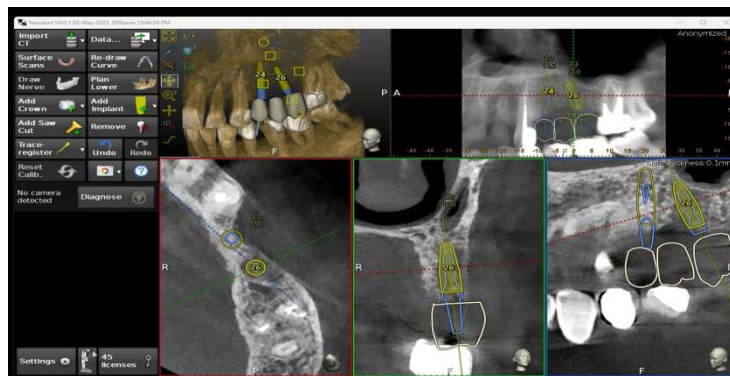


Figure 2. Upper jaw angular implant placement to bypass sinus floor

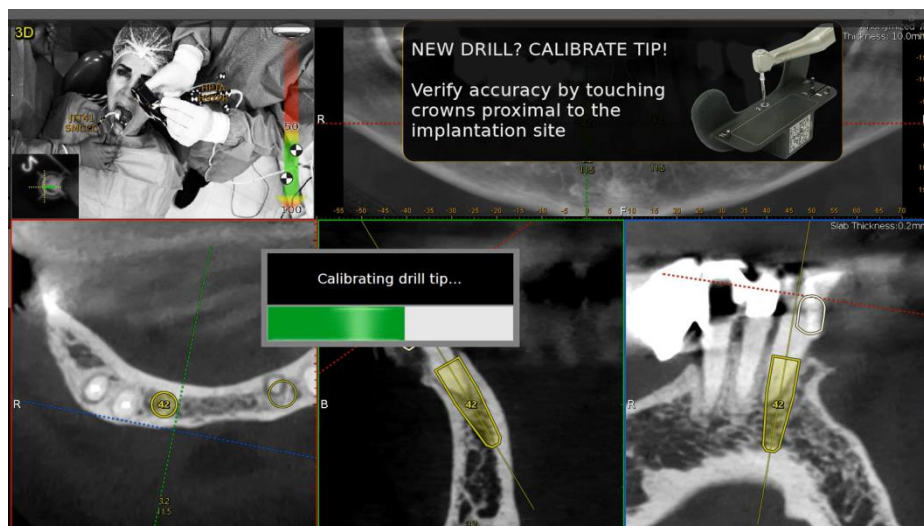


Figure 3. New drill calibration for the system to recognize prior starting the drilling process

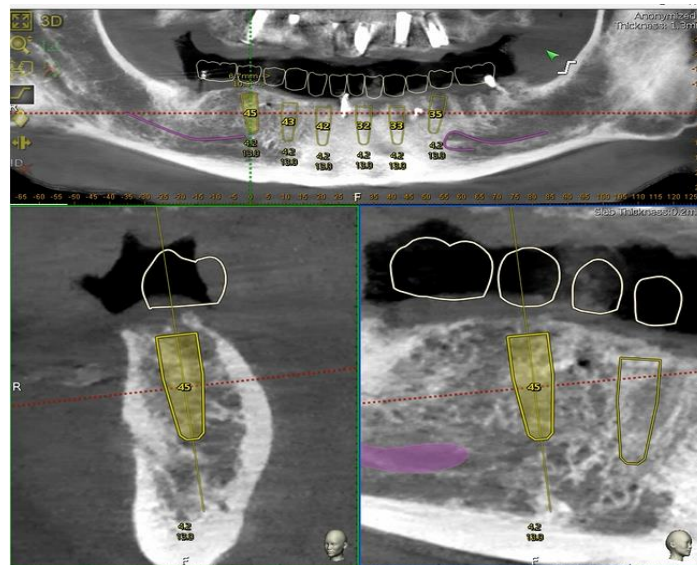


Figure 4. Lower jaw implants, nerve position

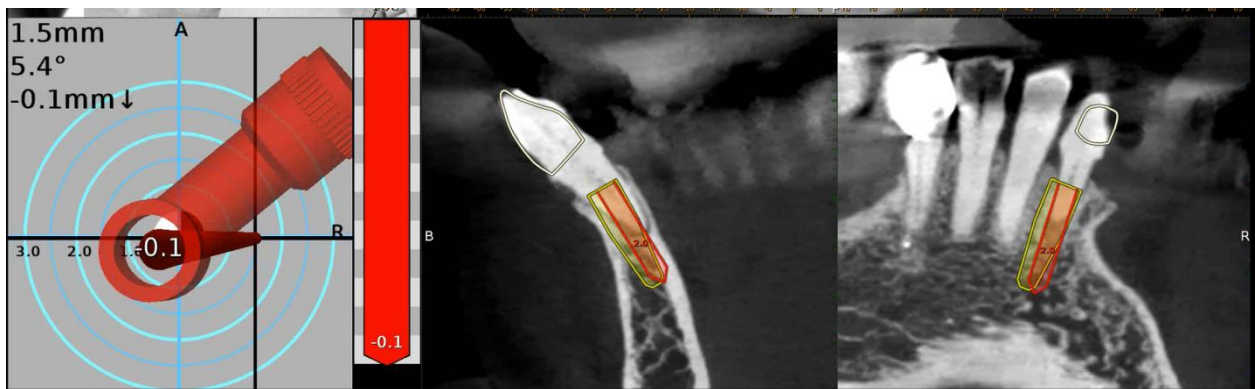

Figure 5. Drill is too far from the placed implant on CBCT

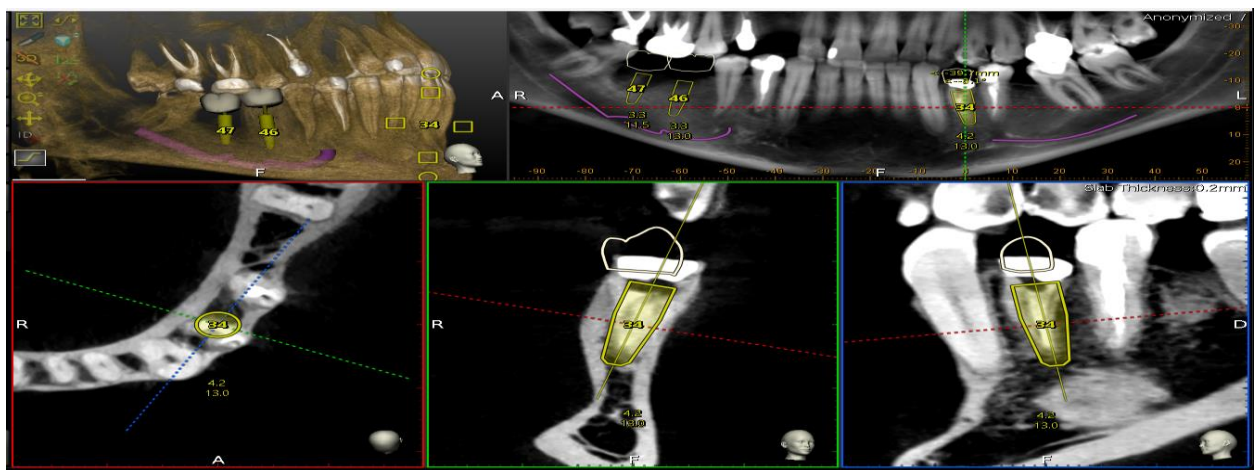


Figure 6. Lower jaw implants placement taking into notice the important structure (nerve)

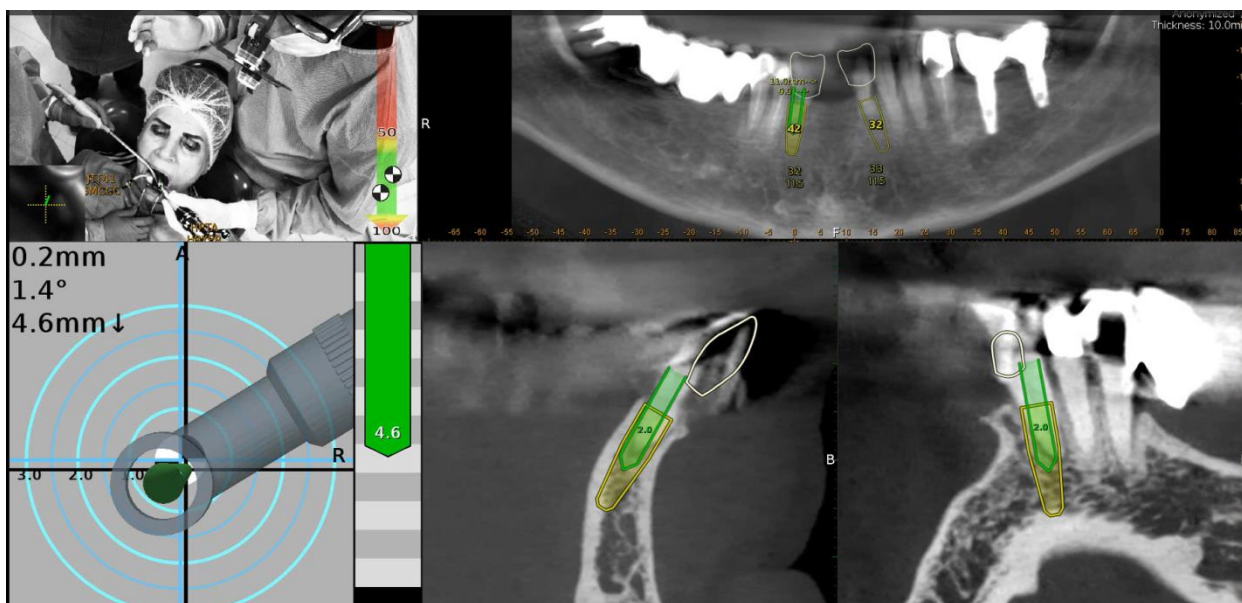


Figure 7. Drill is in the correct position according to the plan

Surgical procedure

The Head-Tracker has been installed and tested for stability. Trace registration was performed by marking four landmarks on the teeth using a panoramic 3D image of the jaw and then tracing the landmark areas using the tracing tool while the camera and software collected 100 points on each tooth. Navident automatically registered the Head-Tracker to a CBCT scan of the patient's maxilla based on the collected points.

Before use, each drill was calibrated and checked for accuracy. A small incision was made to accommodate the reduction flap. All osteotomies were performed at 800 rpm. the virtual implant was repositioned intraoperatively using Navident software, and the rest of the site preparation was performed according to the final angulation using drills. Osteotomies were performed at two angles and monitored in real time, and the same procedure was used for implant placement. The cover screw was attached before the surgical site was sutured.

To assess the accuracy of dental implant placement using preoperative plan cone beam computed tomography (CBCT), deviations between the planned and installed implant positions were analyzed. The coronal deviation was measured as the distance between the centers of the implant coronal platform. Apical deviation was measured as the distance between the centers of the implant apical. Angular

deviation was measured as the angle of the axis of the implant center.

Once the surgery was completed, the file was converted to an STL file, allowing the laboratory to access the treatment plan.

Success of implantation and success of prosthetics of implant- supported reconstructions were evaluated. Data were statistically analyzed with.

Results

No intra-operative or immediate post-operative complications were noted after autografting procedure. The postoperative of the patients was favorable.

For all implants, the mean deviations were: 0.21 mm at the entry point (lateral) and 0.27 mm at the apex. The average angle deviation from the actual and planned implant position was 1.32 degrees. Patients were satisfied with the functional and aesthetic results of implantation.

Discussion

Research is currently underway to improve the integration of artificial intelligence with computer design and manufacturing (CAD/CAM) to optimize the entire implantation process, providing a more predictable and efficient implantation process.^{22,23}

One of the most important factors influencing the result of implantation therapy is the accuracy of implant placement. To ensure the correct position of the implant installation in accordance with the design of the prosthesis a surgical guide is used, however, the errors of surgical guides generated by computed tomography (CT) depend on the manufacturing method and design.²⁴

In the modern world, artificial intelligence refers to a technology that can imitate human cognitive skills, such as problem solving, which depends on algorithms for predicting results based on a set of data.²⁵

Thanks to a large number of artificial neurons (or nodes) connected into neural networks, the system evaluates large volumes of data to perform specific tasks, among which diagnostic data, personalized treatment, and treatment evaluation play an important role.²⁶

Neural networks are a set of algorithms that compute signals through artificial neurons that function like the human brain. The medical robotics industry has recently shifted its focus to autonomous robotic technologies that can independently perform a procedure without constant supervision.

The development of artificial intelligence (AI) in healthcare research has led to its spread in dentistry. Artificial intelligence in dentistry is emerging as an auxiliary tool as a central principle for ensuring safe and effective treatment. When applied to dentistry, artificial intelligence has enormous potential for simplifying diagnostics, eliminating unnecessary procedures, minimizing postoperative complications and predicting treatment results. All this has a positive impact on the quality of treatment due to fewer interventions, diagnostic accuracy and more reliable recovery.

The application of artificial intelligence to predict implant success and optimize implantation has shown great potential, but additional research is needed to further develop and evaluate the clinical effectiveness of artificial intelligence models for widespread implementation in the field of implantology.²⁷

Despite the prediction that the widespread adoption of artificial intelligence (AI) in dentistry could revolutionize dentistry, research on the use of artificial intelligence in dental technology is still scant in the literature.

One of the applications of AI in implantology is the use in digital three-dimensional (3D) treatment

planning based on CT data and can help the practitioner determine the optimal number, size, location for implant installation, and the development of dentures, thereby reducing the risk of complications during surgery and increasing success of implant installation.

The next stage of this achievement was the introduction of this planning into the dynamic implant navigation system.

The use of artificial intelligence will revolutionize implantology in the coming years. Today, in implantology, thanks to artificial intelligence (AI), software allows the dentist to view holographic 3D models of the patient and use them to make the correct diagnosis, as well as illustrate the selected treatment plan to the patient.

A breakthrough in implantology was a new computer navigation system for implant installation.

Currently, dynamic navigation is the most effective way to communicate the planned implant position to a real patient, as it guides surgeons' movements using real-time feedback.

Our research was aimed at studying the effectiveness of the use of artificial intelligence in the practice of dental implantology.

Implants were installed using the Navident (ClaroNav) navigation system. This dynamic navigation system allowed precise placement of the implant within 0.5 mm of the treatment unit.

The handpiece tracker (Rocket) allowed the hand to be tracked throughout the process from multiple angles, enabling precise and efficient surgical intervention. Navident provided visibility of drill movement from the simplest to the most complex cases. The system allowed for minimally invasive surgery to bypass critical structures. The optical camera in the Navident system allowed (175 degrees horizontal and 90 degrees vertical movement) precise and accurate tracking of the surgical area throughout the entire process.

Deviations between planned and installed implant positions, implantation success, and prosthetic success of implant-supported reconstruction were assessed. For all implants, the average deviations from the actual and planned position of the implant were insignificant, which did not affect the effectiveness of implantation. Patients were satisfied with the functional and aesthetic results of implantation.

Thanks to its enormous advantage, artificial intelligence is an additional assistant for specialists and its use is not intended to replace the dentist, but to increase the efficiency of treatment and procedures and give the doctor more confidence to monitor the condition of his patient at every stage of the most complex procedures.

The use of artificial intelligence in implantology is just beginning, and in the coming years it will create a revolution, as it will lead to much better results; however, multicenter long-term studies are needed on all aspects to give an objective assessment

Conclusion

Robotic implant navigation system allows for precise implant placement; the level of experience of the surgeon and the location of the implant do not affect the accuracy of placement and the timing of the procedure.

Declarations

Conflict of interest and financial disclosure

The author declares that he has no conflict of interest and there was no external source of funding for the present study. None of the authors have any relevant financial relationship(s) with a commercial interest.

Ethical approval

Research protocol was approved by the local Ethical Committee (2018/23) and in accordance with those of the World Medical Association and the Helsinki Declaration.

Informed consent

Informed consent was obtained from all individual participants included in the study.

Source of Funding

Non funding.

Availability of Data and Materials

Not applicable.

REFERENCES

1. Correa LR, Spin-Neto R, Stavropoulos A, Schropp L, da Silveira HED, Wenzel A. Planning of dental implant size with digital panoramic radiographs, CBCT-generated panoramic images, and CBCT cross-sectional images. *Clin Oral Implant Res.* 2014;25:690–5. doi:10.1111/clar.12126
2. Marcantonio C, Nicoli LG, Junior EM, et al. Prevalence and possible risk factors of peri-implantitis: A concept review. *J Contemporary Dental Practice.* 2015;16(9):750–7. doi:10.5005/jp-journals-10024-1752
3. Colombo M, Mangano C, Mijiritsky E, Krebs M, Hauschild U, Fortin T. Clinical applications and effectiveness of guided implant surgery: A critical review based on randomized controlled trials. *BMC Oral Health.* 2017;17(1):150. doi:10.1186/s12903-017-0441-y
4. Putra RH, Yoda N, Astuti ER, Sasaki K: The accuracy of implant placement with computer-guided surgery in partially edentulous patients and possible influencing factors: A systematic review and meta-analysis. *J Prosthodont Res.* 2022;66:29-39. doi:10.2186/jpr.JPR_D_20_00184
5. Shen P, Zhao J, Fan L, et al. Accuracy evaluation of computer-designed surgical guide template in oral implantology. *Journal of Cranio-Maxillofacial Surgery.* 2015;43(10):2189-2194. doi:10.1016/j.jcms.2015.10.022
6. Revilla-León M, Gómez-Polo M, Vyas S, et al. Artificial intelligence applications in implant dentistry: A systematic review. *J Prosthet Dent.*

- 2023;129(2):293-300.
doi:10.1016/j.prosdent.2021.05.008
7. Saeed A, Alkhurays M, Al Mutlaqah M, Al Azbah M, Alajlan SA. Future of Using Robotic and Artificial Intelligence in Implant Dentistry. *Cureus*. 2023;15(8):43209. doi:10.7759/cureus.43209
 8. Putra RH, Doi C, Yoda N, Astuti ER, Sasaki K. Current applications and development of artificial intelligence for digital dental radiography. *Dentomaxillofac Radiol*. 2022;51(1):20210197. doi:10.1259/dmfr.20210197
 9. Vodanović M, Subašić M, Milošević D, Savić Pavičič I. Artificial Intelligence in Medicine and Dentistry. *Acta Stomatol Croat*. 2023;57(1):70-84. doi:10.15644/asc57/1/8
 10. Wu Y, Wang F, Fan S, Chow JK. Robotics in dental implantology. *Oral Maxillofac Surg Clin North Am*. 2019;31:513–518. doi:10.1016/j.coms.2019.03.013
 11. Rajaraman, V. JohnMcCarthy — Father of artificial intelligence. *Reson*. 2014;19:198–207. doi:10.1007/s12045-014-0027-9
 12. Khanagar SB, Al-Ehaideb A, Maganur PC, et al. Developments, application, and performance of artificial intelligence in dentistry - a systematic review. *J Dent Sci*. 2021;16:508–522. doi:10.1016/j.jds.2020.06.019
 13. Bohr A, Memarzadeh K. The rise of artificial intelligence in healthcare applications. *Artificial Intelligence in Healthcare*. 2020;25–60. doi:10.1016/B978-0-12-818438-7.00002-2
 14. Xie Y, Lu L, Gao F, et al. Integration of Artificial Intelligence, Blockchain, and Wearable Technology for Chronic Disease Management: A New Paradigm in Smart Healthcare. *Curr Med Sci*. 2021;41(6):1123–33. doi:10.1007/s11596-021-2485-0
 15. Liu L, Watanabe M, Ichikawa T. Robotics in Dentistry: A Narrative Review. *Dent J (Basel)*. 2023;11(3):62. doi:10.3390/dj11030062
 16. Chen J, Bai X, Ding Y, et al. Comparison the accuracy of a novel implant robot surgery and dynamic navigation system in dental implant surgery: An in vitro pilot study. *BMC Oral Health*. 2023;23(1):179. doi:10.1186/s12903-023-02873-8
 17. Aydemir CA, Arisan V. Accuracy of dental implant placement via dynamic navigation or the freehand method: A split-mouth randomized controlled clinical trial. *Clin Oral Implants Res*. 2020;31(3):255–63. doi: 10.1111/clr.13563
 18. Block MS, Emery RW, Cullum DR, Sheikh A. Implant Placement is more Accurate using dynamic Navigation. *J Oral Maxillofac Surg*. 2017;75(7):1377–86. doi:10.1016/j.joms.2017.02.026
 19. Siessegger M, Schneider BT, Mischkowski RA, et al. Use of an image-guided navigation system in dental implant surgery in anatomically complex operation sites. *J Cranio-Maxillofac Surg*. 2001;29:276–81. doi:10.1054/jcms.2001.0242
 20. Yeshwante B, Baig N, Tambake SS, Tambake R, Patil V, Rathod R. Mastering dental implant placement: A review. *J. Appl. Dent. Med. Sci*. 2017;3:220–227. doi:10.1054/jcms.2001.0242
 21. Lisacek-Kiosoglous AB, Powling AS, Fontalis A, Gabr A, Mazomenos E, Haddad FS. Artificial intelligence in orthopaedic surgery. *Bone Joint Res*. 2023;12(7):447-454. doi:10.1302/2046-3758.127.BJR-2023-0111.R1
 22. Naidu V, Jaju S. CAD/CAM Engineering and Artificial Intelligence In Dentistry. *IOP Conference Series Materials Science and Engineering*. 2022;1259(1):012018. doi:10.1088/1757-899X/1259/1/012018
 23. Ahmad P, Alam MK, Aldajani A, et al. Dental robotics: a disruptive technology. *Sensors (Basel)*. 2021;21(10):3308. doi:10.3390/s21103308
 24. Kurt Bayrakdar S, Orhan K, Bayrakdar IS, et al. A deep learning approach for dental implant planning in cone-beam computed tomography images. *BMC Med Imaging*. 2021;21:86. doi:10.1186/s12880-021-00618-z

25. Sheikh H, Prins C, Schrijvers E. Artificial Intelligence: Definition and Background. *Mission AI*. 2023;21(1):15-41. doi:10.1007/978-3-031-21448-6_2
26. Shirmohammadi A, Ghertasi Oskouei S. The growing footprint of artificial intelligence in periodontology & implant dentistry. *J Adv Periodontol Implant Dent*. 2023;15(1):1-2. doi:10.34172/japid.2023.012
27. Lin GSS, Ng YS, Ghani NNA, et al. Revolutionising dental technologies: a qualitative study on dental technicians' perceptions of Artificial intelligence integration. *BMC Oral Health* 23. 2023;690. doi:10.1186/s12903-023-03389-x

ԻՄՊԼԱՆՏՆԵՐԻ ՆԱՎԻԳԱՑԻՈՆ ՀԱՄԱԿԱՐԳԻ ՃՇՊՐՏՈՒԹՅՈՒՆԸ ԻՄՊԼԱՆՏՆԵՐԻ ՊՐԱԿՏԻԿԱՅՈՒՄ

Կարեն Գրիգորյան

Երևանի Մ. Հերացու անվան պետական բժշկական համալսարանի դոցենտ, Ավանտա նորարարական բժշկության կենտրոնի հիմնադիր-նախագահ, Երևան, Հայաստան

Ամփոփում

Նպատակը. Գնահատել իմպլանտների դիրքավորման ճշգրտությունը՝ օգտագործելով ռոբոտային իմպլանտների նավիգացիոն համակարգը ստոմատոլոգիական իմպլանտոլոգիայում:

Մեթոդներ. Մենք վերլուծել ենք 16 հիվանդի բուժումը՝ օգտագործելով ռոբոտային իմպլանտների նավիգացիոն համակարգ՝ փուլային իմպլանտացիայի վիրահատության և իմպլանտների վրա հենված ատամների պրոթեզավորման ժամանակ, որոնք կատարվել են 2022-2023 թվականներին: Բոլոր հիվանդները ենթարկվել են համալիր կլինիկական և լաբորատոր հետազոտություն և համակարգչային տոմոգրաֆիա (CT):

Ընդհանուր առմամբ 46 իմպլանտներ են տեղադրվել՝ օգտագործելով Navident (ClaroNav) նավիգացիոն համակարգ: 25 իմպլանտ տեղադրվել է ամբողջությամբ անատամ հատվածում, իսկ 21 իմպլանտը տեղադրվել է մասամբ անատամ հատվածում: Իմպլանտների տեղադրման ճշգրտությունը գնահատելու համար պլանավորված և տեղադրված իմպլանտների դիրքերի միջև շեղումները վերլուծվել են՝ օգտագործելով նախավիրահատական ճառագայթային համակարգչային տոմոգրաֆիան (CBCT): Պսակի շեղումը չափվել է որպես իմպլանտի պսակային հարթակի կենտրոնների միջև հեռավորություն: Գազաթային շեղումը չափվել է որպես իմպլանտի գազաթային մասի կենտրոնների միջև հեռավորություն: Անկյունային շեղումը չափվել է որպես իմպլանտի կենտրոնի առանցքի անկյուն:

Գնահատվել է իմպլանտացիայի արդյունավետությունը և իմպլանտների վրա հենված պրոթեզների արդյունավետությունը: Տվյալները վիճակագրորեն վերլուծվել են՝ օգտագործելով:

Արդյունքները. Իմպլանտացիայի ժամանակ ներվիրահատական կամ անմիջական հետվիրահատական բարդություններ չեն արձանագրվել: Հիվանդների հետվիրահատական շրջանը բարենպաստ է եղել: Բոլոր իմպլանտների համար միջին շեղումները եղել են՝ 0.21 մմ մուտքի կետում (կողային) և 0.27 մմ ծայրամասում: Միջին անկյունային շեղումը իմպլանտի իրական և պլանավորված դիրքից եղել է 1.32 աստիճան: Հիվանդները գոհ էին իմպլանտացիայի ֆունկցիոնալ և էսթետիկ արդյունքներից:

Եզրակացություն. Իմպլանտների նավիգացիոն ռոբոտային համակարգը թույլ է տալիս իմպլանտների ճշգրիտ տեղադրում: Վիրաբույժի փորձի մակարդակը և իմպլանտի տեղադրման հատվածը չեն ազդում տեղադրման ճշգրտության և ընթացակարգի ժամանակի վրա:

ТОЧНОСТЬ РОБОТИЗИРОВАННОЙ СИСТЕМЫ НАВИГАЦИИ ДЕНТАЛЬНЫХ ИМПЛАНТОВ В ПРАКТИКЕ ДЕНТАЛЬНОЙ ИМПЛАНТАЦИИ

Карен Григорян

Доцент Ереванского государственного медицинского университета имени М. Гераци, Основатель-председатель Центра инновационной медицины «Аванта», Ереван, Армения

Абстракт

Цель: Оценить точность позиционирования имплантата с помощью роботизированной системы навигации в практике дентальной имплантологии.

Методы: Проведен анализ лечения 16 пациентов с использованием роботизированной системы навигации имплантатов в поэтапной имплантационной операции и протезировании зубов на имплантатах, проведенных за период 2022-2023 гг. Всем пациентам проведено комплексное клинично-лабораторное исследование, компьютерная томография (КТ).

Всего было установлено 46 имплантатов с использованием навигационной системы Navident (ClaroNav) безлоскутным или минимальным лоскутным подходом. 25 имплантатов были полностью беззубы и 21 имплантат установлен в частично беззубом участке.

Для оценки точности установки дентального имплантата с помощью предоперационной плановой конусно-лучевой компьютерной томографии (КЛКТ) анализировали отклонения между запланированным и установленным положениями имплантата. Корональное отклонение измеряли как расстояние между центрами коронковой платформы имплантата. Апикальное отклонение измеряли как расстояние между центрами апикальной части имплантата. Угловое отклонение измеряли как угол оси центра имплантата.

Оценивались успешность имплантации и успешность протезирования с опорой на имплантаты. Данные были статистически проанализированы с помощью .

Результаты: При дентальной имплантации не было отмечено никаких интраоперационных или ближайших послеоперационных осложнений. Послеоперационный период у пациентов был благоприятным,

Для всех имплантатов средние отклонения составили: 0.21 мм в точке входа (латерально) и 0.27 мм на верхушке. Среднее угловое отклонение от фактического и запланированного положения имплантата составило 1.32 градуса. Пациенты были удовлетворены функциональными и эстетическими результатами имплантации.

Заключение. Роботизированная система навигации позволяет точно установить имплантат, уровень опыта хирурга и расположение имплантата не влияют на точность установки и сроки проведения процедуры.

DOI: 10.58240/1829006X-2023.19.4-83



CASE REPORT

RARE ODONTOSTOMATOLOGY COMPLICATION ASSOCIATED WITH DISLOCATION OF A SILASTIC NASAL SPLINT: A CASE REPORT

Francesco Litta,¹ Lucia Memè,³ Filippo Grilli,¹ Enzo Iacomino,¹ Fratini Chiara,² Fabrizio Bambini,^{3*} Stefano Mummolo¹

¹ Department of Life, Health and Environmental Sciences, Università degli Studi dell'Aquila, 67100 L'Aquila, Italy

² Department of Sense Organs, Sapienza University of Rome, Viale del Policlinico 155, 00186, Rome, Italy

³ Department of Clinical Sciences and Stomatology, Polytechnic University of Marche, Ancona, Italy

* Corresponding author: Prof. Fabrizio Bambini, Associate professor in Oral Surgery and Implantology, School of Dentistry at Polytechnic University of Marche;
e-mail: f.bambini@staff.univpm.it

Received: Oct. 2, 2023; **Accepted:** Oct. 27, 2023; **Published:** Nov. 5, 2023

Abstract

Silastic is a type of silicone elastomer that has been widely used in various medical applications. One of its popular uses is in aesthetic medicine, specifically as an implant in the nose to enhance its appearance. The potential complications of extrusion, infection, and migration are minimal if the implant is placed in a separate watertight compartment with a tension-free closure and no impingement of the nasal dome. In this Case Report the patient arrived with a periodontitis disease and the silastic sheet was found adjacent to the incisor teeth during oropharyngoscopy to treat acute periodontitis. The authors do not know if the silastic sheet was the direct cause of the acute periodontitis or if the periodontitis creates the migration the infection and the extrusion of the implant. It is possible that the silastic sheet used in the previous rhinoplastic surgery reconstruction had migrated to the perimeter of the premaxilla and induced the chronic inflammation around the teeth or more probably some conditions such as initially gingivitis, complicated on Periodontitis precipitated the acute purulent inflammation of the periodontal tissue and followed by implant extrusion, foreign body reaction, and infection.

Keywords: dental complication, nasal splint, dislocation of silastic.

Introduction

Several materials, both biologic and alloplastic, have been used for nasal augmentation. Although biologic bone and cartilage grafts are associated with lower infection rates, they are also associated with long-term resorption and donor-site morbidity.

Alloplastic materials, in particular silicone, have been associated in the literature with extrusion and infection but have the advantages of being affordable and easy to reshape with no requirement for harvesting autografts.¹ There are a variety of techniques that can be used to enhance or improve the nasal tip. These techniques often use suture techniques and invisible

grafts to achieve the desired result as Columellar Strut² or Silastic implant³ or without graft.⁴ The former methods have been well described throughout the literature. The potential complications of extrusion, infection, and migration are minimal if the implant is placed in a separate watertight compartment with a tension-free closure and no impingement of the nasal dome.⁵ Nevertheless, each method presented various complications⁶ and especially regarding Silastic. Silastic is a type of silicone elastomer that has been widely used in various medical applications.

One of its popular uses is in aesthetic medicine, specifically as an implant in the nose to enhance its

appearance. Silastic is a highly cross-linked polymer that is composed of a silicone elastomer. It has high tensile strength, good tear resistance, and is highly resistant to temperature changes, making it an ideal material for medical implants. Silastic is also highly biocompatible, meaning that it does not cause any harmful reactions when implanted in the body. This makes it a suitable material for use in aesthetic medicine.⁷ A silastic sheet is made from a Dacron mesh that is added to silicone, and has been used in the surgical sections for various purposes including Ent surgery for Septal surgery or Septoplasty.⁸

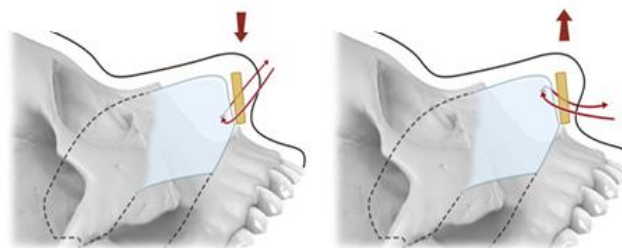


Figure 1. Different types of sutures in the volume augmentation technique with silastic implant support

Case Report

On 03.12.2022 at 5:30 p.m., a 37-year-old patient presented to our observation, who reported pain for about two months and gingival hyperemia with the presence of aphthae in the upper jaw region. On E.O., perforation of the gingival fornix extended between 1.3 and 2.3, leakage of exudate and purulent material and presence of mobile silastic membrane placed about 2 years ago during a corrective rhinoplasty surgery made in Turkey. The opt notes an area of confluent osteolysis between 1.3, and 1.4 and 2.6, periodontitis sloughing of 2.1 and residual root of 1.1, absence of 1.2 and 3.7. Mucosal basisinus thickening of the maxillary sn. We proceeded to perform a second-level radiographic examination, Tc survey of the maxillary upper jaw shows, confluent periapical osteolysis interesting the periodontal of 1.3 and 1.4 with district lifting of the basisinus floor and disruption of continuity of the basisinus bone limiting. Vestibular bony cortical reabsorption and corresponding alveolar wall area 13-23. Defect of substance at fingernail strike of the perspicacity of 22. The patient returns to our observation after 5 days

after performing antibiotic injection therapy with Ceftriaxone 1g x 2 and Metronidazole 250g 1x 3. We proceed to partial removal of the Silastic membrane by access from the gingival fornice, remove mucosal adhesions and perform washings with Rifampicin Sodium. Given the impossibility of performing a complete suture because of the altered anatomy and poor mucosal quality, we prefer to let healing occur by second intention. Postoperative checkup after 8 days, absence of exudate, color and consistency of the mucosa have markedly improved, and the site appears to be healing. The patient unfortunately did not show up for follow-ups.

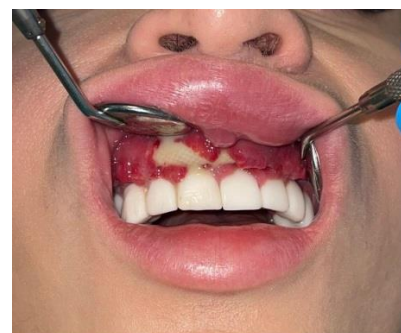

Figure 2. Perforation of the gingival fornix and presence of mobile silastic membrane

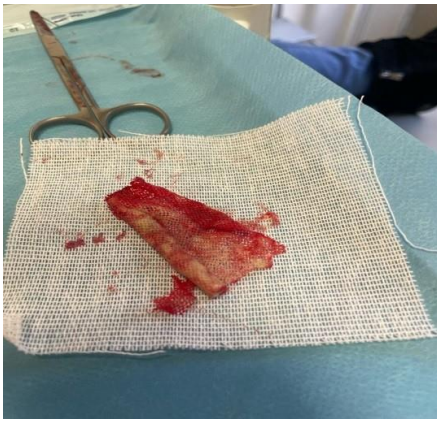

Figure 3. The Silastic membrane removed

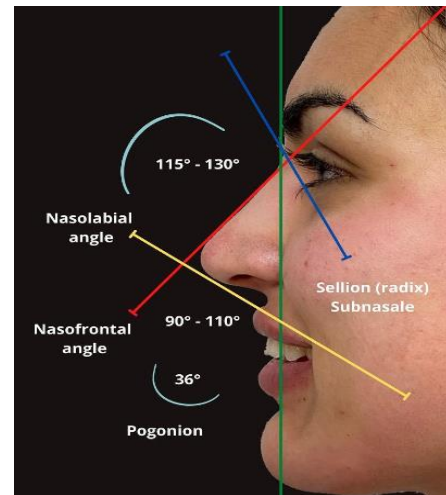


Figure 4. Aesthetic facial harmony ideal angles

Discussion

Rhinoplasty is a surgical process to reshape the nasal skeleton which results in changed underlying structures so that the form and function of the nose will improve. Most rhinoplasty surgeries are performed to improve nose appearance for cosmetic reasons, whether reducing nose size, projection, altering shape, smoothing a hump, adding volume to a flat bridge, or altering size and shape of overlarge nostrils. Facial beauty is related to balance and the symmetry of different parts of the face, including the nose and the premaxilla. As the nose as the premaxilla, in the frontal view, are important regions that constitute. The midface region and play an important role in aesthetic facial appearance.^{9,10} The premaxilla is the region between the maxillary incisor fissures consisting of the anterior central maxilla and overlying soft tissues.¹¹ It extends from the inferior edge of the maxilla to the base of the columella.

To achieve aesthetic facial harmony there are ideal angles we work towards achieving, though these must be treated as guides & ultimately the result will be determined by the patient goals. The premaxilla needs to be at or slightly ahead of a vertical line drawn from the pogonion.

Premaxillary augmentation is an excellent adjunct for rhinoplastic techniques and can enhance the profile harmony, a goal of both rhinoplasty and genioplasty.¹²

It improved nasal projection, addresses the nasal base, upper lip, and nasolabial angle; it offers a solution as an important adjunct to rhinoplasty, for excessive Gingival exposure and for Retrusion of the premaxilla, a common problem in facial plastic surgery, affecting both the profile and frontal views. Premaxillary augmentation may be achieved with surgical implants.¹³ These may be classified as autografts, homografts, and alloplasts. Many different implants are available for nasal reconstruction including Proplast, cartilaginous autografts, and osseous autografts, among others, each with varying degrees of success, but above all the use of a bat shaped Silastic (Implantech, Ventura, California) or Silastic sheets implant was discussed, and the merits of its excellent aesthetic outcomes highlighted. However, no ideal implant currently exists. Implants may also be inserted over the central upper lip anterior to the maxilla to achieve maxillary augmentation in combination with the aforementioned changes to nasal appearance. Caronni was the first to describe the use of a Silastic implant in correcting the nasolabial angle, as well as pointing out its utility as a rhinoplasty adjunct.¹⁴ The implant used in our case report is made of Silastic sheet. A silastic sheet (silicone elastomer: Polydimethyl Siloxane, Dow Corning Ltd, Midland, MI) is silicone that is strengthened with a Dacron mesh and has tensile strength and elasticity over a relatively large area. These implants may be placed strategically into various anatomic sites to achieve different cosmetic goals. Implants may be placed between the anterior maxillary spine and the posterior

end of the medial crura as a plumping graft to enhance nasal projection and to improve the nasolabial angle. Alternatively, a columellar strut may be inserted to increase projection, provide more structural support, and possibly alter the columellar-alar relationship. These implants may be inserted via many different incisions. For example, a plumping graft may be inserted via an intranasal incision, external rhinoplasty incision, or sublabial incision. For The surgical technique for Premaxillary augmentation using the silastic sheet implant can be approached either intranasally or intraorally.

1. *Intranasal approach*

A generous 1.5 cm incision is made in the right nasal vestibule. The incision begins vertically, runs behind the caudal part of the columella, then continues horizontally along the floor of the right vestibule. The incision is deepened to the bone of the nasal spine. A subperiosteal elevator is then used to dissect left and right tracts along and beneath the alar bases, extending a few millimeters beyond the bases laterally and inferiorly. The right pocket is held open with a Senn retractor, while the right end of the implant is introduced with an Adson-Brown forceps. The same procedure is then repeated on the left side. The central body is inspected to ensure a central position on the nasal spine. Closure is completed with two 4-0 chromic sutures.

2. *Intraoral approach*

A vertical midline incision is made in the superior gingival-buccal sulcus. At this point, the identical steps for dissection and implant insertion are carried out as previously stated. The native characteristics of Silastic make it the ideal choice when using a synthetic implant. Silastic is a readily available, biocompatible, easily shaped, easily removable, and inexpensive material. Surgeons have used it widely to reconstruct a defect in bone, cartilage, and connective tissue after trauma, inflammation, and tumor but it is subject to displacement and infection. However, several complications of the silastic sheet have been reported. These are: adhesion.¹⁷

In addition, displacement and migration, as in our case, has also been reported. In rhinoplasty surgery, grafting has become the most widely used technique

as well as suture techniques, it is widely regarded as one of the more technically challenging surgeries, owing in part to the many possible short- and long-term complications that can arise.¹⁶ However, complications fall into two categories: aesthetic and nonaesthetic. Of the nonaesthetic complications, infection has the widest span of severity.¹⁸ In this case the patient arrived with a periodontitis disease. Periodontitis is one of the most common diseases associated with the oral cavity. Periodontitis is a disease of the tissue surrounding the tooth structure. The disease is affected by both local as well as systemic etiological factors. All the cases of gingivitis do not progress into cases of periodontitis as it depends on the host response. Periodontitis can be broadly classified into chronic and aggressive periodontitis. Cases of chronic periodontitis (CP) are associated with a plethora of plaque and calculus. While the characteristic feature of aggressive periodontitis (AgP) is the familial aggregation of disease, increased amount of periodontal destruction with minimal local factors. AgP further classifies as local aggressive periodontitis (LAP) and generalized aggressive periodontitis (GAP). Gingivitis is the initial stage of the response of the body towards local factors present in the oral cavity; this is a reversible process without the loss of any bone or periodontal support. There are three histopathological stages of gingivitis: initial lesion, early lesion, and established lesion. Further inflammatory changes in the gingiva lead to the establishment of periodontal disease by the transition of the established stage to the advanced stage. The spread of inflammation from epithelium to connective tissue takes place laterally and apically resulting in the destruction of collagen fibers. This destruction of collagen fibers presents clinically as "attachment loss" marking the shift from gingivitis to periodontitis. In rhynoplastic Infection this is the most common complication that always warrants thread removal, and the main risks of autogenous transplants are dislocation and resorption, while alloplasts can cause infection and extrusion.¹⁹ In this respect silicone implants can have a complication rate between 5-20%. Gingivitis that is complicated on periodontitis can spoil tissue surrounding the tooth structure and make an infection of surgical implant used for rhinoplasty.²⁰ Infection can occur years after the initial procedure and alloplastic implant complications are the most

common reason for revision rhinoplasty above all in Asia.²¹⁻²² In this case, the silastic sheet was found adjacent to the incisor teeth during oropharyngoscopy to treat acute periodontitis. The authors do not know if the silastic sheet was the direct cause of the acute periodontitis or if the periodontitis creates the migration the infection and the extrusion of the implant. It is possible that the silastic sheet used in the previous rhinoplastic surgery reconstruction had migrated to the perimeter of the premaxilla and induced the chronic inflammation around the theet or more probably some conditions such as initially gengivitis, complicated on Periodontitis precipitated the acute purulent inflammation of the parodontal tissue and followed by implant extrusion, foreign body reaction, and infection.²³ However, although there is a connection and a link in both options, there is some connection, further investigation will be needed to determine the mechanism in this case.

Conclusions

Initial management of an infected implant relies on early recognition of these signs and initiation of antibiotics are the mainstay of treatment.²¹ In rare circumstances, an alloplastic implant may be salvaged with early aggressive antibiotic therapy, but surgical removal is almost always necessary.

In this case we show how a periodontitis can destroy periodontal tissues and create an extrusion of silastic implant, so a copious irrigation with

Rifampicina and antibiotic therapy and was useful not to get safe the implant, but to help the

1 factor, as well as the bacterial load of periodontopathogens, require reduction along with the correction of behavioral factors such as cessation of smoking and tobacco consumption is a part of periodontal treatment.

Declarations

Conflict of interest and financial disclosure

The author declares that he has no conflict of interest and there was no external source of funding for the present study. None of the authors have any relevant financial relationship(s) with a commercial interest.

Ethical approval

Research protocol was approved by the local Ethical Committee (2018/23) and in accordance with those of the World Medical Association and the Helsinki Declaration.

Informed consent

Informed consent was obtained from all individual participants included in the study.

Source of Funding

Non funding.

Availability of Data and Materials

Not applicable.

REFERENCES

1. Deva AK, Merten S, Chang L. Silicone in nasal augmentation rhinoplasty: a decade of clinical experience. *Plast Reconstr Surg.* 1998;102(4):1230-7. doi:10.1097/00006534-199809040-00052
2. Rohrich RJ, Hoxworth RE, Kurkjian TJ. The role of the columellar strut in rhinoplasty: indications and rationale. *Plast Reconstr Surg.* 2012;129(1):118e-125e. doi:10.1097/PRS.0b013e3182362b7a
3. Davis PK, Jones SM. The complications of silastic implants. Experience with 137 consecutive cases. *Br J Plast Surg.* 1971;24(4):405-11. doi:10.1016/s0007-1226(71)80099-1

4. Mottura AA. Short Columella Nasolabial Complex in Aesthetic Rhinoplasty. *Aesth. Plast. Surg.* 2001;25:266–272. doi:10.1007/s002660010134
5. Lawson W, Reino AJ, Seidman D. The silicone columellar strut. *Plast Reconstr Surg.* 1996;97(5):938-43. doi:10.1097/00006534-199604001-00008
6. Sertel S, Venara-Vulpe II, Pasche P. Correction of severe columella and tip retraction in silicone implanted Asian short noses. *J of Otolaryngol - Head & Neck Surg.* 2016;45:19. doi:10.1186/s40463-016-0131-9
7. Zarem HA. Silastic Implants in Plastic Surgery. *Surgical Clinics of North America.* 1968;48(1):129–142. doi:10.1016/s0039-6109(16)38440-7
8. Jung YG, Hong JW, Eun YG, Kim MG. Objective usefulness of thin silastic septal splints after septal surgery. *Am J Rhinol Allergy.* 2011;25(3):182-5. doi:10.2500/ajra.2011.25.3584
9. Jeong JY, Kwon H, Piao Y, Oh AH. A New Method for Stabilizing the Columellar Strut Used in Rhinoplasty: The Trans - Septal Columellar Stabilizing Suture. *Journal of Oral and Maxillofacial Surgery.* 2018;76(1):165-168. doi:10.1016/j.joms.2017.07.145
10. Kim WS, Kim CH, Yoon JH. Premaxillary augmentation using autologous costal cartilage as an adjunct to rhinoplasty. *J Plast Reconstr Aesthet Surg.* 2010;63(9):e686-90. doi:10.1016/j.bjps.2010.04.007
11. Fanous N, Yoskovitch A. Premaxillary augmentation for central maxillary recession: an adjunct to rhinoplasty. *Facial Plast. Surg. Clin. North. Am.* 2002;10(4):415-22. doi:10.1016/s1064-7406(02)00035-4
12. Fanous N, Yoskovitch A. Premaxillary augmentation for central maxillary recession: an adjunct to rhinoplasty. *MSc Surg.* 1995;53:412–417
13. Lin SJ. Premaxillary Augmentation Rhinoplasty. *Medscape.* 2023
14. Caronni EP. A new method to correct the nasolabial angle in rhinoplasty. *Plast Reconstr Surg.* 1972;50: 338 – 40. doi:10.1097/00006534-197210000-00004
15. Gregory GF. Silicone-associated tissue reaction: a dilemma for oral and maxillofacial surgeons. *Br J Oral Maxillofac Surg.* 1995;33:180–184. doi:10.1016/0266-4356(95)90294-5
16. Morrison AD, Sanderson RC, Moos KF. The use of silastic as an orbital wall defect: review of 311 cases treated over 20 years. *J Oral Maxillofac.* 1995;53(4):412-7. doi:10.1016/0278-2391(95)90714-9
17. Marone P, Perversi L, Monzillo V, et al. Ocular infections: antibiotics and bacterial adhesion on biomaterials used in ocular surgery. *Ophthalmologica.* 1995;209:315–318. doi:10.1159/000310649
18. Holt GR, Garner ET, McLarey D. Postoperative sequelae and complications of rhinoplasty. *Otolaryngol Clin North Am.* 1987;20(4):853-76
19. Orhan KS, Yilmazer AB. The use and possible complications of graft materials in rhinoplasty. *Kulak Burun Bogaz Ihtis Derg.* 2013;23(4):201-6. doi:10.5606/kbbihtisas.2013.59852
20. Chen DS, Wang TD. Management of Dorsal Graft and Implant Infections. *Facial Plast Surg.* 2020;36(1):24-27. doi: 10.1055/s-0040-1701489
21. Won TB, Jin HR. Revision rhinoplasty using autologous rib cartilage in Asians. *Plast Aesthet Res.* 2019;6:6
22. Won TB, Jin HR. Immediate reconstruction with autologous cartilage after removal of infected alloplast in revision rhinoplasty. *Otolaryngol Head Neck Surg.* 2012;147(06):1054–1059. doi:10.1177/0194599812459026
23. Rettinger G. Risks and complications in rhinoplasty. *GMS Curr Top Otorhinolaryngol Head Neck Surg.* 2007;6:Doc08

ՕԴՈՆՏՈՍՏՈՄԱՏՈԼՈԳԻԱՅԻ ՀԱՉԱՎԱԳԵՊ ԲԱՐԴՈՒԹՅՈՒՆ ԿՎՊՎԱԾ ՔՌԱՅԻՆ ՍԻԼԱՍՏԱՍՏԻՆ ԹԻԹԵՂԻ ՀԵՏ

Ֆրանչեսկո Լիտա,¹ Լյուսիա Մեմե,³ Ֆիլիպո Գրիլի,¹ Էնցո Յակոմինո,¹ Ֆրատինի Կիարա,² Ֆարրիցիո Բամբինի,³ Ստեֆանո Մումոլո¹

- ¹ Կյանքի, առողջության և շրջակա միջավայրի գիտությունների բաժին, Università degli Studi dell'Aquila, 67100 L'Aquila, Իտալիա
- ² Չգայական օրգանների բաժին, Հռոմի Սապիենցա համալսարան, Viale del Policlinico 155, 00186, Հռոմ, Իտալիա
- ³ Կլինիկական գիտությունների և ստոմատոլոգիայի ամբիոն, Մարկեի պոլիտեխնիկական համալսարան, Անկոնա, Իտալիա

Ամփոփում

Սիլաստիկը սիլիկոնային էլաստոմերի տեսակ է, որը լայնորեն օգտագործվում է տարբեր բժշկական կիրառություններում: Նրա հայտնի կիրառություններից մեկը էսթետիկ բժշկության մեջ է, մասնավորապես որպես իմպլանտ քթի մեջ՝ արտաքին տեսքը բարելավելու համար: Էքստրուզիայի, վարակի և միգրացիայի հնարավոր բարդությունները նվազագույն են, եթե իմպլանտը տեղադրվի առանձին անջրանցիկ խցիկում, առանց լարվածության փակման և առանց քթի գմբեթի ներթափանցման: Այս դեպքի զեկույցում հիվանդը ժամանել է պարոդոնտիտի հիվանդությամբ, և սուր պարոդոնտիտը բուժելու համար օրոֆարինգոսկոպիայի ընթացքում հայտնաբերվել է կտրող ատամների մոտ գտնվող սիլաստիկ թերթիկը: Հեղինակները չգիտեն, թե արդյոք սիլաստիկ թաղանթն է եղել սուր պարոդոնտիտի անմիջական պատճառը, թե՞ պարոդոնտիտը առաջացնում է միգրացիան՝ վարակը և իմպլանտի արտամղումը: Հնարավոր է, որ նախորդ ռինոլաստիկ վիրաբուժության վերականգնման ժամանակ օգտագործված սիլաստիկ թիթեղը տեղափոխվել է պրեմաքսիլայի պարագիծ և առաջացրել ատամների շուրջ քրոնիկական բորբոքում կամ, հավանաբար, որոշ պայմաններ, ինչպիսիք են սկզբնական զինգիվիտը, պարոդոնտիտով բարդացած, առաջացրել է ատամների սուր թարախային բորբոքում: պարոդոնտալ հյուսվածք, որին հաջորդում է իմպլանտի արտամղումը, օտար մարմնի ռեակցիան և վարակը:

РЕДКОЕ ОДОНТОСТОМАТОЛОГИЧЕСКОЕ ОСЛОЖНЕНИЕ, СВЯЗАННОЕ С ВЫВИЖОМ СИЛАСТИЧНОЙ НАЗАЛЬНОЙ ШИНЫ: СЛУЧАЙ СЛУЧАЯ

Франческо Литта,¹ Лючия Меме,³ Филиппо Грилли,¹ Энцо Якомино,¹ Фратини Кьяра,² Фабрицио Бамбини,³ Стефано Муммоло¹

- ¹ Факультет наук о жизни, здоровье и окружающей среде, Университет дельи Студи дель Аквила, 67100 Л'Аквила, Италия
- ² Кафедра органов чувств, Римский университет Сапиенца, Viale del Policlinico 155, 00186, Рим, Италия
- ³ Кафедра клинических наук и стоматологии, Политехнический университет Марке, Анкона, Италия

Аннотация

Силастик — это тип силиконового эластомера, который широко используется в различных медицинских целях. Одно из его популярных применений — в эстетической медицине, в частности, в качестве имплантата в нос для улучшения его внешнего вида. Потенциальные осложнения, связанные с экструзией, инфицированием и миграцией, минимальны, если имплантат размещается в отдельном отофарингоскопии при лечении острого пародонтита рядом с резцами был обнаружен силосный лист. Авторы не знают, был ли

силиконовый лист непосредственной причиной острого пародонтита или пародонтит вызывает миграцию инфекции и выдавливание имплантата. Возможно, что силиконовый лист, использованный в предыдущей реконструкции ринопластической операции, мигрировал по периметру предчелюстной кости и вызвал хроническое воспаление вокруг зубов или, что более вероятно, некоторые состояния, такие как первоначальный гингивит, осложненный пародонтитом, спровоцировали острое гнойное воспаление верхней челюсти. ткани пародонта с последующей экструзией имплантата, реакцией на инородное тело и инфекцией.

DOI: 10.58240/1829006X-2023.19.4-91



CASE REPORT

FAMILIAL FOURTH MOLARS IN NON-SYNDROMIC PATIENTS: CASE REPORT OF AN UNUSUAL ENTITY

Lourimar de Moura Moreira DDS, MD, MSc,^{1,2} Ricardo Grillo DDS, MBA, MSc,^{3*}
Jeová Clementino de Almeida Júnior DDS, MSc,² Rubens Gonçalves Teixeira DDS, PhD²

¹ Department of Oral & Maxillofacial Surgery, Hospital Santa Casa de Curitiba, Curitiba, Brazil

² Department of Oral & Maxillofacial Surgery, Faculdade São Leopoldo Mandic, Campinas, Brazil

³ Department of Oral & Maxillofacial Surgery, Faculdade Planalto Central, Brasília, Brazil

* Corresponding author: Ricardo Grillo Orcid: 0000-0002-8096-738X Faculdade Planalto Central, Brasília-DF/Brazil, SIA trecho 8 lote 70/80; ZIP Code: 71205-020 Brazil; Phone: +55 61 3323-6109; e-mail: doutorgrillo@uol.com.br

Received: Oct. 2, 2023; **Accepted:** Oct. 27, 2023; **Published:** Nov. 5, 2023

Abstract

Objectives: This work aims to report an unusual case of fourth molars in three patients from the same family.

Case Report: The patient underwent third and fourth molars removal with little morbidity. Some important aspects were discussed, in particular the use of piezosurgery. Important features of the classification and epidemiology of distomolars and paramolars were discussed. The authors believe this to be the first report of familial fourth molars.

Conclusions: Although considered a rare condition, fourth molars can be treated as an unusual or uncommon condition. The term rare is not appropriate to this situation and the authors debate it. Piezosurgery is very harmful in extensive osteotomies to remove third and/or fourth molars.

Keywords: Molar, Third; Tooth, Supernumerary; Surgery, Oral; Toothache

Introduction

Third molar surgery is always on the up. This topic is of interest to general dentists, oral surgeons, and researchers. The number of publications on third molar surgery is increasing and must continue for years.¹

The same is not true for fourth molars. Due to the lower incidence, fewer than 50 articles published and indexed on Pubmed are available over the years.

Because of the very small number of publications, some questions about this entity arise. The main

questions relate to the most appropriate surgical technique, classification, and epidemiology.² These findings regarding supernumerary teeth can be performed worldwide with significant results. In the case of distomolars, these results can be falsified by meaningless numbers. Especially in the context of some syndromes, the occurrence of distomolars in non-syndromic patients is even more unusual.

This article aims to report a case of a non-syndromic patient with four impacted distomolars. Although an uncommon entity, a familial occurrence of distomolars makes this report unique. Three female

family members with the same unusual condition. Some aspects of the use of the term “rare condition” and surgical technique were discussed.

Case Report

An 18-year-old female patient presented to our private practice with recurrent pericoronitis. In the medical history, the patient reported that she was referred by another oral surgeon because of technical issues related to the third molar surgery. No comorbidity was reported. Four impacted fourth molars could be observed on the panoramic radiograph (figure 1).

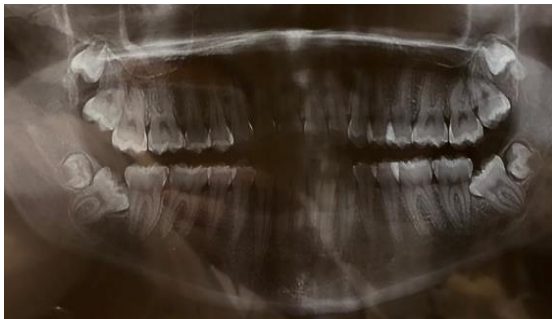

Figure 1. Panoramic radiography. Note four third molars and four distomolars

The mother underwent four different. In the anamnesis, the patient’s mother said that she had had a similar situation. The mother underwent four distinct surgeries to remove her third and fourth molars about 15 years ago. It was the request of the patient and caregivers to remove both the third and fourth molars under sedation and local anesthesia.

A preemptive medication consisting of 1g amoxicillin, 8mg dexamethasone, and 1g dipyrone was administered one hour before the operation. The patient underwent third and fourth molar removal under general anesthesia. Due to the size of the impacted teeth, a regular osteotomy was performed with a major lengthening required. Piezosurgery was used for the osteotomy and a conventional rotary drill for the odontosection. The eight teeth were extracted without difficulty in about 90 minutes.

After six days the patient presented with mild edema and trismus (figure 2), with no evidence of infection.

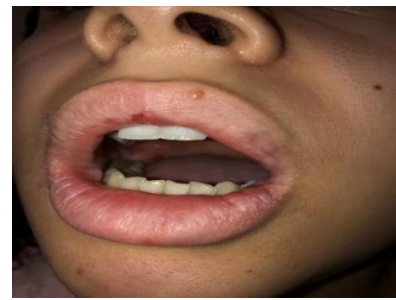

Figure 2. Trismus after teeth extraction

The suture has been removed. Two weeks after the operation, the patients have no trismus and no pain. Second panoramic radiography was taken to accompany the case (figure 3). Although the surgeon requested the anterior panoramic X-rays from those in charge, no examination was found.

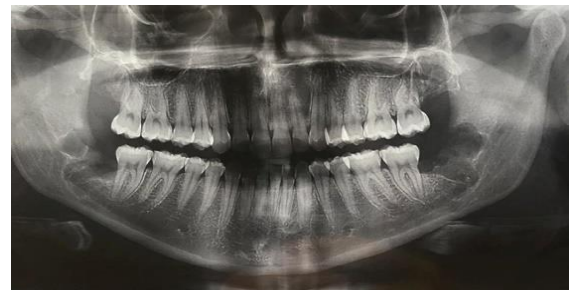

Figure 3. Panoramic radiography after tooth extraction

At the return consultation, the patient’s sister also reported panoramic radiography showing four distomolars. This third patient has refused to cooperate in the present report and the parents have not consented to the publication of the images because the patient is a minor.

Discussion

The most commonly used classification of supernumeraries was made by Bolk in 1914.³ The author has divided the fourth molars into distomolars and paramolars. Any tooth located behind the third molar, regardless of its format, is called a distomolar. A paramolar is any tooth that is in the molar region and has significant anatomical changes. In our case, four distomolars were removed from the patient. None of the patients was syndromic.

The removal of supernumerary teeth must be carried out independently of the affected region after a risk/benefit assessment.² Common complaints of impacted molars include recurrent pericoronitis, unrecoverable tooth decay, and orthodontic or prosthetic purposes. As in our case, about 33% of the removals of third molar are due to recurrent pericoronitis.⁴

Supernumerary teeth have an incidence of about 0.5% to 1% in some articles and reach a maximum of 2 or 3%.^{2,5} The incidence of distomolars is extremely low, around 0.02%.⁶ Mandibular distomolars have a lower incidence than maxillary distomolars. There is no dominance between the sexes in the literature.⁵ The definition of a disease as a rare condition depends on the regulations of different countries, there is no universal protocol. Most countries define a rare disease as 1/2,000 patients ($p=0.0005\%$).⁷ Although there is no universal protocol, fourth molars cannot be treated as a rare disease. A common entity might be a more appropriate definition.

Piezosurgery is developing more and more into an efficient surgical technique. Although it has some disadvantages like longer uptime and cost, the advantages outweighed the disadvantages. Piezosurgery is associated with a significant reduction in the incidence of edema, trismus, and pain.⁸ The number of analgesics taken is lower compared to conventional rotary instruments.⁹ In the case of extensive osteotomies, as in the present case, the authors consider piezosurgery to be mandatory.

Conclusions

We presented the first case of four familial distomolars in nonsyndromic patients. Distomolars cannot be treated as rare entities. Although the incidence is very low, ideally the fourth molar can be treated as a common or unusual entity. In extensive osteotomies, piezosurgery is mandatory to reduce edema, pain, and trismus.

Declarations

Conflict of interest and financial disclosure

The author declares that he has no conflict of interest and there was no external source of funding for the present study. None of the authors have any relevant financial relationship(s) with a commercial interest.

Ethical approval

Research protocol was approved by the local Ethical Committee (2018/23) and in accordance with those of the World Medical Association and the Helsinki Declaration.

Informed consent

Informed consent was obtained from all individual participants included in the study.

Source of Funding

Non funding.

Availability of Data and Materials

Not applicable.

REFERENCES

1. Balel Y. Bibliometric analysis of international publication trends in impacted third molar surgery research (2000–2020). *Br J Oral Maxillofac Surg.* 2021;59(10):1220–1226. doi:10.1016/j.bjoms.2021.04.003
2. Shahzad KM, Roth LE. Prevalence and management of fourth molars: A retrospective study and literature review. *J Oral Maxillofac Surg.* 2012;70(2):272–5. doi:10.1016/j.joms.2011.03.063
3. Bolk L. Supernumerary teeth in the molar region in man. *Dent Cosm.* 1914;56:154–67. doi:10.1136/bcr-2014-205000

Moreira LM, Grillo R, de Almeida Júnior JC, Gonçalves Teixeira R. Familial Fourth Molars In Non-Syndromic Patients: Case Report Of An Unusual Entity. *Bulletin of Stomatology and Maxillofacial Surgery.* 2023;19(4):91-95. doi: 10.58240/1829006X-2023.19.4-91

4. Patel S, Mansuri S, Shaikh F, Shah T. Impacted Mandibular Third Molars: A Retrospective Study of 1198 Cases to Assess Indications for Surgical Removal, and Correlation with Age, Sex and Type of Impaction-A Single Institutional Experience. *J Maxillofac Oral Surg.* 2017;16(1):79–84. doi:10.1007/s12663-016-0929-z
5. Ohata H, Hayashi K, Iwamoto M, et al. Three cases of distomolars. *Bull Tokyo Dent Coll.* 2013;54(4):259–64. doi:10.2209/tdcpublication.54.259
6. Costantino A, Fonseca GM, Cantín M. Bilateral mandibular fourth molars: A case report. *Rev Stomatol Chir Maxillofac Chir Orale.* 2015;116(5):312–4. doi:10.1016/j.revsto.2015.05.001
7. Richter T, Nestler-Parr S, Babela R, et al. Rare Disease Terminology and Definitions — A Systematic Global Review: Report of the ISPOR Rare Disease Special Interest Group. *Value Heal.* 2015;18(6):906–14. doi:10.1016/j.jval.2015.05.008
8. Silva LD, Reis EN, Bonardi JP, Lima VN, Aranega AM, Ponzoni D. Influence of surgical ultrasound used in the detachment of flaps, osteotomy and odontosection in lower third molar surgeries. A prospective, randomized, and “split-mouth” clinical study. *Med Oral Patol Oral Cir Bucal.* 2020;25(4):e461–7. doi:10.4317/medoral.23447
9. Al-Moraissi EA, Elmansi YA, Al-Sharaee YA, Alrmali AE, Alkhutari AS. Does the piezoelectric surgical technique produce fewer postoperative sequelae after lower third molar surgery than conventional rotary instruments? A systematic review and meta-analysis. *Int J Oral Maxillofac Surg.* 2016;45(3):383–91. doi:10.1016/j.ijom.2015.10.005

ԸՆՏԱՆԵԿԱՆ ՉՈՐՐՈՐԴ ՄՈՒԱՐՆԵՐ ԱՆՍԻՆԴՐՈՍ ՀԻՎԱՆԳՆԵՐԻ ՄՈՏ. ԱՆՍՈՎՈՐ ԴԵՊՔԻ ՆԿԱՐԱԳՐՈՒԹՅՈՒՆ

Լուրիմար դե Մոուրա Մորեյրա,^{1,2} Ռիկարդո Գրիլլո,³ Գեովա Կլեմենտինո դե Ալմեյդա,² Ռուբենս Գոնսալվես Տեյշեյրա²

- ¹ Բերանի և դիմաձնոտային վիրաբուժության բաժանմունք, Սանտա Կասա դե Կուրիտիբա հիվանդանոց, Կուրիտիբա, Բրազիլիա
- ² Բերանի և դիմաձնոտային վիրաբուժության բաժին, Սան Լեոպոլդո Մանդիչի ֆակուլտետ, Կամպինաս, Բրազիլիա
- ³ Բերանի և դիմաձնոտային վիրաբուժության բաժին, Պլանալտոյի կենտրոնական ֆակուլտետ, Պլանալտո, Բրազիլիա

Ամփոփում

Նպատակ. Այս աշխատանքը նպատակ ունի զեկուցել չորրորդ մոլյարի արտասովոր դեպքի մասին նույն ընտանիքից երեք հիվանդների մոտ:

Դեպքի հաշվետվություն. հիվանդը ենթարկվել է երրորդ և չորրորդ մոլյարի հեռացման՝ քիչ հիվանդացությամբ: Զննարկվեցին մի քանի կարևոր ասպեկտներ, մասնավորապես՝ պիեզովիրաբուժության կիրառումը: Զննարկվեցին դիստոմոլյարների և պարամոլյարների դասակարգման և համաճարակաբանության կարևոր առանձնահատկությունները: Հեղինակները կարծում են, որ սա ընտանեկան չորրորդ մոլյարների առաջին զեկույցն է:

Եզրակացություն. Թեև համարվում է հազվագյուտ վիճակ, չորրորդ մոլյարները կարող են դիտարկվել որպես անսովոր կամ հազվադեպ վիճակ: Հազվադեպ տերմինը չի համապատասխանում այս իրավիճակին,

և հեղինակները քննարկում են այն: Պիեզոփիրարուժությունը շատ վնասակար է լայնածավալ օստեոտոմիաներում երրորդ և/կամ չորրորդ մոլյարները հեռացնելու համար:

СЕМЕЙНЫЕ ЧЕТВЕРТЫЕ МОЛЯРЫ У НЕСИНДРОМНЫХ ПАЦИЕНТОВ: ОПИСАНИЕ НЕОБЫЧНОГО СЛУЧАЯ

Луримар де Моура Морейра,^{1,2} Рикардо Грилло,³ Жеова Клементино де Алмейда Младший,² Рубенс Гонсалвес Тейшейра²

¹ Отделение челюстно-лицевой хирургии, больница Санта-Каса-де-Куритиба, Куритиба, Бразилия

² Отделение челюстно-лицевой хирургии, факультет Сан-Леопольдо Мандич, Кампинас, Бразилия

³ Отделение челюстно-лицевой хирургии, Центральный факультет Планалто, Планалто, Бразилия

Абстракт

Цель: Целью данной работы является сообщение о необычном случае появления четвертых моляров у трех пациентов из одной семьи.

История болезни: Пациенту удалили третьи и четвертые моляры с небольшими осложнениями. Обсуждались некоторые важные аспекты, в частности использование пьезохирургии. Обсуждены важные особенности классификации и эпидемиологии дистомоляров и парамоляров. Авторы полагают, что это первое сообщение о семейных четвертых молярах.

Выводы: Несмотря на то, что четвертые моляры считаются редким заболеванием, их можно рассматривать как необычное или редкое заболевание. Термин «редкий» не подходит для данной ситуации, и авторы спорят по этому поводу. Пьезохирургия очень вредна при обширных остеотомиях по удалению третьих и/или четвертых моляров.

DOI: 10.58240/1829006X-2023.19.4-96



ORIGINAL ARTICLE

**COMPLEX TREATMENT OF INTERNAL TMJ DISORDERS IN PATIENTS WITH
DIFFERENT BIT TYPES**

Boris Gharamanyan,* Tina Chkhikvadze, Valery Bekreev

Department of Surgical Dentistry and Maxillofacial Surgery, Peoples Friendship University of Russia, Moscow, Russian Federation

* Corresponding author: Boris Gharamanyan, Peoples Friendship University of Russia, Moscow, Russian Federation;

e-mail: bgaramyan@gmail.com

Received: Oct. 2, 2023; **Accepted:** Oct. 27, 2023; **Published:** Nov. 5, 2023

Abstract

Objective: To assess the impact of physiological and pathological types of occlusions on the effectiveness of the treatment of patients with internal disorders of the TMJ.

Material and Methods: A comprehensive examination and treatment of 139 patients with internal TMJ disorders with subluxation and chronic dislocation of the articular disc was carried out. The patients were divided into three groups. All groups included patients with both physiological and pathological occlusion. The first group included 28 (20.1%) patients who were treated only with occlusal splint therapy; the second group included 95 (68.3%) patients who were treated with a combination of occlusal splint therapy and the use of arthrocentesis; in the third group (16 people (11.5%), along with splint therapy and arthrocentesis, TMJ arthroscopy was performed. The examination included a survey and examination of patients, a study of diagnostic models of the jaws to determine the types of occlusion and occlusal contacts, magnetic resonance imaging (MRI) and ultrasound examination (ultrasound) of the TMJ. Patients underwent a phased treatment, including occlusive splint therapy (stage I); with insufficient effectiveness - occlusive splint therapy and arthrocentesis (stage II); occlusive splint therapy and arthrocentesis in combination with arthroscopy (stage III of treatment).

Results: As a result of the study, it turned out that the groups of patients differed significantly in the complexity and duration of the treatment. Thus, in patients with internal TMJ disorders and pathological type of occlusion, in 82.6% of cases, additional use of arthrocentesis was required and in 34.8% - arthroscopy (95 patients out of 139), while patients with physiological types of occlusions (orthognathic, prognathic, biprognathic and direct) needed these treatments in 80.2% and 7.8% of cases, respectively. In the groups of patients, the duration of therapy, as well as the number of arthrocentesis performed in patients at the second and third stages of treatment, significantly differed. In the first group, the duration of treatment was 6.2 months for patients with normal occlusion and 8.7 ($p<0.01$) months for patients with pathological occlusion; additional methods of treatment (arthrocentesis and arthroscopy) were not used. In the second and third groups of patients, the duration of treatment for patients with occlusion pathology was also longer: in the second group 4.9 and 6.8 ($p<0.01$) months for patients with physiological and pathological types of occlusions, respectively, in the third group with the use of splint therapy, arthrocentesis and arthroscopy in patients with normal occlusion was 13.1 ($p<0.05$) months, and in patients with occlusion pathology 14.5 months.

Conclusion: Patients with internal TMJ disorders need a comprehensive examination for the timely detection of occlusion pathologies. The relationship between internal TMJ disorders and the type of occlusion must always be taken into account in the choice of further treatment tactics and therapy planning in order to achieve the best result.

Keywords: *internal temporomandibular joint disorders; occlusive dysfunction; bite type; occlusive splint therapy; arthrocentesis; arthroscopy*

Introduction

Pathology of the temporomandibular joint (TMJ) is an important problem in dentistry due to its wide prevalence and significant impact on the quality of life of patients.¹⁻³ In more than 70% of cases, according to recent studies, TMJ diseases are combined with impaired occlusion.⁴ Due to this frequency of occurrence of a combination of these pathologies, many authors believe that occlusion disorders can play an important role in the etiopathogenesis of TMJ diseases.^{5,6} One of the possible mechanisms was described by Savajani et al.⁷

According to these authors, the occurrence of occlusion disorders leads to compensatory asymmetry of muscle contraction and displacement of the mandibular heads. Because of this, the nerve endings of the joint capsule, posterior zones are subsequently injured, as well as a violation of the blood supply to the tissues, changes in the width of the joint space and the position of the articular disc. In addition, there is evidence that the violation of occlusion significantly complicates the course of TMJ disease.^{8,9}

On the other hand, the results of studies have been published in which no correlation was found between the incidence of TMJ pathologies and the number of occlusal disorders.¹⁰ Despite the fact that the etiology of internal disorders of the TMJ is multifactorial, ignoring the role of occlusion is incorrect in the treatment of patients with internal disorders of the TMJ.¹¹⁻¹⁴

Thus, due to the lack of complete clarity on this issue, we conducted a study whose purpose was to assess the impact of physiological and pathological types of occlusions on the effectiveness of the treatment of patients with internal disorders of the TMJ.

Material and Methods

A comprehensive examination and treatment of 139 patients with internal TMJ disorders with subluxation and chronic dislocation of the articular disc was carried out. The patients were divided into three groups. All groups included patients with both physiological and pathological occlusion. The first group included 28 (20.1%) patients who were treated only with occlusal splint therapy; the second group

included 95 (68.3%) patients who were treated with a combination of occlusal splint therapy and the use of arthrocentesis; in the third group (16 people (11.5%), along with splint therapy and arthrocentesis, TMJ arthroscopy was performed.

The groups of patients were comparable in gender and age. The exclusion criteria were patients who had previously undergone orthodontic and orthognathic treatment.

The examination included a survey and examination of patients, a study of diagnostic models of the jaws to determine the types of occlusion and occlusal contacts, magnetic resonance imaging (MRI) and ultrasound examination of the TMJ. Patients underwent a phased treatment, including occlusive splint therapy (stage I of treatment); with insufficient effectiveness - occlusive splint therapy and arthrocentesis (stage II of treatment); occlusive splint therapy and arthrocentesis in combination with arthroscopy (stage III of treatment).

After treatment with internal TMJ disorders, all patients underwent repeated MRI of the TMJ and ultrasound of the TMJ to assess the state of the joint. All patients with occlusion pathology underwent orthodontic or orthopedic treatment simultaneously with the treatment of internal TMJ disorders or after its completion.

Statistical processing of the obtained results was carried out using the software Statistica 8.0, the criterion for differences in the group was Student's t-test. Differences were considered significant at * - $p < 0.05$, ** - $p < 0.01$.

Results

As a result of the study, it turned out that the groups of patients differed significantly in the complexity and duration of the treatment. Thus, in patients with internal TMJ disorders and pathological type of occlusion, in 82.6% of cases, additional use of arthrocentesis was required and in 34.8% - arthroscopy (95 patients out of 139), while patients with physiological types of occlusions (orthognathic, progenic, biprogenic and direct) needed these treatments in 80.2% and 7.8% of cases, respectively (table 1).

Table 1: The number of patients with different types of occlusions at the stages of treatment

	Physiological types of bite				Pathological types of bite		
	I stage of treatment	II stage of treatment	III stage of treatment		I stage of treatment	II stage of treatment	III stage of treatment
Orthognathic	61	53	-	Deep	6	6	2
Progenic	39	28	5	Open	5	4	2
Biprogenic	11	7	-	Distal	3	2	2
Straight	5	5	4	Mesial	7	5	1
				Cross	2	2	1
Number of patients in % who required the use of arthropuncture and arthroscopy		80.2%	7.8%			82.6%	34.8%

In the groups of patients, the duration of therapy, as well as the number of arthrocentesis performed in patients at the second and third stages of treatment, significantly differed. In the first group, the duration of treatment was 6.2 months for patients with normal occlusion and 8.7 (p<0.01) months for patients with pathological occlusion; additional methods of treatment (arthrocentesis and arthroscopy) were not used. In the second and third groups of patients, the duration of treatment for patients with occlusion pathology was also longer: in the second group 4.9 and

6.8 (p<0.01) months for patients with physiological and pathological types of occlusions, respectively, in the third group with the use of splint therapy, arthrocentesis and arthroscopy in patients with normal occlusion was 13.1 (p<0.05) months, and in patients with occlusion pathology 14.5 months (figure 1).

The terms of treatment also depend on the type of physiological or pathological bite. On (figure 2) shows the treatment time for patients with various types of physiological and pathological occlusion.

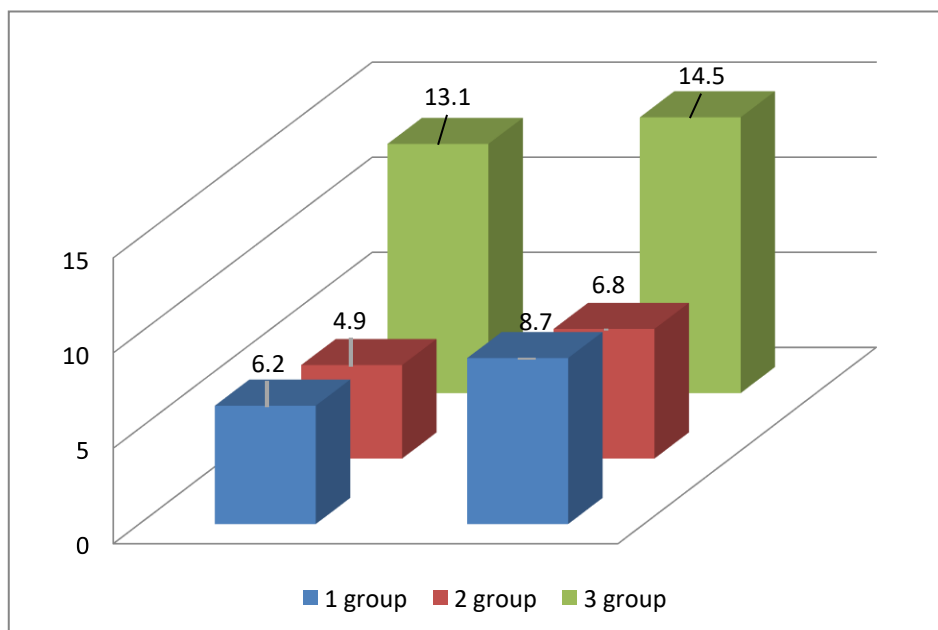


Figure 1. Terms of treatment of patients in all three groups with physiological types of bite pathological types of bite (in months)

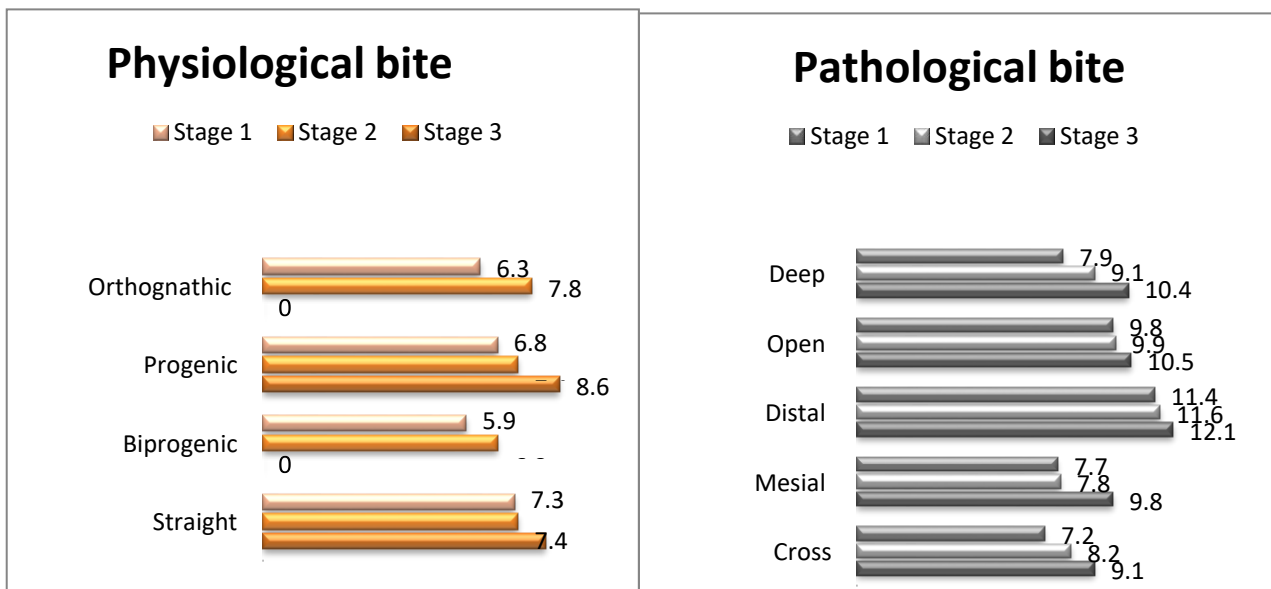


Figure 2. Terms of treatment of patients with internal TMJ disorders depending on the type of occlusion

At the first stage of treatment, only an occlusal splint was used. At the second and third stages of treatment, the number of necessary atrocentesis was required in patients with occlusion pathology significantly more than in patients with physiological occlusion (figures 3 and 4). On (figure 5) shows the

average number of required arthropunctures in patients with normal and pathological occlusion. In patients with pathological occlusion, an average of 14.95 more arthrocentesis was required to normalize the position of the articular disc.

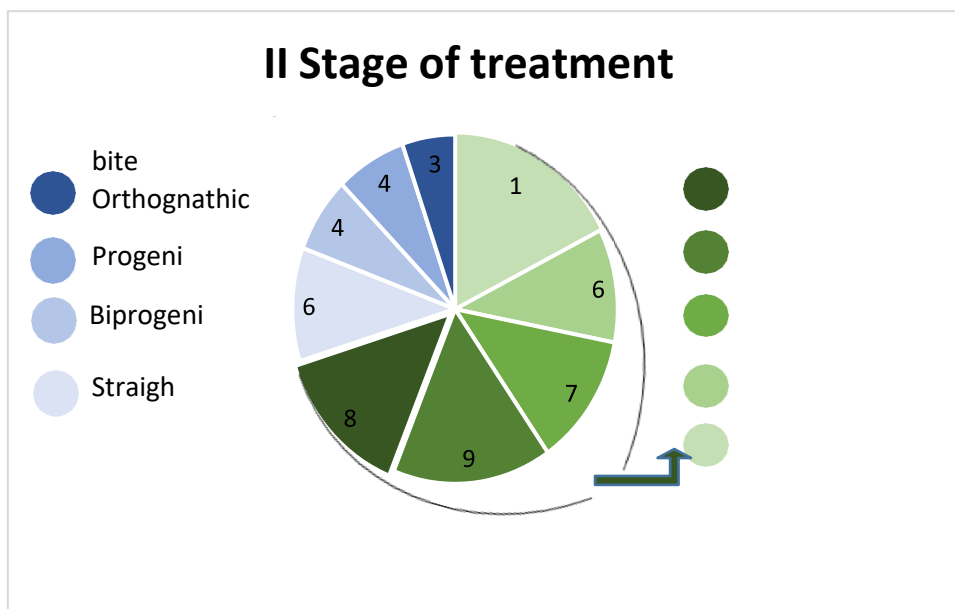


Figure 3. Number of arthrocentesis II stages of treatment in patients with different types of occlusions

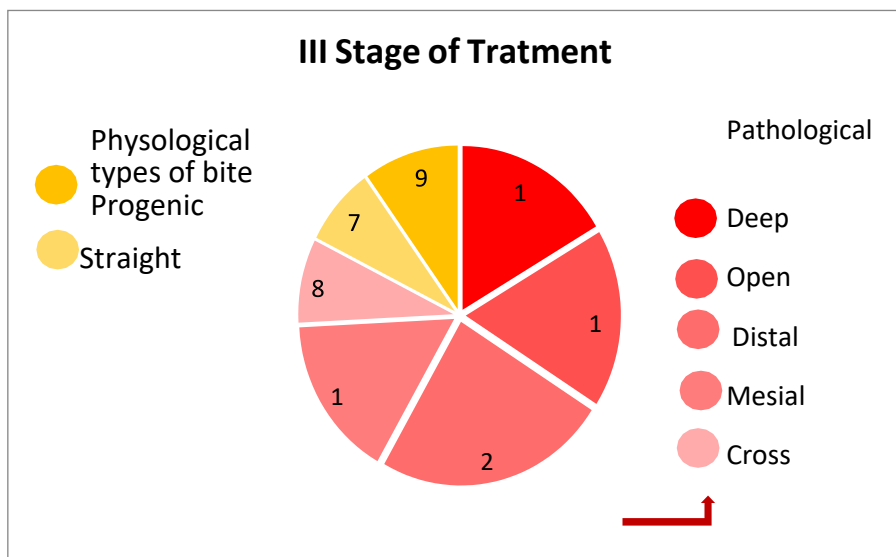


Figure 4. Number of arthrocentesis III stages of treatment in patients with different types of occlusions

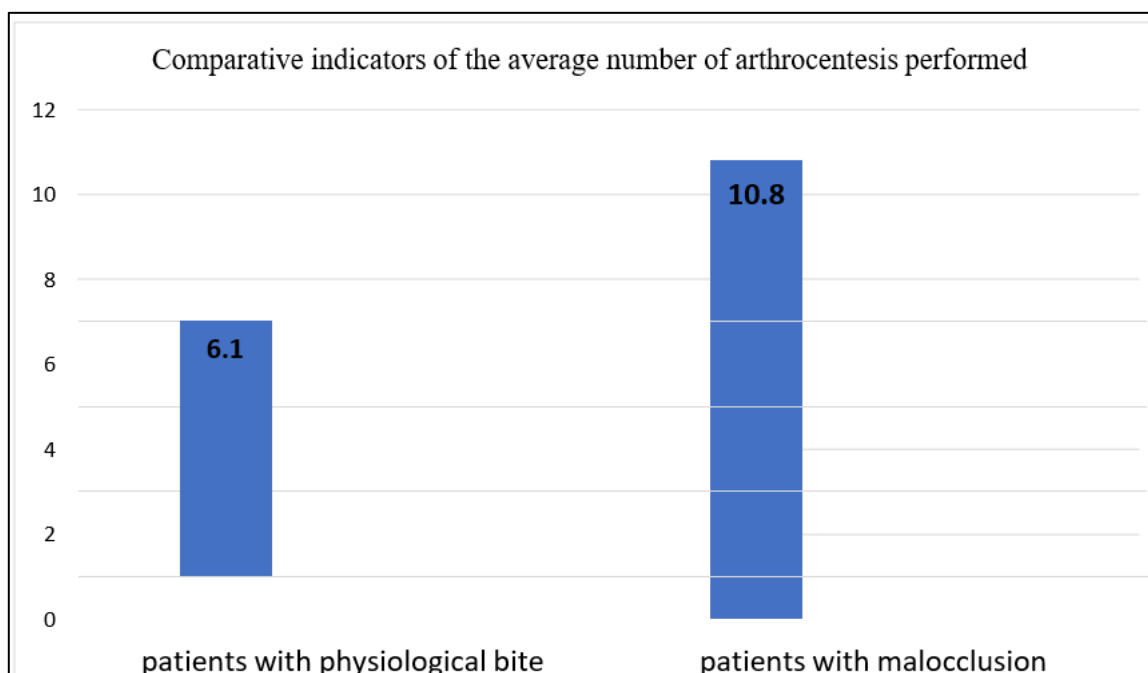


Figure 5. The average number of arthrocentesis performed in patients with physiological and pathological types of bite

Discussion

Internal disorders of the temporomandibular joint (TMJ) in most cases are combined with the presence of occlusion disorders in patients, TMJ diseases, or only occlusive disorders.^{15,16} However, it is known that the violation of occlusion can significantly complicate the course of TMJ disease, and incorrect treatment tactics lead to instability of the formed

occlusion and relapse of the disease.^{17,18} Since the diagnosis and treatment of TMJ remains a challenge, there is still no consensus on many aspects. An important part of the diagnosis of TMJ is the differential diagnosis from those clinically significant but unusual conditions that require urgent treatment. Depending on the type of TMJ, a variety of conservative treatment options and surgical

interventions are offered. It has been shown that the use of an occlusal splint reduces the intensity of pain and has a positive effect.¹⁹

In the case of an internal disorder, restoring the position of the disc is not the main goal of treatment, since it may not lead to clinical improvement.^{20,21} Nevertheless, the available literature does not show how strongly occlusive disorders influence the complexity of treatment of TMJ pathology and its duration. The effectiveness of arthroscopy in the management of internal derangement of the temporomandibular has been reported in many studies.^{22,23}

Arthrocentesis has been proposed which involves two puncture needles into the superior joint space guided by landmarks in relations to adjacent structures, followed by lavage with an irrigation solution.^{24,25}

At the moment, based on the data available in the scientific literature, it is impossible to unambiguously conclude which of the pathologies is primary and which is secondary, however, most authors support the idea that the pathological types of occlusions existing in the patient to greater or lesser extent affect the occurrence of internal TMJ disorders. Many cases of TMD are due to multiple etiologies, which requires a multimodal approach, and it is also necessary to evaluate the clinical improvement of the proposed methods.

In this work, we assessed several parameters: the total duration of treatment, the number of arthrocentesis and arthroscopy operations performed in patients with TMJ with pathological occlusion and in patients with physiological occlusion. It was revealed that patients with pathological occlusion require more complex and often longer therapy than patients with physiological occlusion. This must be taken into account when determining the treatment tactics and planning therapy to achieve the best result.

The type of occlusion is an important aspect in the treatment of internal TMJ disorders. The results of this

study clearly demonstrate that pathological types of occlusions significantly increase the duration of treatment for patients with internal TMJ disorders and often require the use of arthrocentesis and arthroscopy along with occlusal splint therapy.

Conclusion

Patients with internal TMJ disorders need a comprehensive examination for the timely detection of occlusion pathologies. The relationship between internal TMJ disorders and the type of occlusion must always be taken into account in the choice of further treatment tactics and therapy planning in order to achieve the best result.

Declarations

Conflict of interest and financial disclosure

The author declares that he has no conflict of interest and there was no external source of funding for the present study. None of the authors have any relevant financial relationship(s) with a commercial interest.

Ethical approval

Research protocol was approved by the local Ethical Committee (2018/23) and in accordance with those of the World Medical Association and the Helsinki Declaration.

Informed consent

Informed consent was obtained from all individual participants included in the study.

Source of Funding

Non funding.

Availability of Data and Materials

Not applicable.

REFERENCES

1. Li DTS, Leung YY. Temporomandibular Disorders: Current Concepts and Controversies in Diagnosis and Management. *Diagnostics (Basel)*. 2021;11(3):459. doi:10.3390/diagnostics11030459
2. List T, Jensen RH. Temporomandibular disorders: old ideas and new concepts. *Cephalalgia*. 2017;37:692–704. doi:10.1177/0333102416686302
3. Valesan LF, Da-Cas CD, Reus JC, et al. Prevalence of temporomandibular joint disorders: A systematic review and meta-analysis. *Clin. Oral Investig.* 2021;25(2):441-453. doi:10.1007/s00784-020-03710-w
4. Caldas W, Conti AC, Janson G, Conti PC. Occlusal changes secondary to temporomandibular joint conditions: a critical review and implications for clinical practice. *J Appl Oral Sci.* 2016;24(4):411-419. doi:10.1590/1678-775720150295
5. Haralur SB. Digital Evaluation of Functional Occlusion Parameters and their Association with Temporomandibular Disorders. *J. Clin. Diagn. Res.* 2013;7(8):1772–1775. doi:10.7860/JCDR/2013/5602.3307
6. Padala S, Padmanabhan S, Chithranjan AB. Comparative evaluation of condylar position in symptomatic (TMJ dysfunction) and asymptomatic individuals. *Indian J. Dent. Res.* 2012;23(1):122. doi:10.4103/0970-9290.99060
7. Savajani D, Wertheim D, Edler R. Change in cranio- cervical angulation following orthognatic surgery. *Eur. J. Orthod.* 2005;3(27):268-273. doi:10.1093/ejo/cji013
8. Al-Ani Z. Occlusion and Temporomandibular Disorders: A Long-Standing Controversy in Dentistry. *Prim. Dent. J.* 2020;9(1):43-48. doi:10.1177/2050168420911029
9. JAM de Kanter R, Pasquale GFCM Battistuzzi P, Truin GJ. Temporomandibular Disorders: “Occlusion” Matters! *Pain. Res. Manag.* 2018;2018:8746858. doi:10.1155/2018/8746858
10. Cordray F. The Relationship between Occlusion and TMD. *Open Journal of Stomatology.* 2017;07(01):35-8011. doi:10.4236/ojst.2017.71003
11. Sharma S, Gupta DS, Pal US, Jurel SK. Etiological factors of temporomandibular joint disorders. *Natl J Maxillofac Surg.* 2011;2(2):116-119. doi:10.4103/0975-5950.94463
12. Chisnoiu AM, Picos AM, Popa S, et al. Factors involved in the etiology of temporomandibular disorders - a literature review. *Clujul Med.* 2015;88(4):473-478. doi:10.15386/cjmed-485
13. Cordray F. The Relationship between Occlusion and TMD. *Open Journal of Stomatology.* 2017;07(01):35-8011. doi:10.4236/ojst.2017.71003
14. Ahmad M, Schiffman EL. Temporomandibular Joint Disorders and Orofacial Pain. *Dent Clin North Am.* 2016;60(1):105-124. doi:10.1016/j.cden.2015.08.004
15. Wilkes CH. Internal Derangements of the Temporomandibular Joint: Pathological Variations. *Arch. Otolaryngol. Head Neck Surg.* 1989;15:469-477. doi:10.1001/archotol.1989.01860280067019
16. Dzingutė A, Pileičikienė G, Baltrušaitytė A, Skirbutis G. Evaluation of the relationship between the occlusion parameters and symptoms of the temporomandibular joint disorder. *Acta Med Litu.* 2017;24(3):167-175. doi:10.6001/actamedica.v24i3.3551
17. Wang C, Yin X. Occlusal risk factors associated with temporomandibular disorders in young adults with normal occlusions. *Oral Surg Oral Med Oral Pathol Oral Radiol Endod.* 2012;114:419–23. doi:10.1016/j.oooo.2011.10.039

18. Zhang C, Wu JY, Deng DL, et al. Efficacy of splint therapy for the management of temporomandibular disorders: A meta-analysis. *Oncotarget*. 2016;7:84043–84053. doi:10.18632/oncotarget.13059
19. Al-Ani Z. Occlusion and Temporomandibular Disorders: A Long-Standing Controversy in Dentistry. *Prim. Dent. J.* 2020;9(1):43-48. doi:10.1177/2050168420911029
20. Kakudate N, Yokoyama Y, Sumida F, et al. Dentist Practice Patterns and Therapeutic Confidence in the Treatment of Pain Related to Temporomandibular Disorders in a Dental Practice-Based Research Network. *J. Oral Facial Pain Headache*. 2017;31:152–158. doi:10.11607/ofph.1730
21. Al-Moraissi EA. Arthroscopy versus arthrocentesis in the management of internal derangement of the temporomandibular joint: A systematic review and meta-analysis. *Int. J. Oral Maxillofac. Surg.* 2015;44:104–112. doi:10.1016/j.ijom.2014.07.008
22. Machoň V, Levorová J, Hirjak D, Beňo M, Drahoš M, Foltán R. Does arthroscopic lysis and lavage in subjects with Wilkes III internal derangement reduce pain? *Oral Maxillofac. Surg.* 2021;25(4):463-470. doi:10.1007/s10006-020-00935-7
23. Laskin DM. Arthroscopy Versus Arthrocentesis for Treating Internal Derangements of the Temporomandibular Joint. *Oral Maxillofac. Surg. Clin. N. Am.* 2018;30:325–328. doi:10.1016/j.coms.2018.04.008
24. Bayramoglu Z, Tozoglu S. Comparison of single- and double-puncture arthrocentesis for the treatment of temporomandibular joint disorders: A six-month, prospective study. *Cranio*. 2021;39(2):151-156. doi:10.1080/08869634.2019.1603796
25. Nagori SA, Roy Chowdhury SK, Thukral H, Jose A, Roychoudhury A. Single puncture versus standard double needle arthrocentesis for the management of temporomandibular joint disorders: A systematic review. *J. Oral Rehabil.* 2018;45:810–818. doi:10.1111/joor.12665

ՆԵՐՔԻՆ TMJ-Ի ԽԱՆԳԱՐՈՒՄՆԵՐԻ ՀԱՄԱԼԻՐ ԲՈՒԺՈՒՄ ՏԱՐԲԵՐ ՕԿԼՅՈՒԶԱԼ ՏԻՊԵՐՈՎ ՀԻՎԱՆՂՆԵՐԻ ՄՈՏ

Բորիս Ղարամանյան, Թինա Չիլիկվաձե, Վալերի Բեկրեն

Վիրաբուժական ստոմատոլոգիայի և դիմաձնոտային վիրաբուժության ամբիոն, Ռուսաստանի Ժողովուրդների բարեկամության համալսարան, Մոսկվա, Ռուսաստանի Դաշնություն

Ամփոփում

Նպատակը. Գնահատել կցվածքների ֆիզիոլոգիական և պաթոլոգիական տեսակների ազդեցությունը TMJ-ի ներքին խանգարումներ ունեցող հիվանդների բուժման արդյունավետության վրա:

Նյութ և մեթոդներ. Կատարվել է 139 հիվանդի համապարփակ հետազոտություն և բուժում՝ ներքին TMJ խանգարումներով հոդխախտի և քրոնիկական հոդխախտի: Հիվանդներին բաժանել են երեք խմբի: Բոլոր խմբերը ներառում էին ինչպես ֆիզիոլոգիական, այնպես էլ պաթոլոգիական խցանումներ ունեցող հիվանդներ: Առաջին խմբում ներառված էին 28 (20.1%) հիվանդներ, որոնք բուժվել են միայն օկլյուզալ սպլինտի թերապիայով: Երկրորդ խումբը ներառում էր 95 (68,3%) հիվանդներ, ովքեր բուժվել են օկլյուզալ սպլինտով թերապիայի և արտրոցենտեզի կիրառմամբ: Երրորդ խմբում (16 հոգի (11,5%), սպլինտային թերապիայի և արթրոցենտեզի հետ մեկտեղ, կատարվել է TMJ արթրոսկոպիա, որը ներառում էր հիվանդների հարցում և հետազոտություն, ծնոտների ախտորոշիչ մոդելների ուսումնասիրություն՝ խցանման և խցանման տեսակների որոշման համար: կոնտակտներ, մագնիսական ռեզոնանսային

տոնոգրաֆիա (MRI) և TMJ-ի ուլտրաձայնային հետազոտություն (ուլտրաձայնային) և արտրոցենտեզ արթրոսկոպիայի հետ համատեղ (բուժման III փուլ):

Արդյունքները. Հետազոտության արդյունքում պարզվել է, որ հիվանդների խմբերը զգալիորեն տարբերվել են բուժման բարդությամբ և տևողությամբ: Այսպես, TMJ-ի ներքին խանգարումներով և խցանման պաթոլոգիական տիպով հիվանդների մոտ 82,6% դեպքերում պահանջվել է արթրոցենտեզի լրացուցիչ կիրառում, իսկ 34,8%-ի մոտ՝ արթրոսկոպիա (95 հիվանդ 139-ից), մինչդեռ ֆիզիոլոգիական տիպի խցանումներ ունեցող հիվանդները (օրթոգնաթիկ, պրոգենիկ, բիպրոգեն և ուղղակի) այս բուժումներն անհրաժեշտ են եղել համապատասխանաբար 80,2% և 7,8% դեպքերում:

Հիվանդների խմբերում թերապիայի տևողությունը, ինչպես նաև բուժման երկրորդ և երրորդ փուլերում հիվանդների մոտ կատարված արթրոցենտեզների քանակը զգալիորեն տարբերվում էր: Առաջին խմբում բուժման տևողությունը եղել է 6,2 ամիս նորմալ օկլյուզիա ունեցող հիվանդների համար և 8,7 ($p < 0,01$) ամիս պաթոլոգիական օկլյուզիա ունեցող հիվանդների համար; բուժման լրացուցիչ մեթոդներ (արթրոցենտեզ և արթրոսկոպիա) չեն օգտագործվել: Հիվանդների երկրորդ և երրորդ խմբերում օկլյուզիայի պաթոլոգիայով հիվանդների բուժման տևողությունը նույնպես ավելի երկար է եղել. երկրորդ խմբում 4,9 և 6,8 ($p < 0,01$) ամիս խցանումների ֆիզիոլոգիական և պաթոլոգիական տիպերով հիվանդների համար, համապատասխանաբար, երրորդում: Նորմալ օկլյուզիայով հիվանդների մոտ սպինտային թերապիայի, արթրոցենտեզի և արթրոսկոպիայի կիրառմամբ խումբը եղել է 13,1 ($p < 0,05$) ամիս, իսկ օկլյուզիայի պաթոլոգիայով հիվանդների մոտ՝ 14,5 ամիս:

Եզրակացություն. TMJ-ի ներքին խանգարումներ ունեցող հիվանդներին անհրաժեշտ է համապարփակ հետազոտություն՝ խցանման պաթոլոգիաների ժամանակին հայտնաբերման համար: Հետագա բուժման մարտավարության և թերապիայի պլանավորման ընտրության ժամանակ միշտ պետք է հաշվի առնել TMJ-ի ներքին խանգարումների և խցանման տեսակի միջև կապը՝ լավագույն արդյունքի հասնելու համար:

КОМПЛЕКСНОЕ ЛЕЧЕНИЕ ВНУТРЕННИХ НАРУШЕНИЙ ВНЧС У ПАЦИЕНТОВ С РАЗНЫМ ТИПОМ ПРИКУСА

Борис Гараманян, Тина Чхиквадзе, Валерий Бекреев

Кафедра хирургической стоматологии и челюстно-лицевой хирургии, Российский университет дружбы народов, Москва, Российская Федерация.

Абстракт

Цель: Оценить влияние физиологических и патологических видов окклюзии на эффективность лечения больных с внутренними нарушениями ВНЧС.

Материал и методы: Проведено комплексное обследование и лечение 139 больных с поражением внутренних органов ВНЧС с подвывихом и застарелым вывихом суставного диска. Больные были разделены на три группы. Во все группы вошли пациенты как с физиологической, так и с патологической окклюзией. В первую группу вошли 28 (20,1%) больных, которым проводилось лечение только окклюзионной шиной; во вторую группу вошли 95 (68,3%) пациентов, которым проводилось лечение в сочетании с окклюзионной шинной терапией и применением артроцентеза; в 3-й группе (16 человек (11,5%) наряду с шинной терапией и артроцентезом выполняли артроскопию ВНЧС. Обследование включало опрос и осмотр пациентов, исследование диагностических моделей челюстей для определения видов окклюзии и окклюзионной контактами, магнитно-резонансной томографией (МРТ) и ультразвуковым исследованием (УЗИ) ВНЧС. Больным проводилось поэтапное лечение, включающее окклюзионную шинную терапию (I этап); при недостаточной эффективности - окклюзионную шинную терапию и артроцентез (II этап); окклюзионную шинную терапию. и артроцентез в сочетании с артроскопией (III этап лечения).

Полученные результаты: В результате исследования выяснилось, что группы больных существенно различались по сложности и длительности лечения. Так, у пациентов с внутренними нарушениями ВНЧС и патологическим типом прикуса в 82,6% случаев потребовалось дополнительное применение артроцентеза и в 34,8% - артроскопии (95 пациентов из 139), а у пациентов с физиологическими типами прикуса (ортогнатический, прогенные, бипрогенные и прямые) нуждались в таком лечении в 80,2% и 7,8% случаев соответственно

В группах больных продолжительность терапии, а также количество артроцентезов, выполненных у больных на втором и третьем этапах лечения, существенно различались. В первой группе продолжительность лечения составила 6,2 мес у больных с нормальной окклюзией и 8,7 ($p<0,01$) мес у больных с патологической окклюзией; дополнительные методы лечения (артроцентез и артроскопия) не применялись. Во второй и третьей группах пациентов продолжительность лечения больных с патологией прикуса также была больше. во второй группе 4,9 и 6,8 ($p<0,01$) мес для больных с физиологическим и патологическим типами прикуса соответственно, в третьей группе с применением шинотерапии, артроцентеза и артроскопии у больных с нормальной окклюзией 13,1 ($p<0,05$).) мес, а у больных с патологией прикуса 14,5 мес.

Заключение: Пациенты с внутренними нарушениями ВНЧС нуждаются в комплексном обследовании для своевременного выявления патологии прикуса. Взаимосвязь внутренних нарушений ВНЧС и типа окклюзии необходимо всегда учитывать при выборе дальнейшей тактики лечения и планировании терапии для достижения наилучшего результата.

DOI: 10.58240/1829006X-2023.19.4-106



CASE REPORT

CASE REPORT: IDIOPATHIC SCLEROSING ORBITAL INFLAMMATION

Armine Gharakeshishyan MD PhD,¹ Hovsep Miroyan MD, PhD,^{2*} Meri Stepanyan MD³

- ¹ Head of the Department of Oculoplastic and Neuro-Ophthalmology, Ophthalmological center after S.V. Malayan, Yerevan, Armenia
- ² Director of Ophthalmological center after S.V. Malayan, Yerevan, Armenia
- ³ Resident of Ophthalmology Department of Yerevan State Medical University after Mkhitar Heratsi, Yerevan, Armenia

* Corresponding author: Hovsep Miroyan Director of Ophthalmological center after S.V. Malayan, Yerevan, Armenia;

e-mail: miroyan.hovsep@gmail.com

Received: Oct. 2, 2023; **Accepted:** Oct. 27, 2023; **Published:** Nov. 5, 2023

Abstract

Idiopathic sclerosing orbital inflammation (ISOI) also known as sclerosing orbital pseudotumor is a rare, idiopathic, chronic, slowly progressive orbital inflammation, characterized by scarring of the tissue that represents a mass effect. The latter leads to bulging of the eye, restriction of ocular movements and visual impairment up to potential loss of vision. It is a subtype of non-specific inflammatory orbital pseudotumor, which both radiologically and clinically mimics a malignant process or other orbital inflammatory disease, and therefore is challenging to diagnose and manage. This case highlights the challenges in diagnosis and management of ISOI.

Keywords: idiopathic sclerosing orbital inflammation, orbital sclerosing pseudotumor, orbital pseudotumor, diagnosis, management

Introduction

Idiopathic sclerosing orbital pseudotumor, is a benign, non-infectious, non-specific inflammatory condition of the orbit in which no local or systemic cause can be identified.¹ It manifests with proptosis, eyelid edema, chemosis, lagophthalmos, diplopia, optic neuropathy. The diagnosis is obtained by exclusion.² HPE is the gold standard currently which shows non-malignant lymphocytic infiltration and dense fibrous tissue. The sclerosing type presents a more aggressive condition and is less responsive to steroids. In this case report, we describe the

management of a 52-year-old woman with orbital pseudotumor at Ophthalmological center after S.V. Malayan in Armenia, who presented with painless, binocular progressive proptosis. Informed consent was obtained from his family before publication of this report.

Case Presentation

A 52-year-old female presented to the Malayan Eye Center, with complaints of gradual protrusion of the right eyeball, redness, cosmetic discomfort,

tearing and severe visual impairment. According to the patient's relatives, the complaints started 4 years ago, with a slight, painless bilateral protrusion of the eyes and the patient applied to another hospital, where she underwent appropriate laboratory tests to rule out thyroid eye disease. The tests showed normal thyroid function.

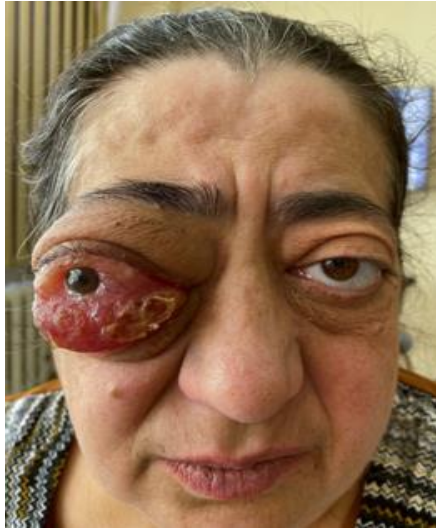

Figure 1. Bilateral proptosis, right eyeball subluxation

The patient also reported that she was diagnosed with paranoid schizophrenia in 2004 and was receiving an appropriate psychiatric therapy. Therefore, she did not continue her eye examination for some time.

On clinical examination in our clinic, there was a total subluxation of the right eyeball, a solid mass was palpated in the medial part of the upper eyelid. Other symptoms present were: chemosis, lagophthalmos, eyelid edema, keratopathy, tearing, visual impairment, mild pain, severe restriction of ocular movements (Figure 1). The visual acuity of the patient in the right eye was determined as a hand motion and 20/30 in the left eye.

The patient underwent CT-scan of the orbits, which revealed a multinodular non-encapsulated mass of 52 x 40mm in the right orbit, with uneven edges, indistinct boundaries, extending from the orbital apex along the medial wall of the orbit. A lot of small nodules were also found in the left orbit, with the same CT features (Figure 2).

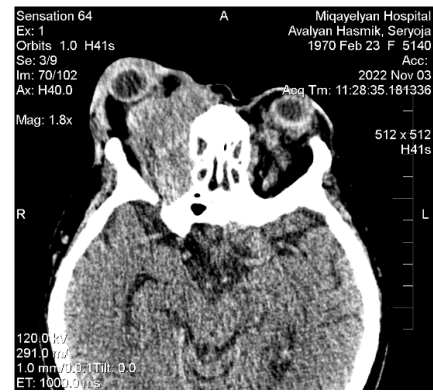


Figure 2. On CT-scan: non-encapsulated, multinodular masses in both orbits with bilateral proptosis; no signs of bone destruction

The muscles and the eyeballs were not involved in the process. There were no destructive changes observed in the bones as well as in the brain tissue. The radiological impression was a suspected orbital pseudotumor, although orbital lymphoma could not be excluded. The patient's blood test results were within normal limits.

Based on the patient's complaints and clinical and radiological examination data, a preliminary diagnosis of intra-orbital neoplasm was made. Since the malignant origin of the neoplasm was not excluded, in order to clarify the diagnosis and determine the tactics of further treatment, an incisional biopsy was performed from the medial part of the upper eyelid. The removed tissue was sent for histopathological examination (HPE), which showed no evidence of malignancy, but instead suggested a preliminary diagnosis of pilomatrixoma, due to the presence of foreign body-type giant cells, amorphous eosinophils, and basophilic cells in the sample.

This answer was quite unexpected, as it is known that pilomatrixoma, which is a benign skin tumor, originates from the matrix of the hair follicle. Whereas in the case of our patient, the mass grew in the orbit and did not involve the skin of the eyelids. Due to the nonspecific finding, we reviewed several case reports related to pilomatrixoma and found that sometimes, very rarely, pilomatrixoma of the orbit can also occur, furthermore, the symptoms of pilomatrixoma were consistent with our patient's symptoms.

Based on the fact that the patient's eye retained some vision and that we were dealing with a clearly non-malignant mass, the previous plan of possible exenteration of the eyeball ruled out, and a surgical

debulking of the intra-orbital mass was performed by an anterior orbitotomy (Figure 3).

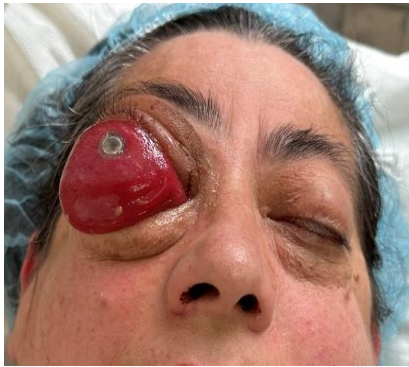

Figure 3. *The condition of the eye before operation*

The mass was found in the orbit and acutely separated within the boundaries of healthy tissues (Figure 4). The eyeball was placed back into orbit. Medial, central and lateral tarsorrhaphies were performed with complete closure of the palpebral fissure to protect the cornea (Figure 5).

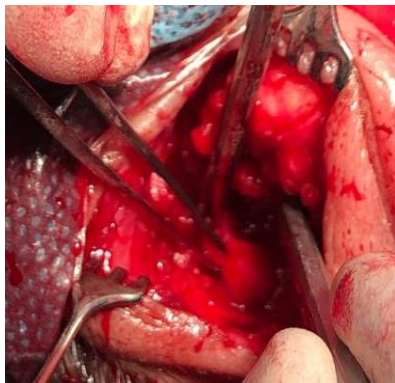


Figure 4. *The arrow points to the solid mass found in the patient's orbit during the surgery*

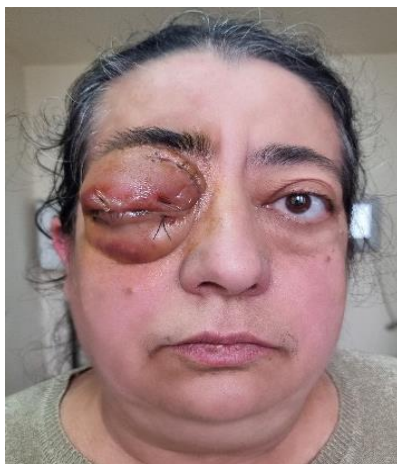

Figure 5. *The condition of the eye after operation*

The removed tissues were sent for HPE and the answer again excluded the malignant origin of the mass, but also excluded the diagnosis of pilomatixoma. The specimen contained large amounts of dense fibrous tissue, giant foreign-body-type cells, and chronic lymphocytic infiltration giving the impression of sclerosing orbital pseudotumor. However, the lymphocytic infiltration was quite large in some areas, which raised the possibility of an alternative diagnosis such as low-grade lymphoma. To clarify the diagnosis immunohistochemical examination was performed, which confirmed the diagnosis of idiopathic sclerosing orbital inflammation.

After 1 month the swelling and the proptosis had decreased and the eyeball had a better position in the orbit, therefore the central tarsorrhaphy was removed to make the binocular vision possible (Figure 6).

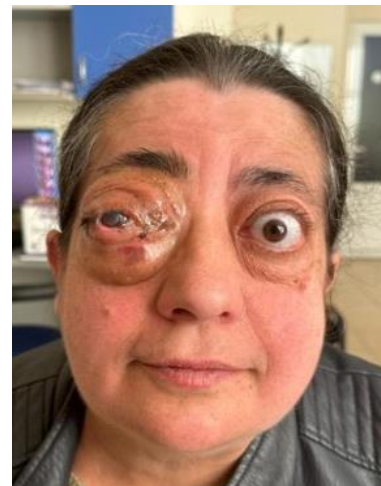

Figure 6. *Patient's eye, after the removal of central tarsorrhaphy*

The condition of the cornea was better and the vision in the right eye was determined as object detection.

Discussion

Idiopathic sclerosing orbital inflammation also known as sclerosing orbital pseudotumor is a rare subtype of non-specific, idiopathic orbital inflammation that is poorly defined and is described in the literature in case reports or small series only.³ It is a benign, space-occupying orbital inflammation

without local or systemic known cause, which both clinically and on orbital imaging mimics a malignant process or other orbital inflammatory disease, and therefore is difficult to diagnose and manage. The presentation may be unilateral or bilateral. It occurs in all age groups without gender predilection. The sclerosing type behaves differently than other types of pseudotumor of the orbit. It grows more slowly, does not cause ocular pain and has moderate response to steroid therapy. It can also rarely extend into the sinuses, brain, and the other orbit.

The pathogenesis is unclear, yet several lines of evidence suggest an autoimmune process, due to the response to immunosuppressive agents.⁴

The most common signs and symptoms observed are proptosis, restriction of extraocular muscle movements and visual impairment or loss of vision: when the mass has an apical location. Other clinical features include: palpebral edema, diplopia, chemosis, redness, palpable orbital mass, lagophthalmos, exposure keratopathy, tearing.⁵

The diagnosis is obtained by exclusion. For that, along with the clinical examination, CT-scan of the orbit, HPE and laboratory tests for differential diagnosis with other diseases (T3, T4, TSH, c-ANCA antibodies, ANA (antinuclear antibody), RF (rheumatoid factor)) are crucial.

Histopathological features are currently considered the gold standard for diagnosing sclerosing orbital pseudotumor. In cases where the histological findings raise the possibility of an alternative diagnosis, immunohistochemical examination is necessary.

Orbital CT-scan usually reveals focal or diffuse mass in the retrobulbar space, showing the involvement of muscles, the eyeball or the optic nerve in the inflammatory process. Orbital imaging is an essential tool, it allows to determine the localization of the mass.

HPE reveals a large amount of dense fibrous tissue associated with pleomorphic inflammatory cell infiltration. The main cell types found in specimens include lymphocytes, eosinophils and foreign body type giant cells. Lymphocytes were by far found in all specimens, and it has been suggested that they play a critical role in driving the processes that leads to fibrosis.

The main diagnoses that should be excluded are: Thyroid Eye Disease, Wegner's granulomatosis,

sclerosing lymphoma, metastatic sclerosing tumors of breast.

All these other possible diseases can be excluded by the presence of high or low levels of characteristic serum markers, antibodies and hormones, and by typical features of X-rays and biopsies.

Compared with other types of inflammatory orbital pseudotumor, the sclerosing type is less responsive to steroid therapy. Most cases suggest combinations of surgery and steroid therapy.

Others found convincing results of using nonsteroidal immunosuppressive - agents (cyclophosphamide, azathioprine, methotrexate) with steroids. Azathioprine or other second-line agents can be used to reduce the use of corticosteroids.

Surgical debulking is crucial for patients with severely progressive and disabling clinical courses (apical mass with optic nerve compression) or when the lesion is focal and easily approachable.

Conclusion

Sclerosing orbital pseudotumor is an uncommon disorder that mimics malignant process or other orbital inflammatory disease and is difficult to diagnose and manage. No large studies exist because of the rare nature of the disease. Although the etiology remains unknown, an underlying immunological mechanism has been suggested. CT-scan of the orbit and HPE are required to confirm diagnosis. Steroids represent the first option of treatment. The sclerosing subtype shows moderate response to steroids, therefore combination therapy is suggested.

Declarations

Conflict of interest and financial disclosure

The author declares that he has no conflict of interest and there was no external source of funding for the present study. None of the authors have any relevant financial relationship(s) with a commercial interest.

Ethical approval

Research protocol was approved by the local Ethical Committee (2018/23) and in accordance with

those of the World Medical Association and the Helsinki Declaration.

Informed consent

Informed consent was obtained from all individual participants included in the study.

Source of Funding

Non funding.

Availability of Data and Materials

Not applicable.

REFERENCES

1. Brannan PA. A review of sclerosing idiopathic orbital inflammation. *Curr Opin Ophthalmol.* 2007;18(5):402-4. doi:10.1097/ICU.0b013e3282bfe85b
2. Sripathi S, Shenoy PM, Ayachit A, Kadavigere R. Bilateral sclerosing orbital pseudotumour in an adult. *BMJ Case Rep.* 2014;2014:bcr2013203389. doi:10.1136/bcr-2013-203389
3. Nagai K, Andoh K, Nakamura N, et al. Suspected idiopathic sclerosing orbital inflammation presenting as immunoglobulin G4-related disease: a case report. *J Med Case Reports.* 2011;5:427. doi:10.1186/1752-1947-5-427
4. Hsuan JD, Selva D, McNab AA, Sullivan TJ, Saeed P, O'Donnell BA. Idiopathic sclerosing orbital inflammation. *Arch Ophthalmol.* 2006;124(9):1244-50. doi:10.1001/archophth.124.9.1244
5. Liu CH, Ma L, Ku WJ, Kao LY, Tsai YJ. Bilateral idiopathic sclerosing inflammation of the orbit: report of three cases. *Chang Gung Med J.* 2004;27(10):758-65

ՕՐԲԻՏԱՅԻ ԻԴԻՈՊԱԹԻԿ ՍԿԼԵՐՈԶԱՅՆՈՂ ԲՈՐԲՈՔՈՒՄ. ԴԵՊՔԻ ՉԵԿՈՒՅՑ

Արմինե Ղարաքեչիշյան բ.գ.թ.,¹ Հովսեփ Միրոյան բ.գ.թ.,² Մերի Ստեփանյան³

- ¹ Ս.Վ.Սալայանի անվան Ակնաբուժական կենտրոնի ակնաբուժական և նեյրոակնաբուժության բաժանմունքի վարիչ, Երևանի Մխիթար Հերացու անվան պետական բժշկական համալսարանի ակնաբուժական ամբիոն
- ² Ս.Վ. Սալայանի անվան ակնաբուժական կենտրոնի տնօրեն, Երևան, Հայաստան
- ³ Ս.Վ.Սալայանի անվան Ակնաբուժական կենտրոնի ակնաբուժական և նեյրոակնաբուժության բաժանմունքի օրդինատոր, Երևան, Հայաստան

Ամփոփում

Օրբիտայի իդիոպաթիկ սկլերոզացնող բորբոքումը (ISOI), որը նաև հայտնի է նաև որպես օրբիտայի սկլերոզացնող կեղծ ուռուցք, իրենից ներկայացնում է օրբիտայում հյուսվածքի սպիացումով ընթացող հազվագյուտ, իդիոպաթիկ, քրոնիկական, դանդաղ պրոգրեսիվող բորբոքում, ինչը կլինիկորեն նմանվում է նորագոյացության: Վերջինս հանգեցնում է ակնագնդի արտանկման, շարժումների սահմանափակման և տեսողության խանգարման՝ ընդհուպ մինչև տեսողության կորուստ: Այն օրբիտայի ոչ սպեցիֆիկ բորբոքային կեղծ ուռուցքի ենթատեսակ է, որը թե՛ ռենտգենաբանորեն և թե՛ կլինիկորեն նմանվում է օրբիտայի այլ բորբոքային հիվանդությունների կամ չարորակ պրոցեսների, և հետևաբար, դժվար է ախտորոշել և բուժել: Այս կլինիկական դեպքը ընդգծում է ISOI-ի ախտորոշման և բուժման խրթին կետերը:

ИДИОПАТИЧЕСКОЕ СКЛЕРОЗИРУЮЩЕЕ ВОСПАЛЕНИЕ ОРБИТЫ. КЛИНИЧЕСКИЙ СЛУЧАЙ

Армине Каракешисян к.м.н.,¹ Овсеп Мироян к.м.н.,² Мери Степанян³

- ¹ Заведующий отделением окулопластики и нейроофтальмологии Офтальмологического центра им. С.В. Малаян, кафедра офтальмологии Ереванского государственного медицинского университета имени Мхитара Гераци
- ² Директор Офтальмологического центра им. С.В. Малаян, Ереван, Армения
- ³ Ординатор кафедры офтальмологии Ереванского государственного медицинского университета, Ереван, Армения

Аннотация

Идиопатическое склерозирующее воспаление орбиты (ISOI), также известное как склерозирующий псевдотумор орбиты это редкое, идиопатическое, хроническое, медленно прогрессирующее воспаление орбиты, характеризующееся рубцеванием ткани, которое проявляется симптомами опухоли. Последнее приводит к выпучиванию глазного яблока, ограничению движений глаза и ухудшению зрения вплоть до потенциальной потери зрения. Это подтип неспецифического воспалительного псевдотумора орбиты, который как рентгенологически, так и клинически имитирует злокачественный процесс или другое воспалительное заболевание орбиты, и поэтому сложно диагностировать и лечить. Этот случай подчеркивает трудности диагностики и лечения ISOI.

DOI: 10.58240/1829006X-2023.19.4-112



ORIGINAL ARTICLE

MODERN METHODS FOR ASSESSING MOTOR AND SENSORY INTER-HEMISPHERIC ASYMMETRY OF THE BRAIN IN CHILDREN OF PRIMARY AND SECONDARY SCHOOL AGE (8-11 YEARS OLD)

Tereza Azatyan PhD,^{1*} Stepan Grigoryan²

- ¹ Associate professor, Head of the Chair of Special Pedagogy and Psychology, Faculty of Special and Inclusive Education, Armenian State Pedagogical University after Kh. Abovyan
- ² Head of the Chair of Speech and Rehabilitation Therapy, Faculty of Special and Inclusive Education, Armenian State Pedagogical University after Kh. Abovyan

* Corresponding author: Tereza Azatyan, PhD, Associate professor, Department of Special Pedagogy and Psychology, Yerevan, Armenia;
e-mail: azatyantereza41@aspu.am

Received: Oct. 2, 2023; **Accepted:** Oct. 27, 2023; **Published:** Nov. 5, 2023

Abstract

Background: The neuropsychological study of some features of interhemispheric relationships in the motorsphere in children with various types of mental disorders is of undoubted interest. It can show a number of new aspects of the problem of the formation of inter-hemispheric asymmetry and inter-hemispheric interaction in ontogenesis.

Methodology: Nowadays, two approaches are used in physiology to assess brain inter-hemispheric differences: the method of determining the "handedness" by means of a survey (Edinburgh test) and the method of actively detecting motor and sensory asymmetry by N.N. Bragina and T.A. Dobrokhotova methodology.

Results: The neuropsychological study of some features of interhemispheric relationships in the motor sphere in children with various types of mental disorders is of undoubted interest. It can show a number of new aspects of the problem of the formation of inter-hemispheric asymmetry and inter-hemispheric interaction in ontogenesis.

Both techniques are widely represented in modern scientific literature, but we have not found research that describes the relationship between the results of testing assessment of functional brain asymmetry using the Edinburgh test and tests for determining motor and sensory asymmetry.

Normally, the formation of brain inter-hemispheric asymmetry and inter-hemispheric interaction is, of course, heterochronical in nature.

Conclusion: Therefore, the examined schoolchildren may encounter an almost fully formed primary level of inter-hemispheric connections, while the second and third levels are still in their formation. At the same time, a comparison between the results of healthy children of 8–11 years of age shows that the functional organization of inter-hemispheric asymmetry and inter-hemispheric interaction in this age range is in a state of constant ongoing development.

Keywords: *inter-hemispheric asymmetry, inter-hemispheric interaction, manual (motor) asymmetry, functional asymmetry, kinesthetic praxis.*

Introduction

Nowadays, two approaches are used in physiology to assess brain interhemispheric differences: the method of determining the "handedness" by means of a survey (Edinburgh test)¹ and the method of actively detecting motor and sensory asymmetry by N.N. Bragina and T.A. Dobrokhotova methodology.² The Edinburgh test is widely used in the world: it is used in studying behavior and emotions.^{3,4,5} Trials to determine the leading limbs and the leading eye are recommended to use when assessing the impact of brain lateralization on intelligence and mathematical abilities,⁶ when studying the adaptive capabilities and physical development of young people, as well as the formation of the body's stress resistance.⁷ Both techniques are widely represented in modern scientific literature, but we have not found research that describes the relationship between the results of testing assessment of functional brain asymmetry using the Edinburgh test and tests for determining motor and sensory asymmetry.

Testing methodology

Functional testing should be carried out in the first half of the day, in conditions that meet the hygienic

requirements for educational institutions.⁸ Comply with the ethical requirements prescribed by the Helsinki Declaration.

Detection of functional asymmetry of hands

At the first stage of the research, schoolchildren answer the questions of the Edinburgh test.⁹ In this case, their parents can answer for children aged 8-9 years. Since the purpose of the study is to perform a comparative analysis of functional motor asymmetry of normally developing schoolchildren and children of the same age with varying degrees of mental retardation, we have developed our original test questionnaire, adapted from well-known tests — the Edinburgh and Bragina and Dobrokhotova method.² In our test questionnaire, we retained the first 10 questions of the Edinburgh test, which supplemented with 4 questions that, in our opinion, will help to form a clearer impression about the preference for using the right or left hand when performing certain actions, such as writing, painting, sewing, combing hair, brushing teeth, using a spoon or fork, etc. (Table 1).

Table 1. Student Application Form

	Action performed	Left hand	Right hand
1.	Which hand do you write with?		
2.	Which hand do you draw with?		
3.	Which hand do you throw the ball with?		
4.	Which hand do you catch the ball with?		
5.	Which hand do you hold scissors with?		
6.	Which hand do you hold a toothbrush with?		
7.	Which hand do you hold a dinner spoon with?		
8.	Which hand do you hold the comb with?		
9.	Which hand do you open the lid of the box (candy box) with?		
10.	Which hand do you hold the hammer with when you hammer a nail?		
11.	The finger of the leading hand rests on top when crossing (lock) fingers		

12.	"Napoleon's Pose" (the leading is considered to be the hand which is directed first to the forearm of the other hand and is placed on top of it)		
13.	Applause test (the leading hand is more active and mobile, makes shock movements on the palm of the non-leading hand)		
14.	Which hand do you pick up the object from the floor with?		

According to the results of the test questionnaire, the coefficient of functional asymmetry (CFA), the coefficient of manual (motor) asymmetry (CMA) and the coefficient of general asymmetry (CGA) are calculated using the following formulas:

$$CFA = (N (\text{right}) - N (\text{left})) / Nm$$

Where CFA is the coefficient of functional asymmetry, N (right) and N (left) the number of “+” signs in the columns “Right hand” and “Left hand”, respectively, Nm is the number of proposed tests.

$$CMA = (N (\text{right})) / Nm$$

Where CMA is the coefficient of manual asymmetry, N (right) is the number of actions performed by the right hand, Nm is the number of proposed tests.

$$CGA = (CFA + CMA) / 2$$

Where CGA is the coefficient of total (General) asymmetry, the arithmetic average of the coefficients of CFA and CMA.

Trial of kinesthetic praxis

To study brain interhemispheric interaction in the field of voluntary movements, it is recommended to use experimental methods developed by A.R. Luria [8]. The complex of trials includes the study of kinesthetic praxis (mono-manual reproduction of hand position using visual and kinesthetic patterns, transferring poses from one hand to another without visual control), kinetic (dynamic) praxis (performing reciprocal coordination), test “fist-edge-palm” etc., spatial praxis, as well as writing and drawing. These tests allow more precisely to assess the inter-hemispheric interaction in the motor area (this applies

particularly to bimanual testes), understand the formation of inter-hemispheric connections and their influence on the successful performance of spatial motor tasks, and also to make a conclusion about the degree of maturity and flexibility of inter-hemispheric relationships in the motor sphere.

When interpreting the results of the study, the percentage of children who successfully completed the proposed tests is calculated, the qualitative features of the errors made are analyzed. The features of interhemispheric relations in normal and with varying degrees of mental retardation, and age differences are evaluated.

Assessment of auditory and oral speech asymmetry

To determine the lateralization of the hearing-speech functions, the dichotic listening method with the definition of the “right ear coefficient” (CPA) is used. Dichotic stimulation can be performed through headphones in both ears at the same time. For separate channels are presented two sets of verbal stimuli (words). This technique requires special equipment, while one of our tasks is to propose the use of available methods that we could recommend to school psychologists for diagnostic purposes.

To study the asymmetry of hearing, you can use simple, available techniques and techniques that do not require use of special tools. So, we selected the following methods: test "Whisper",² test "Ticking of watch".¹⁰ In this case, if the test reveals the dominance of the right ear, then put (+1) score, if the dominance of the left ear (-1) score. Zero score is assigned with no identified dominance of the right or left ear.

Test "whisper". The experimenter says something in a whisper. In case of equal hearing acuity in both ears, the subject puts his leading ear to the speaker,

what it means that this ear is heard more easily and quickly realized.

Test "ticking hours". The subject is asked to evaluate the volume of the ticking of the clock or the sound of the stopwatch with one and the other ear. It is noted at the same time, to which ear he puts the clock for the first time and whether the different ears evaluate the volume of the tick to be the same. It should be noted, what ear the subject pushes forward to listening something.¹⁰

Test "tuning fork". The time of perception of the sound of the tuning fork, which is brought alternately to the right and left ear, is determined.

Assessment of visual asymmetry

The following tests are used to determine the leading eye:

Test "blink with one eye." The subject is asked to blink with one eye. Usually not leading eye closes.

Rosenbach's test. The subject holds a pencil vertically in an outstretched hand and fixes it with a gaze at a certain point (preferably with respect to any vertical line), 3-4 m apart, with both eyes open. Then the subject alternately closes one and the other eye. The eye is considered to be the leading, when closed, the pencil shifts in its direction.^{11,12}

Test "card with a hole". A 1x1 cm hole is cut out in a sheet of thick paper. Holding this card at a short distance from the eyes, the subject examines objects. Viewing is usually carried out by the leading eye.^{2,13}

Self-esteem of the subject. The answer to the question of which eye he aims with.

Thus, methods aimed at analyzing motor and sensory preferences when performing certain behavioral acts, which allow us to determine not only the degree of interhemispheric asymmetry, but with their help it becomes possible to evaluate the degree of interhemispheric interaction.

The total assessment of the profile of the lateral organization

All possible types of profile of the lateral organization were divided into 5 main groups.

- Group 1: the test group with a full right-sided domination of the arm, ear and eye is included in the "pure right-handers" group.
- Group 2: All subjects with dominance of the right hand, but with different combinations of asymmetries of hearing and vision, belong to the "right-handed" group.
- Group 3: the left-right equality (ambidextrous) group is characterized by equality in manual lateralization and a different combination of asymmetries in the hearing and visual functions.
- Group 4: the group of "left-handed" includes subjects with a predominance of the left hand with various combinations of asymmetries of hearing and vision.
- Group 5: the group with complete left-sided dominance of the arm, ear, and eye define a group of "clean left-handers."

Discussion

Normally, the formation of brain inter-hemispheric asymmetry and inter-hemispheric interaction is, of course, heterochrony in nature. Therefore, the examined schoolchildren may encounter an almost fully formed primary level of interhemispheric connections, while the second and third levels are still in their formation. This leads to the fact that healthy children of 8 years are not yet fully successful in complex bimanual movements, automated execution of motor programs, the implementation of spatially organized motor acts, based on the "body pattern" and the speech level of representation of spatial relationships. Some of them, various motor, and sensory asymmetries, have not yet fully stabilized. At the same time, a comparison between the results of healthy children of 8–11 years of age show that the functional organization of inter-hemispheric asymmetry and inter-hemispheric interaction in this age range is in a state of constant ongoing development.

Another aspect of the test results, which is important not to be ignored, concerns the peculiarities of the development of interhemispheric asymmetry and interhemispheric interaction in children with left-handedness. It is well known that the presence of the left-handedness factor in most cases suggests an atypical, from the point of view of brain organization, the flow of mental ontogenesis.¹⁴ Usually, left-handers have distortions, peculiar delays, and disproportions in the formation of various mental functions: speech (oral and written), reading, counting, constructive processes, spatial representations, emotional sphere, etc. They are a “risk group” in terms of the occurrence of logoneuroses (stuttering) and the pathocharacteristic features of the personality.¹⁴⁻¹⁶

According to the results of several studies within the ambidextral group, children with balanced right-left laterality in brain processes appeared. In our opinion, the term "ambicerebrality" is more appropriate for this phenomenon. The following working formulation should be adopted: ambicerebrality is the ability of the right and left human brain alternately, or in parallel, and at the same time to process information. We express the opinion that this is a more accurate fixation of a new trend that differs from “two-handedness” – ambidexterity.¹⁷

Conclusion

Therefore, the examined schoolchildren may encounter an almost fully formed primary level of inter-hemispheric connections, while the second and

third levels are still in their formation. At the same time, a comparison between the results of healthy children of 8–11 years of age shows that the functional organization of inter-hemispheric asymmetry and inter-hemispheric interaction in this age range is in a state of constant ongoing development.

Declarations

Conflict of interest and financial disclosure

The author declares that he has no conflict of interest and there was no external source of funding for the present study. None of the authors have any relevant financial relationship(s) with a commercial interest.

Ethical approval

Research protocol was approved by the local Ethical Committee (2018/23) and in accordance with those of the World Medical Association and the Helsinki Declaration.

Informed consent

Informed consent was obtained from all individual participants included in the study.

Source of Funding

Non funding.

Availability of Data and Materials

Not applicable.

REFERENCES

1. Oldfield RC. The Assessment and Analysis of the Edinburgh Inventory. *Neuropsychologia*. 1971;9(1):97-113. doi:10.1016/0028-3932(71)90067-4
2. Bragina NN, Dobrokhotova TA. Functional human asymmetries - 2nd ed. reclaiming and add. - M.: Medicine, 1988;237
3. Pankova NB, Romanov SV. Dynamics in the academic year of behavioral manifestations and quantitative indicators of functional interhemispheric asymmetry among students // Scientific Perspectives of the 21st Century. Achievements and Prospects of the New Century // III International Scientific and Practical Conference, Novosibirsk, 15–16 August 2014 -

- №3. Part 5. - Novosibirsk: International Scientific Institute "Educatio". 2014;38–42
4. Mikhailov IV, Tkachenko PV. The value of functional asymmetry in teaching complex targeted bimanual movements. *Modern high technologies*. 2009;9:59–62
 5. Aron A, Fisher H, Mashek DJ, Strong G, Li H, Brown LL. Reward, motivation, and emotion systems associated with early-stage intense romantic love. *Journal of Neurophysiology*. 2005;94(1):327–337. doi:10.1152/jn.00838.2004
 6. Khokhlov NA, Kovyazina MS. Lateral signs, structural-level characteristics of intelligence and mathematical abilities. *Journal "Asymmetry"*. 2013;7(3):32–52
 7. Lisova NA. The role of the activation processes of the cerebral cortex in the formation of stress tolerance in female students with different temperamental characteristics. *Siberian Journal of Special Education*. 2015;2(15):52-57
 8. SanPiN 2.4.2.2821-10 "Sanitary and epidemiological requirements for the conditions and organization of training in educational institutions" from 03.03.2011
 9. Henderson SE, Morrys J, Frith V. The motor deficit in Down's Syndrome children: a problem of timing? *Child. Psychology and Psychiatry*. 1981;22(3):233–245. doi:10.1111/j.1469-7610.1981.tb00549.x
 10. Leutin VP, Nikolaeva EI, Fomina EV. Brain asymmetry and human adaptation. *Asymmetry*. 2007;1(1):71–73
 11. Luria AR. Fundamentals of Neuropsychology. Moscow. 1973;374
 12. Berlucchi G, Sprague JM, Antonini A, Simoni A. Learning and interhemispheric transfer of visual pattern discriminations following unilateral suprasylvian cuts for split / chimes. *Experimental Brain Research*. 1979;34(3):551–574
 13. Annett M. Five test of hand skill. *Cortex*. 1992;28(4):583-600. doi:10.1016/s0010-9452(13)80229-8
 14. Semenovich AV. Neuropsychological diagnosis and correction in childhood. Moscow: Akademiya. 2002;232
 15. Manelis NG, Lebedeva AN. The influence of the individual profile of the functional asymmetry of the brain on the severity of phantom-pain syndrome. *Actual problems of psychophysiology and neuropsychology, Moscow: Izd-vo IPE USSR*. 1991;213–222
 16. Semenovich AV. Inter-hemispheric organization of mental processes in left-handers. *Moscow: MGU Publishing House*. 1991;95
 17. Luria AR. Higher human cortical functions and their violations in local brain lesions. M.: *Akademicheskyy project*. 2000;512

ԿՐՏՍԵՐ ԵՎ ՄԻՋԻՆ ՏԱՐԻՔԻ (8-11 ՏԱՐԵԿԱՆ) ԴՊՐՈՑԱԿԱՆ ԵՐԵԽԱՆԵՐԻ ՄՈՏ ՈՒՂԵՂԻ ՇԱՐԺԻՉ ԵՎ ՍԵՆՍՈՐ ՄԻՋԿԻՍԱԳՆԴԱՅԻՆ ԱՆՀԱՄԱԶՈՒԹՅԱՆ ԺԱՄԱՆԱԿԱԿԻՑ ԳՆԱՀԱՏՄԱՆ ՄԵԹՈԴՆԵՐԸ

Թերեզա Ազատյան,¹ Ստեփան Գրիգորյան²

¹ Հատուկ մանկավարժության և հոգեբանության ամբիոն, Խ. Աբովյանի անվան Հայկական պետական մանկավարժական համալսարան, Երևան, Հայաստան

² Լոգոպեդիայի և վերականգնողական թերապիայի ամբիոն, Խ. Աբովյանի անվան Հայկական պետական մանկավարժական համալսարան, Երևան, Հայաստան

Ամփոփում

Ներածություն. Տարբեր տեսակի հոգեկան խանգարումներ ունեցող երեխաների նյարդահոգեբանական ուսումնասիրությունը շարժիչ ոլորտում միջկիսագնդային անհամաչափության որոշ առանձնահատկությունների վերաբերյալ անկասկած հետաքրքրություն է ներկայացնում: Այն կարող է ցույց տալ մի շարք նոր ասպեկտներ օնտոգենեզում միջկիսագնդային անհամաչափության և միջկիսագնդային փոխազդեցության ձևավորման խնդրի վերաբերյալ:

Մեթոդաբանություն. Ներկայումս ֆիզիոլոգիայում օգտագործվում է երկու մոտեցում՝ ուղեղի միջկիսագնդային տարբերությունները գնահատելու համար՝ հարցման միջոցով (Էդինբուրգյան թեստ) և շարժիչ և զգայական անհամաչափության ակտիվ բացահայտման մեթոդ՝ Ն.Ն. Բրագինի և Թ.Ա. Դոբրոխտովի մեթոդիկա:

Արդյունքներ. Երկու մեթոդներն էլ լայնորեն ներկայացված են ժամանակակից գիտական գրականության մեջ, բայց մենք չկարողացանք գտնել ուսումնասիրություններ, որոնք նկարագրում են ուղեղի ֆունկցիոնալ ասիմետրիայի թեստային գնահատման արդյունքների կապը Էդինբուրգյան թեստի և շարժիչ ու սենսոր ասիմետրիայի որոշման թեստերի միջև: Սովորաբար, ուղեղի միջկիսագնդային ասիմետրիայի և միջկիսագնդային փոխազդեցության ձևավորումը, անշուշտ, ունի հետերոքրոն բնույթ:

Եզրակացություն. Այսպիսով, հետազոտված դպրոցականները կարող են նկատվել միջկիսագնդային կապերի գրեթե ամբողջությամբ ձևավորված առաջնային մակարդակ, մինչդեռ երկրորդ և երրորդ մակարդակները դեռ ձևավորման փուլում են: Միևնույն ժամանակ, 8-11 տարեկան առողջ երեխաների արդյունքների համեմատությունը ցույց է տալիս, որ այս տարիքային միջակայքում միջկիսագնդային ասիմետրիայի և միջկիսագնդային փոխազդեցությանը գտնվում է մշտական շարունակական զարգացման վիճակում:

СОВРЕМЕННЫЕ МЕТОДЫ ОЦЕНКИ МОТОРНОЙ И СЕНСОРНОЙ МЕЖПОЛУШАРНОЙ АСИММЕТРИИ МОЗГА У ДЕТЕЙ МЛАДШЕГО И СРЕДНЕГО ШКОЛЬНОГО ВОЗРАСТА (8-11 ЛЕТ)

Тереза Азатян,¹ Степан Григорян²

¹ Кафедра специальной педагогики и психологии, Армянский государственный педагогический университет имени Х. Абовяна, Ереван, Армения

² Кафедрой логопедии и реабилитационной терапии, Армянский государственный педагогический университет им. Х. Абовян, Ереван, Армения

Введение: Нейропсихологическое изучение некоторых особенностей межполушарных взаимоотношений в двигательной сфере у детей с различными видами психических расстройств представляет несомненный интерес. Оно может показать ряд новых аспектов проблемы формирования межполушарной асимметрии и межполушарного взаимодействия в онтогенезе.

Методология: В настоящее время в физиологии используются два подхода для оценки межполушарных различий мозга: метод определения «рукастости» посредством опроса (Эдинбургский тест) и метод активного выявления двигательной и сенсорной асимметрии, методика Н.Н. Брагина и Т.А. Доброхотова.

Результаты: Обе методики широко представлены в современной научной литературе, однако нам не удалось найти исследования, описывающие взаимосвязь результатов тестовой оценки функциональной асимметрии мозга с помощью Эдинбургского теста и тестов на определение моторной и сенсорной асимметрии. В норме формирование межполушарной асимметрии мозга и межполушарного взаимодействия носит, конечно, гетерохронный характер.

Заключение: Таким образом, у обследуемых школьников может наблюдаться практически полностью сформированный первичный уровень межполушарных связей, тогда как второй и третий уровни еще находятся в стадии формирования. В то же время сравнение результатов здоровых детей 8–11 лет показывает, что функциональная организация межполушарной асимметрии и межполушарного взаимодействия в этом возрастном диапазоне находится в состоянии постоянного непрерывного развития.



CASE REPORT

THE USE OF “DIPLLEN-S” ADHESIVE MEMBRANE IN THE COMPLEX THERAPY OF RECURRENT APHTHOUS STOMATITIS. (CLINICAL CASE REPORT)

Lyudmila Tatintyan,^{1*} Lazar Yessayan,² Gohar Gevorgyan,³ Tatevik Barseghyan,⁴ Valery Tatintyan⁵

- ¹ Associate professor Department of Therapeutic stomatology, Yerevan State Medical University. M. Heratsi
² Professor, Head of Department of Therapeutic stomatology, Yerevan State Medical University after M. Heratsi
³ Assistant professor of Department of Therapeutic stomatology, Yerevan State Medical University after M. Heratsi
⁴ Lecturer Department of Pediatric stomatology and Orthodontics, Yerevan State Medical University. M. Heratsi
⁵ Professor of Department of Therapeutic stomatology, Yerevan State Medical University after M. Heratsi

* Corresponding author: Lyudmila Tatintyan, Associate professor Department of Therapeutic stomatology, Yerevan State Medical University after M. Heratsi;
e-mail: l_tatintyan@yahoo.com

Received: Oct. 2, 2023; **Accepted:** Oct. 27, 2023; **Published:** Nov. 5, 2023

Абстракт

Recurrent aphthous stomatitis (RAS) is a common ulcerative disease of the oral mucosa. In the etiopathogenesis of this pathology, there is no single concept that would outline the data of the trigger mechanisms that determine chronic recurrent aphthous stomatitis, interpreting the statement of the manifestation of various clinical signs in the oral cavity. The paper presents the results of treatment and dental examination of a patient using the protective adhesive film “Diplen-S” in the complex therapy of chronic recurrent stomatitis (RAS). The use of the adhesive film “Diplen-S” led to a decrease and disappearance of pain, accelerated the healing time and epithelization of aphthae with no side effects.

Conclusion: The positive clinical results obtained, wound healing in an accelerated time, are the basis for recommending the use of the adhesive film “Diplen” in the complex therapy and treatment of RAS, in the practice of stomatology.

Keywords: oral mucosa, “Diplen-S” adhesive membrane, recurrent aphthous stomatitis.

Introduction

The oral mucosa (OM) is an indicator of the state of the body and its relationship with the external environment. Under the influence of unfavorable endogenous and exogenous factors, pathological

processes of an inflammatory and destructive nature arise in the oral mucosa.^{1,2}

Among the numerous lesions of the oral mucosa of various etiologies is chronic recurrent aphthous stomatitis (RAS), which has its own characteristics of manifestation in the oral cavity.^{3,4}

HRAS accounts for 90% of violations of the integrity of the mucous membrane encountered in dental practice - characterized by the occurrence of aphthae (from the Greek aphtha - ulcer) and occurring with periodic exacerbations and remissions.^{5,6}

In the etiopathogenesis of this pathology, there is no single concept that would outline the data of the trigger mechanisms that determine chronic recurrent aphthous stomatitis, interpreting the statement of the manifestation of various clinical signs in the oral cavity.^{7,8} A number of authors point to the role of autoimmune processes in the pathogenesis of recurrent aphthous stomatitis. Those who carried out microscopic studies of the mucous membrane in CRAS found that in almost half of the patients there was a glow along the basement membrane area, and in one third - in the area of the vascular wall.

A number of authors point to the role of autoimmune processes in the pathogenesis of recurrent aphthous stomatitis.^{9,10} Those who carried out microscopic studies of the mucous membrane in RAS found that in almost half of the patients there was a glow along the basement membrane area, and in one third - in the area of the vascular wall.

The glow was due to the third fraction of complement and deposits of fibrin, sometimes IgM and IgG, so it should be assumed that identified circulating immune complexes play a certain role in tissue damage in RAS.^{11,12} Using intradermal tests, we detected mono- and polyvalent allergies to proteo, streptococcus, staphylococcus and E coli in patients, with which the authors attribute a significant role to bacterial allergy.

In the pathogenesis of aphthous stomatitis, a cross-immune reaction may have a certain significance, since there is a bacterial flora on the oral mucosa and in the intestines, and antibodies produced in its presence may mistakenly attack the epithelial cells of the mucous membrane due to the similarity of their antigenic structure with that of some bacteria.¹³⁻¹⁵

This may well explain the manifestations of the Arthus phenomenon, as well as the significance of gastrointestinal pathology, accompanied by an imbalance between the body and the bacterial flora, in the origin of RAS.¹⁶

The role of gastrointestinal pathology and liver diseases in the pathogenesis of aphthous stomatitis. Found by many authors.^{17,18}

The causes of aphthous stomatitis can also be the presence of malignant tumors in the neck or nasopharynx, the body's reaction to chemotherapy procedures, the presence of AIDS, the use of drugs that reduce salivation, seasonal vitamin deficiency, or a lack of beneficial microelements (iron) in the body.^{13,17}

Taking into account the interpretation of the etiopathogenesis of RAS, where there is no single approach, we can say that this pathology is not completely curable and mainly manifests itself with reduced immunity.

Various treatment methods have been proposed for the treatment of recurrent aphthous stomatitis, but the search for effective treatment methods continues.¹⁸⁻²⁵

In this case, it is necessary to consider the main task of pathogenetic therapy, reducing the risk of relapse using protection of ulcers with the help of various dressings aimed at rapid epithelization of ulcers and the functioning of homeostasis of the oral cavity. Known dressings used in the oral cavity are mainly based on zinc oxide with the introduction of various drugs into its composition (antibiotics, corticosteroids, enzymes, vitamins, etc.). However, they have many disadvantages: they are ungrammatical, functionally and cosmetically do not meet clinical requirements - they are quickly washed off with oral fluid from the wound surface.

The most optimal, in our opinion, is the use of the adhesive membrane "Diplen", developed at the Department of General Chemistry and Therapeutic Dentistry of Yerevan State Medical University, which best meets the clinical requirements for the treatment of CRAS, which was the subject of our research.

Diplen-denta C is a two-layer membrane consisting of combined hydrophilic and hydrophobic layers. The active ingredient "Solcoseryl" is included in the hydrophilic layer of the film. It has a multifunctional effect - it activates the transport of oxygen and nutrients, promotes their utilization by cells, enhances intracellular metabolism, stimulates cell regeneration and blood microcirculation.^{26,27} Hydrophilic layer (adhesive - tightly fixed to the oral mucosa, to the wound surface and isolated from the environment and preserved for 10 to 24 hours, preventing secondary infection of the wound, provides a therapeutic effect on the affected area for the entire period of treatment. Outer layer (hydrophobic)

prevents the release of film components into the oral cavity and the entry of oral fluid and microorganisms into the area of action of the film. The film is transparent and allows you to maintain oral hygiene for the entire period of treatment. The film is easy to use, patients can apply it independently under the supervision of a doctor.

The adhesive membrane “Diplen” has dissolving properties, since it contains food starch, cellulose, medical glue MK-1 and a medicinal ingredient, thereby simplifying its use.

Material and Methods

The clinical case presents the results of treatment and dental examination of a patient using the protective adhesive film “Diplen-S” in the complex therapy of chronic recurrent stomatitis (CRAS).

A 19-year-old patient came to the N1 University Dental Clinic of Yerevan State Medical University with complaints of pain and burning in the oral

mucosa, aggravated by eating, and the periodic appearance of painful ulcers, which disappeared on their own after 7-10 days.

Diagnostic methods included: clinical and laboratory methods, radiological methods, orthopantomography, assessment of periodontal and oral hygiene, general consultation with a doctor.

Exacerbations occur periodically 2-3 times a year. The cervical and occipital lymph nodes are enlarged and painful on palpation. Oral hygiene is unsatisfactory; there is an abundance of dental plaque, supra and subgingival dental deposits. The mucous membrane of the oral cavity is hyperemic and swollen, clearly defined ulcers (aphthae) are visible, up to 5 mm in diameter, covered with a grayish fibrous coating, surrounded by a reddish border, localized on the palate, lips and gums. In the area of the soft palate closer to the arch, where the aphthae were localized, a biological scab with purulent discharge is detected, as well as an unpleasant odor from the oral cavity (figures 1-5).

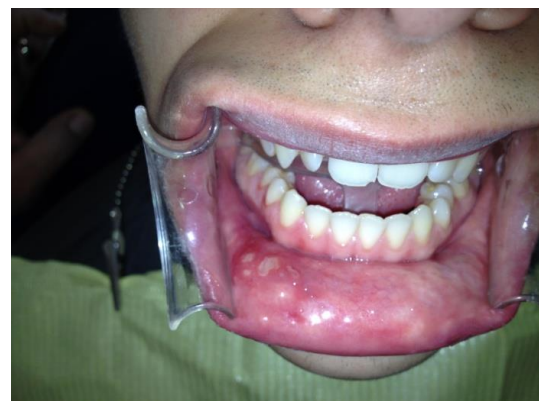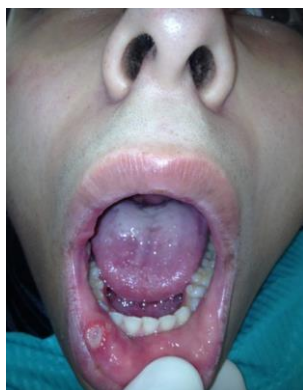
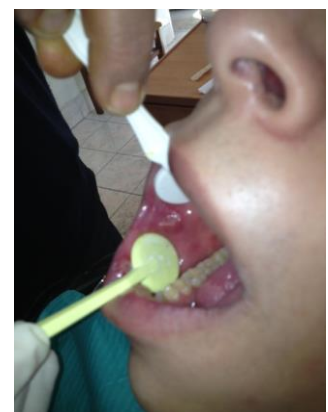

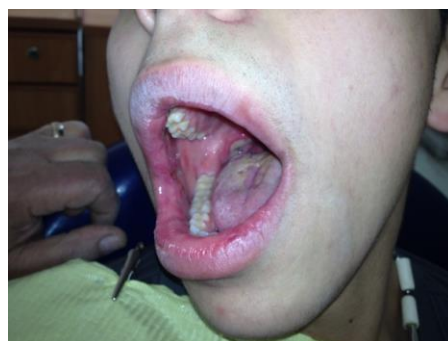
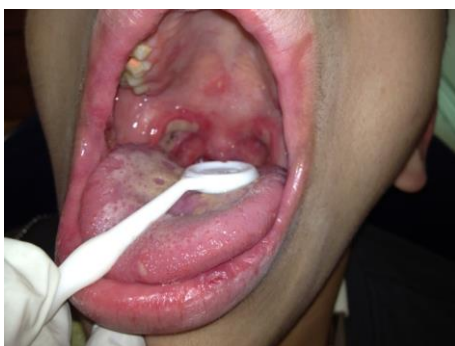Figure 1, 2. Aphtha of the mucous membrane of a sharply limited, round shape



Figures 3, 4, 5. Multiple aphthae on the palatine arches of the oral mucosa covered with fibrous plaque, aphthae with a grayish-yellow coating

The collected medical history includes the presence of chronic constipation. In this regard, the patient was referred to a gastroenterologist, where dysbiosis of the gastrointestinal tract was diagnosed. Among the laboratory methods, a general blood test was performed (leukocytosis, neutrophilosis, eosinophilia, shift of the blood count to the left were determined); bacteriological examination of the oral cavity, after which the patient was diagnosed with oral dysbiosis, with an increase in the number of *Candida albicans* fungi, a decrease in the number of lactobacilli and the presence of yeast-like drusen.

Bacteriological research was carried out over time before and after treatment. A bacteriological study was carried out dynamically before and after treatment according to the Zinovieva-Kagramanova method, which consisted of the following: on an empty stomach, to obtain a native picture (brushing teeth, rinsing with liquids, eating food was excluded), a biopsy sample with sterile cotton balls from the affected surface and oral mucosa from various topographic zones was transferred into sterile tubes and transported in a portable refrigerator from BOMANN to a microbiological laboratory within 1-2 hours, where the microbial factor, sensitivity to antibiotics and fungal infections were determined. The study was carried out in the bacteriological laboratory of the Department of Epidemiology of Yerevan State Medical University. M. Heratsi and in the laboratories of the 1st clinical hospital in Yerevan.

The treatment was as follows: Due to pain and difficulty eating, rinsing with a 0.5-1% solution of novocaine, anesthesin with glycerin (in a weight ratio of 1 to 10), and aerosol spray Lidocaine 10% 5-10 minutes before meals were prescribed.

Sanitation of the oral cavity was carried out, which included the removal of supra and subgingival dental plaque, and also anesthesia of the aphthae was performed, the purpose of which was to eliminate pain in the patient, anesthetic ointment (1:10) was used, as well as aerosol spray Lidocaine 10%. After which the fibrous films were removed with the help of enzymes (trypsin, chymotrypsin). The most pronounced aphthae were covered with Diplen adhesive films for a period of 12 to 24 hours (see Materials and methods of treatment). For local therapy, the following were prescribed: oxygen therapy, a solution of antiseptic drugs (a solution of hydrogen peroxide 1% and

potassium permanganate 1:5000, as well as chlorhexidine 0.06%), epithelializing drugs (methyluracil ointment 5%, Metrogyl-Denta, and an oil solution of retinol. The patient was simultaneously directed to physiotherapeutic treatment, namely hyperbaric oxygenation, which increases cellular metabolism and regeneration. In parallel, general treatment was carried out: desensitizing therapy - Zaditen 0.001 g 1 t.3 times a day; to increase the ability of blood serum to inactivate free histamine histaglobulin 2 ml per / m² 2 times a week for a course of 10-12 injections; vitamin complex Pangexavit, vitamin B 12, for injections using the type of mandibular and torus anesthesia, effect on the microflora. For the effective treatment of oral dysbiosis, in addition to antifungal drugs and drugs with a targeted effect on the microflora, immunomodulators were included, in particular Imudon (15) (topically, 6 tablets per day until completely dissolved in the oral cavity, course - 20 days).

Conclusion

According to the results of this study, despite the limitations of the study the use of the adhesive membrane "Diplen-S", which has therapeutic and protective properties with the possibility of including targeted drugs in its composition (taking into account the results of bacteriological research), largely leads to a reduction and disappearance of pain, accelerates the healing time and epithelization of aphthae, which gives us reason to recommend its use in the complex therapy of chronic recurrent aphthous stomatitis (RAS). The positive clinical results obtained, consisting in the absence of side effects and accelerated wound healing, are the basis for recommending the use of the Diplen adhesive film in the complex therapy and treatment of CRAS, as an innovative method in wide clinical practice.

Declarations

Conflict of interest and financial disclosure

The author declares that he has no conflict of interest and there was no external source of funding for the present study. None of the authors have any

relevant financial relationship(s) with a commercial interest.

Ethical approval

Research protocol was approved by the local Ethical Committee (2018/23) and in accordance with those of the World Medical Association and the Helsinki Declaration.

Informed consent

Informed consent was obtained from all individual participants included in the study.

Source of Funding

Non funding.

Availability of Data and Materials

Not applicable.

REFERENCES

1. Thomas C, Minty M, Vinel A, et al. Oral Microbiota: A Major Player in the Diagnosis of Systemic Diseases. *Diagnostics (Basel)*. 2021;11(8):1376. doi:10.3390/diagnostics11081376
2. Yeoh SC, Hua H, Yepes JF, Peterson DE. (2019). Oral Manifestations of Systemic Diseases and Their Treatments. *Contemporary Oral Medicine*. 2019;1523–1639. doi:10.1007/978-3-319-72303-7_18
3. Manoj MA, Jain A, Madtha SA, Cherian TM. Prevalence and risk factors of recurrent aphthous stomatitis among college students at Mangalore, India. *PeerJ*. 2023;11:e14998. doi:10.7717/peerj.14998
4. Babae N, Mansourian A, Momen-Heravi F, Moghadamnia A, Momen-Beitollahi J. The efficacy of a paste containing *Myrtus communis* (Myrtle) in the management of recurrent aphthous stomatitis: A randomized controlled trial. *Clin Oral Investig*. 2010;14(1):65-70. doi:10.1007/s00784-009-0267-3
5. Seyyedi SA, Olyae P, Fekrazad R, Partovi S, Baghizadeh Fini M. The Effect of Carbon Dioxide Laser on Aphthous stomatitis Treatment: A Double-Blind Randomized Clinical Trial. *J Lasers Med Sci*. 2020;11(S1):S67-S72. doi:10.34172/jlms.2020.S11
6. Altenburg A, El-Haj N, Micheli C, Puttkammer M, Abdel-Naser MB, Zouboulis CC. The treatment of chronic recurrent oral aphthous ulcers. *Dtsch Arztebl Int*. 2014;111(40):665-73. doi:10.3238/arztebl.2014.0665
7. Slebioda Z, Szponar E, Kowalska A. Etiopathogenesis of recurrent aphthous stomatitis and the role of immunologic aspects: literature review. *Arch Immunol Ther Exp (Warsz)*. 2014;62(3):205-15. doi:10.1007/s00005-013-0261-y
8. Preeti L, Magesh K, Rajkumar K, Karthik R. Recurrent aphthous stomatitis. *J Oral Maxillofac Pathol*. 2011;15(3):252-6. doi:10.4103/0973-029X.86669
9. Jurge S, Kuffer R, Scully C, Porter SR. Recurrent aphthous stomatitis. *Oral Dis*. 2006;12:1–21. doi:10.4103/0973-029X.86669
10. Scully C, Porter S. Oral mucosal disease: Recurrent aphthous stomatitis. *Br J Oral Maxillofac Surg*. 2008;46:198–206. doi:10.1016/j.bjoms.2007.07.201
11. Edgar NR, Saleh D, Miller RA. Recurrent Aphthous Stomatitis: A Review. *J Clin Aesthet Dermatol*. 2017;10(3):26-36
12. Kamat M, Datar U, Wadgave U, Varsha VK. Association of bedtime with recurrent aphthous stomatitis: A cross-sectional study among health-

- care professional students. *J Oral Maxillofac Pathol.* 2021;25(3):553-554. doi:10.4103/jomfp.jomfp_401_20
13. Preeti L, Magesh K, Rajkumar K, Karthik R. Recurrent aphthous stomatitis. *J Oral Maxillofac Pathol.* 2011;15(3):252-6. doi:10.4103/0973-029X.86669
14. Oh J, Lee JW, Chung KB, Bang D, Kim DY. Safety, Efficacy, and Drug Survival of Colchicine in Recurrent Aphthous Stomatitis in a Real-World Setting. *Ann Dermatol.* 2022;34(1):22-27. doi:10.5021/ad.2022.34.1.22
15. Bankvall M, Sjöberg F, Gale G, Wold A, Jontell M, Östman S. The oral microbiota of patients with recurrent aphthous stomatitis. *J Oral Microbiol.* 2014;6:25739. doi:10.3402/jom.v6.25739
16. Hijazi K, Lowe T, Meharg C, Berry SH, Foley J, Hold GL. Mucosal microbiome in patients with recurrent aphthous stomatitis. *J Dent Res.* 2015;94(3):87S-94S. doi:10.1177/0022034514565458
17. Dalessandri D, Zotti F, Laffranchi L, et al. Treatment of recurrent aphthous stomatitis (RAS; aphthae; canker sores) with a barrier forming mouth rinse or topical gel formulation containing hyaluronic acid: A retrospective clinical study. *BMC Oral Health.* 2019;19(1):153. doi:10.1186/s12903-019-0850-1
18. Ślebioda Z, Dorocka-Bobkowska B. Systemic and environmental risk factors for recurrent aphthous stomatitis in a Polish cohort of patients. *Postepy Dermatol Alergol.* 2019;36(2):196-201. doi:10.5114/ada.2018.74638
19. Manfredini M, Guida S, Giovani M, et al. Recurrent Aphthous Stomatitis: Treatment and Management. *Dermatol Pract Concept.* 2021;11(4):e2021099. doi:10.5826/dpc.1104a99
20. Picciani BL, Silva-Junior GO, Barbirato DS, Ramos RT, Cantisano MH. Regression of major recurrent aphthous ulcerations using a combination of intralesional corticosteroids and levamisole: a case report. *Clinics (Sao Paulo).* 2010;65(6):650-2. doi:10.1590/S1807-59322010000600015
21. Srivastava A, Gc S, Pathak S, et al. Evidence-based effectiveness of herbal treatment modality for recurrent aphthous ulcers - A systematic review and meta-analysis. *Natl J Maxillofac Surg.* 2021;12(3):303-310. doi:10.4103/njms.NJMS_249_20
22. Naniwa M, Nakatomi C, Hitomi S, et al. Analgesic Mechanisms of Steroid Ointment against Oral Ulcerative Mucositis in a Rat Model. *Int J Mol Sci.* 2021;22(22):12600. doi:10.3390/ijms222212600
23. Soliman HA, Mostafaa D. Clinical Evaluation of 660 nm Diode Laser Therapy on the Pain, Size and Functional Disorders of Recurrent Aphthous Stomatitis. *Open Access Maced J Med Sci.* 2019;7(9):1516-1522. doi:10.3889/oamjms.2019.268
24. Altenburg A, El-Haj N, Micheli C, Puttkammer M, Abdel-Naser MB, Zouboulis CC. The treatment of chronic recurrent oral aphthous ulcers. *Dtsch Arztebl Int.* 2014;111(40):665-73. doi:10.3238/arztebl.2014.0665
25. Belenguer-Guallar I, Jiménez-Soriano Y, Claramunt-Lozano A. Treatment of recurrent aphthous stomatitis. A literature review. *J Clin Exp Dent.* 2014;6(2):e168-74. doi:10.4317/jced.51401
26. Abakarova DS. Two-layer adhesive film Diplenda C: A new compound containing polymer base and active component Solcoseryl. *Stomatologiya (Mosk)* 2007;86(1):70-1.
27. Cervatiuc M, Vladimirovich Reshetov IV, Eldor J, Saakyan SV, Elyor Komilov ES. Reconstruction of eyelid defects using the diplene adhesive membrane. *Chinese Journal of Plastic and Reconstructive Surgery.* 2023;5(1):43-45. doi:10.1016/j.cjprs.2023.03.002

«ԴԻՊԼԵՆ-Ս» ԱԳՀԵԶԻՎ ԹԱՎԱՆԹԻ ՕԳՏԱԳՈՐԾՈՒՄԸ ԿՐԿՆՎՈՂ ԱՖՏՈՉ ՍՏՈՄԱՏԻՏԻ ՀԱՄԱԼԻՐ ԹԵՐԱՊԻԱՅԻ ՄԵՋ (ԿԼԻՆԻԿԱԿԱՆ ԳԵՊՔ).

Լյուդմիլա Տատինցյան,¹ Լազար Եսայան,² Գոհար Գևորգյան,³ Տաթևիկ Բարսեղյան,⁴ Վալերի Տատինցյան⁵

- ¹ Մ. Հերացու անվան Երևանի պետական բժշկական համալսարանի թերապևտիկ ստոմատոլոգիայի ամբիոնի դոցենտ
- ² Պրոֆեսոր, Մ. Հերացու անվան Երևանի պետական բժշկական համալսարանի թերապևտիկ ստոմատոլոգիայի ամբիոնի վարիչ
- ³ Մ. Հերացու անվան Երևանի պետական բժշկական համալսարանի թերապևտիկ ստոմատոլոգիայի ամբիոնի դասախոս
- ⁴ Մ. Հերացու անվան Երևանի պետական բժշկական համալսարանի մանկական ստոմատոլոգիայի և օրթոդոնտիայի ամբիոնի դասախոս
- ⁵ Մ. Հերացու անվան Երևանի պետական բժշկական համալսարանի թերապևտիկ ստոմատոլոգիայի ամբիոնի պրոֆեսոր

Ամփոփում

Կրկնվող աֆտոզ ստոմատիտը բերանի լորձաթաղանթի տարածված խոցային հիվանդություն է: Այս պաթոլոգիայի էթիոպաթոգենեզում չկա մեկ հայեցակարգ, որը կներկայացնի տվյալներ մեխանիզմների մասին, որոնք որոշում են քրոնիկ կրկնվող աֆտոզ ստոմատիտը, մեկնաբանելով բերանի խոռոչում տարբեր կլինիկական նշանների դրսևորումը: Աշխատանքը ներկայացնում է հիվանդի բուժման և ստամնաբուժական հետազոտության արդյունքները՝ օգտագործելով «Diplen-S» ադհեզիվ թաղանթը քրոնիկական կրկնվող աֆտոզ ստոմատիտի համալիր թերապիայի ժամանակ:

«Դիպլեն-Ս» ադհեզիվ թաղանթի օգտագործումը հանգեցրեց ցավի նվազման և անհետացման, ապաքինման ժամանակի արագացման և քրոնիկական կրկնվող աֆտոզ ստոմատիտի աֆթայի էպիթելիզացման՝ առանց կողմնակի ազդեցությունների:

Եզրակացություն. Ստացված դրական կլինիկական արդյունքները (վերքերի ապաքինումը արագացնելը) հիմք են հանդիսանում «Դիպլեն» ադհեզիվ թաղանթի օգտագործումը ԱՍՀ-ի քրոնիկական կրկնվող աֆտոզ ստոմատիտի համալիր թերապիայի և բուժման մեջ ստոմատոլոգի պրակտիկայում:

ПРИМЕНЕНИЕ АДГЕЗИВНОЙ МЕМБРАНЫ «ДИПЛЕН-С» В КОМПЛЕКСНОЙ ТЕРАПИИ РЕЦИДИВИРУЮЩЕГО АФТОЗНОГО СТОМАТИТА (КЛИНИЧЕСКИЙ СЛУЧАЙ).

Людмила Татинцян,¹ Лазар Есаян,² Гоар Геворгян,³ Татевик Барсегян,⁴ Валерий Татинцян⁵

- ¹ Доцент кафедры терапевтической стоматологии Ереванского государственного медицинского университета им. М. Гераци
- ² Профессор, заведующий кафедрой терапевтической стоматологии Ереванского государственного медицинского университета им. М. Гераци
- ³ Преподаватель кафедры терапевтической стоматологии Ереванского государственного медицинского университета им. М. Гераци
- ⁴ Преподаватель кафедры детской стоматологии и ортодонтии Ереванского государственного медицинского университета. М. Гераци
- ⁵ Профессор кафедры терапевтической и ортопедической стоматологии Ереванского государственного медицинского университета им. М. Гераци

Абстракт

Рецидивирующий афтозный стоматит (РАС) — распространенное язвенное заболевание слизистой оболочки полости рта. В этиопатогенезе данной патологии не существует единой концепции, которая бы излагала данные о пусковых механизмах, определяющих хронический рецидивирующий афтозный стоматит, трактуя констатацию проявления различных клинических признаков в полости рта. В работе представлены результаты лечения и стоматологического обследования пациента с использованием защитной адгезивной пленки «Диплен-С» в комплексной терапии хронического рецидивирующего стоматита (РАС).

Применение адгезивной пленки «Диплен-С» привело к снижению и исчезновению боли, ускорение сроков заживления и эпителизации афт без побочных эффектов.

Заключение: Полученные положительные клинические результаты, ускоряющие заживление ран, являются основанием для рекомендации использования адгезивной пленки «Диплен» в комплексной терапии и лечении РАС в практике стоматологии.



CASE REPORT

VASCULAR COMPLICATION AFTER LATERAL TEMPORAL LIFTING TECHNIQUE:
A CASE REPORT

Hadi M. Darawsheh,^{1*} T. Entel,² Z.K. Omarova,³ A.A. Batov,¹ I.M. Smilyk,⁴ A.V. Glinskii,⁴ F.I. Bakieva,⁵
R.J. Meylanova,¹ O.V. Kytko,¹ Yu.L. Vasil'ev¹

- ¹ N.V. Sklifosovsky Institute of Clinical Medicine, I.M. Sechenov First Moscow State Medical University (Sechenov University), 8-2 Trubetskaya St., 119991 Moscow, Russia
² Clinic of plastic surgery and cosmetology "Time of Beauty", 11-3 Mokhovaya St., 125009, Moscow, Russia
³ Clinic of Digital Dentistry and cosmetology by Dr. Omarov, 6-1, Broshevsky pereulok, 109147, Moscow, Russia
⁴ Institute of Anatomy "Skolkovo", Skolkovo, 42-1 Bolshoy Boulevard St., 121205 Moscow, Russia
⁵ Peoples' Friendship University of Russia named after Patrice Lumumba, 6 Miklukho-Maklaya, St., 117198, Moscow, Russia

* Corresponding author: Darawsheh H.M., maxillofacial surgeon, assistant of the Department of Operative Surgery and Topographic Anatomy, N.V. Sklifosovsky Institute of Clinical Medicine, I.M. Sechenov First Moscow State Medical University (Sechenov University);
e-mail: hadi.darawsheh@gmail.com

Received: Oct. 2, 2023; **Accepted:** Oct. 27, 2023; **Published:** Nov. 5, 2023

Abstract

Vascular complication after lateral temporal lifting technique with hyaluronic acid-based fillers may result from arterial occlusion by direct injection into the artery or embolization with the product, which is usually immediately manifested by acute pain and scarlet-red spots due to hemorrhagic blisters. Vascular complication can also result from venous occlusion caused by external compression of the vessel with soft tissue filler.

Vascular occlusion requires immediate treatment as the risk of tissue damage and skin necrosis increases with time.

In this paper we consider a clinical case of vascular complication after the technique of lateral temporal lifting of hyaluronic acid, manifested by painfulness of the area of hyaluronic acid injection, Livedo reticularis, alopecia, and treatment of this patient for 3 months.

Keywords: filler, hyaluronic acid, temporal fossa, volume deficit, cosmetic procedure, vascular complication

Introduction

Age-related facial changes include thinning of the epidermis, loss of skin elasticity, muscle atrophy, subcutaneous adipose and bone changes resulting in volume loss. As the temporal bones become more

concave, temporal muscle atrophies, and temporal adipose tissue volume decreases, the loss of volume results in an undesirable haggard appearance.^{1,2,3} By reshaping the temporal fossa and upper face with hyaluronic acid-based filler, cosmetic physicians can achieve a balanced and more youthful facial structure.

The joining of the scaly portion of the temporal bone, parietal bone, the greater wing of sphenoid bone, and the frontal bone at a point known as the pterion creates the osseous structure of the temporal region. The temporal fossa directly covers the scaly part of the temporal bone and is bordered below by the zygomatic arch of the temporal bone. Above these bones lie the periosteum, temporal muscle, and temporal fascia. Several important vessels are located in the periphery of the temporal region, including the zygomatico-orbital (medial), middle temporal and superficial temporal arteries (both lateral), all terminal branches of the external carotid artery, and the zygomaticofacial artery (medial), which branches distal to the internal carotid artery.⁴ These arteries are of particular concern to cosmetic physicians because injections into them can lead to vascular complications, particularly filler embolism.⁵

Complications of filler injection into the temporal fossa include bruising, soreness, edema, hypercorrection, and discomfort with chewing, forming a headache trigger.^{6,7} Serious complications include infection, foreign body granuloma, intravascular necrosis, and ocular artery embolization.^{8,9,10,11} Clinicians should be aware of possible complications and promptly provide treatment.

Clinical case

Vascular complication after lateral temporal elevator technique.

We performed a study of the temporal region on cadavers (Institute of Anatomy, Skolkovo) in the context of the obtained complication. For this purpose, a stained silicone paste was injected into the external carotid artery to visualize the vascular bed. Further, by layer-by-layer dissection, the temporal region was opened and potential anastomoses with the posterior auricular artery were identified, as well as the microvasculature in the subcutaneous layer, which, when compressed, is involved in the formation of the livedo reticularis.

On March 8, 2023 at 12:00 p.m., the patient underwent correction of the lateral temporal area with hyaluronic acid-based filler in the B. UP technique (0.5 ml on both sides) and filling of the temporal area with the interfascial technique (0.5 ml on both sides).

The instrument used was a 22G/50 MM cannula. Protocol for correction of the lateral temporal zone: the point for cannula entry - 1-1.5 cm in front of the antilobium, skin puncture and advancement of the cannula 1.5 cm beyond the hair growth line, injection of filler in several boluses next to each other (total volume of 0.5 ml on one side). The level of injection was subcutaneous adipose tissue (Figure 1 A). Half an hour later, patient returned with a complaint of point pain "on the top of the head" (on the border between the parietal and frontal areas) and skin discoloration of the temporal area.

Half an hour after admission, the patient returns with a complaint of acute pain "on the top of the head" (on the border between the parietal and frontal areas) and a change in skin color of the temporal area. Objectively: Livedo reticularis (vascular spots of reddish-blue color, forming a reticular pattern); painful spot on the parietal area. The skin color of the scalp of the temporal area was not changed (Figure 1 B).

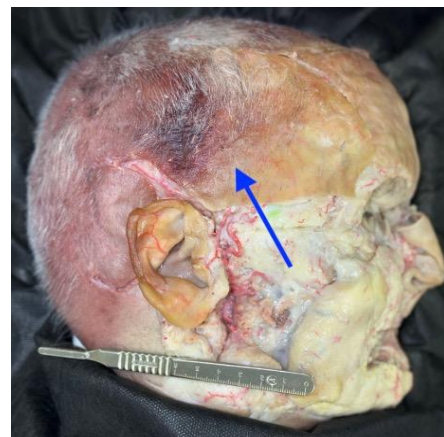


Figure 1 A. Planned temporal zone correction

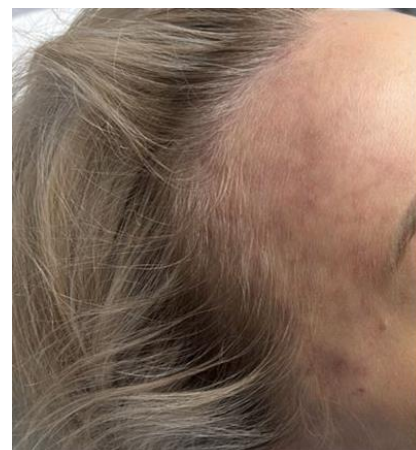

Figure 1 B. Livedo reticularis on the patient half an hour after the end of the procedure

Treatment of complication: March 8 at 12:45 p.m. bovyhaluronidase azoximer 3000 IU (3 ml saline solution + 0.5 ml dexamethasone) three times every hour. Injections on the entire area of the color-changed skin and on the skin of the scalp of the temporal area on the affected side with transition to the parietal area to the painful point in 1 cm intervals. Local cooling. Sildenafil a single dose. Pentoxifylline in tablets immediately and for 5 days, acetylsalicylic acid 100 mg. Local application of heparin sodium ointment (Figure 2 A).

The patient flew the same evening to the other side of the country. All treatment was administered remotely, the treatment was performed by a physician in another city.

March 9 in the morning complaints of skin numbness of the temporal scalp, soreness from hematomas (Figure 2 B).

Figure (2 A) - Complication treatment on the day of the procedure; (2 B) - Complaints of numbness of the skin of the scalp of the temporal area, soreness from hematomas on the next day after the procedure.

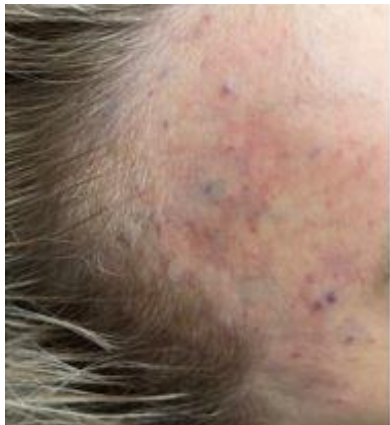

Figure 2 A. *Complication treatment on the day of the procedure*

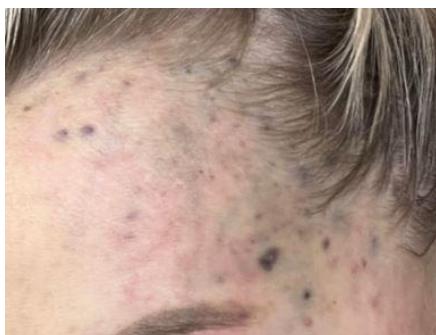

Figure 2 B. *Complaints of numbness of the skin of the scalp of the temporal area, soreness from hematomas on the next day after the procedure*

Treatment

Continuation of bovyhaluronidase azoximer - 3000 IU, pentoxifylline by drop intravenous infusion for 4 days, ciprofloxacin + tinidazole 500/600 mg - 1 tablet 2 times a day, eubiotics - 2 capsules 3 times a day. (Figure 3 A, B).

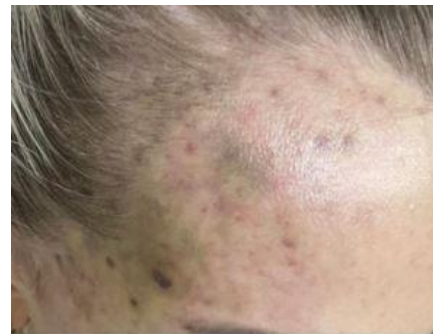

Figure 3 A. *The 4th day of the vascular complication treatment*

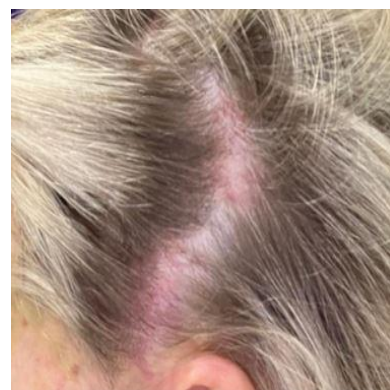

Figure 3 B. *The 6th day of the vascular complication treatment*

From March 15, hyperbaric chamber every day for 7-10 days; ibuprofen 200 mg 3 times a day.

The results of treatment are presented in the figures (Figure 4 A, B, C).

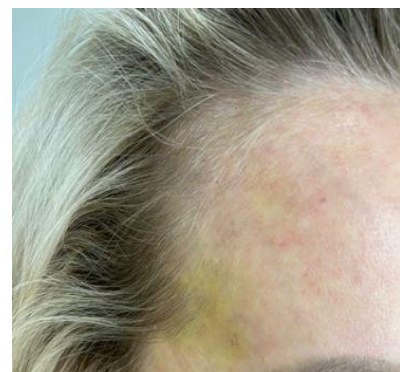

Figure 4 A. *The 10th day of the vascular complication treatment*

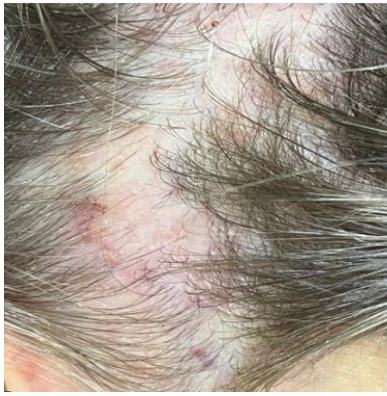

Figure 4 B. The 12th day of the vascular complication treatment

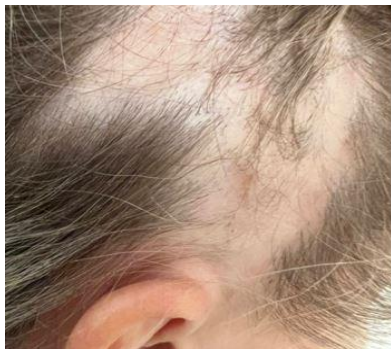

Figure 4 C. 36 days after the procedure

From May 15, Minoxidil 5% 1 -2 times a day, 1 month

By the end of June, the patient stopped external treatment as hair growth was fully restored (Figure 5).



Figure 5. After 3 months of treatment, hair growth has been restored

Discussion

The patient was diagnosed with embolization of the superficial temporal artery with migration to the

temporal branch of the superficial temporal artery, post-ischemic alopecia. The filler was injected not into the subcutaneous adipose tissue but into the vascular network of the superficial temporal artery (Figure 6 A). The red dot in the figure indicates the position of the superficial temporal artery relative to the temporo-parietal fascia (Figure 6 B).

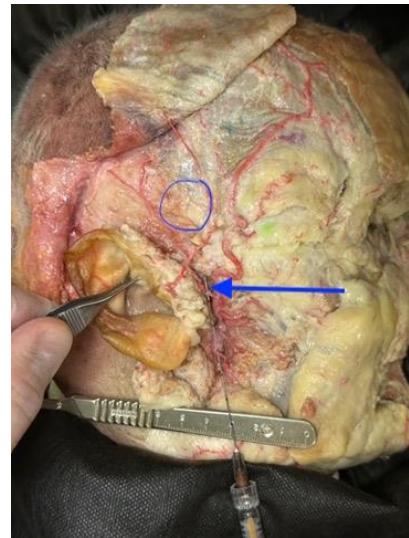


Figure 6 A. Location of the superficial temporal artery branch

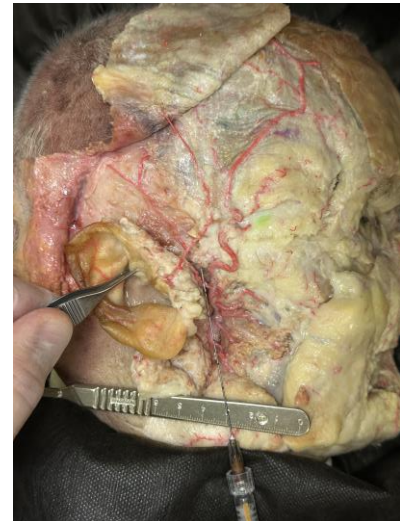

Figure 6 B. Position of the superficial temporal artery that has been infiltrated by filler

The subcutaneous temporal region is an easily accessible plane for temporal volume augmentation. The layers of the temporal fossa include the skin, subcutaneous adipose tissue, superficial temporal fascia, deep temporal fascia, temporal muscle, pericranium, and temporal bone. Age-related changes, including thinning of subcutaneous adipose tissue and

the temporal muscle, affect each of these structures to form temporal hollowing.

Several authors have reported excellent results after injection into the subcutaneous and deep subcutaneous planes, as well as the plane immediately beneath the superficial temporal fascia,¹² but complications have also been reported. The injection planes correspond to the cutaneous and superficial arterial network of the temporal fascia. Putative pathologies of the superficial temporal artery that have been reported after cosmetic injections in this area include branch retinal artery occlusion, pseudoaneurysm, and alopecia.^{13,14,15,16,17} Anastomoses between the superficial facial, deep facial, and deep muscular arterial networks in this region can cause retrograde intraarterial flow of hyaluronic acid gel in the superficial temporal artery.¹²

Another mechanism of local ischemic complications may involve vasoconstriction. The gel may fuse in the perivascular fibrous septa of subcutaneous or fascial tissues, constricting the vessel.¹⁸

Juhász and Marmur (2015)⁶ noted that intravascular necrosis after filler injection occurs due to accidental intraarterial injection causing drug-induced skin embolism. If dermal angiosomes are disrupted, full-thickness necrosis may occur. Risk factors for intravascular necrosis include injection of a large amount of filler at a single site, deep injection, and use of a sharp needle. The authors note that intravascular necrosis can manifest in a variety of ways. Intense pain immediately after injection may be disguised by the effects of lidocaine. However, signs of pallor, a reticulated skin pattern, or scarlet-red patches due to hemorrhagic blisters (which may persist for up to 72 hours) may appear shortly after injection. Necrosis occurs between 2 and 7 days after injection. It is important to recognize intravascular necrosis as early as possible and, if possible, inject hyaluronidase, an enzyme used in cosmetology to eliminate unpleasant complications after injections with hyaluronic acid medications.

Conclusions

Vascular occlusion has been identified as the most serious and dangerous early complication of aesthetic treatment, and its incidence appears to be increasing. Unintentional injection of hyaluronic acid-based filler into the arterial circulation occurs, which, unrecognized, is irreparably associated with vascular complications. It is worth noting that the localization of complications, regardless of injection site, is the same and accounts for only five areas of the face, all within the functional angiosome of the facial or ocular artery. Cosmetic physicians should be aware of the possible complications associated with filler injection into this sensitive area and promptly administer treatment.

Declarations

Conflict of interest and financial disclosure

The author declares that he has no conflict of interest and there was no external source of funding for the present study. None of the authors have any relevant financial relationship(s) with a commercial interest.

Ethical approval

Research protocol was approved by the local Ethical Committee (2018/23) and in accordance with those of the World Medical Association and the Helsinki Declaration.

Informed consent

Informed consent was obtained from all individual participants included in the study.

Source of Funding

Non funding.

Availability of Data and Materials

Not applicable.

REFERENCES

1. Hernandez CA, Schneider C, Gold DMH, et al. After the temporal lifting technique-what comes next? *J. Cosmet. Dermatol.* 2021;20(12):3857-3862. doi:10.1111/jocd.14247
2. Darawsheh HM, Mellin RV, Aydemirova ZB, et al. Morphological and morphometric variations of the lower jaw: An observational typology. *Clinical Dentistry (Russia)*. 2023;26(1):114-120 doi:10.37988/1811-153X_2023_1_114
3. Darawsheh HM, Vasil'ev UL, Panin AM, Kuznetsov AI, Heigetyan AV, Karammaeva MR. Morphometric study of the condylar process of the mandible. *Clinical Dentistry (Russia)*. 2022;25(2):28-33. doi:10.37988/1811-153X_2022_2_28
4. Sykes JM. Applied anatomy of the temporal region and forehead for injectable fillers. *J. Drugs Dermatol.* 2009;8(10):24-7. PMID: 19891119
5. Funt D, Pavicic T. Dermal fillers in aesthetics: an overview of adverse events and treatment approaches. *Clinical, cosmetic and investigational dermatology*. 2013;6:295-316. doi:10.2147/CCID.S50546
6. Juhász MLW, Marmur ES. Temporal fossa defects: techniques for injecting hyaluronic acid filler and complications after hyaluronic acid filler injection. *Journal of Cosmetic Dermatology*. 2015;14(3),254-259. doi:10.1111/jocd.12155
7. Casabona G, Frank K, Moellhoff N, et al. Full-face effects of temporal volumizing and temporal lifting techniques. *J. Cosmet. Dermatol.* 2020;19(11):2830-2837. doi:10.1111/jocd.13728
8. Cotofana S, Gaete A, Hernandez CA, et al. The six different injection techniques for the temple relevant for soft tissue filler augmentation procedures. Clinical anatomy and danger zones. *J. Cosmet. Dermatol.* 2020;19(7):1570-1579. doi:10.1111/jocd.13491
9. Wang HC, Yu N, Wang X, et al. Cerebral Embolism as a Result of Facial Filler Injections: A Literature Review. *Aesthet. Surg. J.* 2022;15;42(3):162-175. doi:10.1093/asj/ sjab193
10. Zhang LX, Lai LY, Zhou GW, et al. Evaluation of Intraarterial Thrombolysis in Treatment of Cosmetic Facial Filler-Related Ophthalmic Artery Occlusion. *Plast. Reconstr. Surg.* 2020;145(1):42-50. doi:10.1097/PRS.000000 0000006313
11. Thanasarnaksorn W, Cotofana S, Rudolph C, Kraisak P, Chanasumon N, Suwanchinda A. Severe vision loss caused by cosmetic filler augmentation: Case series with review of cause and therapy. *J. Cosmet. Dermatol.* 2018;17(5):712-718. doi:10.1111/jocd.12705
12. Chundury RV, Weber AC, McBride J, Plesec TP, Perry JD. Microanatomical location of hyaluronic acid gel following injection of the temporal hollows. *Ophthalmic Plastic & Reconstructive Surgery*. 2015;31(5):418-420. doi:10.1097/IOP.0000000000000507
13. Kapoor KM, Kapoor P, Heydenrych I, Bertossi D. Vision loss associated with hyaluronic acid fillers: a systematic review of literature. *Aesthetic plastic surgery*. 2020;44:929-944. doi:10.1007/s00266-019-01562-8
14. Skaf GS, Domloj NT, Salameh JA. Pseudoaneurysm of the superficial temporal artery: A complication of botulinum toxin injection. *Aesthetic Plast Surg.* 2012;36:982-5. doi:10.1007/s00266-012-9881-6
15. Gan SD, Itkin A, Wolpowitz D. Hyaluronic acid-induced alopecia: a novel complication. *Dermatol. Surg.* 2013;39:1724-5. doi:10.1111/dsu.12333
16. Darawsheh HM, Safronova AA, Vasil'ev YL, et al. Choosing the optimal mandible position for inferior alveolar nerve block (IANB) using finite element analysis. *Ann Anat.* 2023;247:152055. doi:10.1016/j.aanat.2023.152055
17. Vasil'ev Y, Diachkova E, Darawsheh H, et al. Cross-Sectional Study on the Comparative Assessment of Mandibular Anesthesia (Inferior

Alveolar Nerve Blockage) Manual Skills Shaping among Dentists on Plastic and Biomaterial Models. *Dent. J.* 2022;10:124. doi:10.3390/dj10070124

18. King M, Walker L, Convery C, Davies E. Management of a vascular occlusion associated with cosmetic injections. *The Journal of clinical and aesthetic dermatology.* 2020;13(1):e53–e58.

ԱՆՈՌԱՅԻՆ ԲԱՐԴՈՒԹՅՈՒՆ ԿՈՂԱՅԻՆ ՔՈՒՆՔԱՅԻՆ ԲԱՐՁՐԱՅՄԱՆ ՏԵԽՆԻԿԱՅԻՑ ՀԵՏՈՒ ԿԼԻՆԻԿԱԿԱՆ ԴԵՊԵ

Դարաշե Խ.Մ.,¹ Էնթել Տ.,² Օմարովա Չ.Կ.,³ Բատով Ա.Ա.,¹ Սմիլիկ Ի.Մ.,⁴ Գլինսկի Ա.Վ.,⁴ Բակիևա Ֆ.Ի.,⁵ Մեյլանովա Ռ.Դ.,¹ Կիտկո Օ.Վ.,¹ Վասիլև Յու.Լ.¹

- ¹ Ն.Վ. Սկլիֆոսովսկու անվան կլինիկական բժշկության ինստիտուտ, Ի.Մ. Մեչենովի անվան Մոսկվայի առաջին պետական բժշկական համալսարան (Մեչենովի համալսարան), Մոսկվա, Ռուսաստան
- ² Պլաստիկ վիրաբուժության և կոսմետոլոգիայի «Գեդեցկոյան ժամանակ» կլինիկա, Մոսկվա, Ռուսաստան
- ³ Թվային ստոմատոլոգիայի և կոսմետոլոգիայի կլինիկա, Մոսկվա, Ռուսաստան
- ⁴ Անատոմիայի ինստիտուտ «Սկոլկովո», Մոսկվա, Ռուսաստան,
- ⁵ Պատրիս Լումուսբայի անվան Ռուսաստանի ժողովուրդների բարեկամության համալսարան, Մոսկվա, Ռուսաստան

Ամփոփում

Անոթային բարդությունը հիալուրոնաթթվով լցոնիչներով կողային քունքային բարձրացման տեխնիկայից հետո կարող է առաջանալ ուղղակի ներարկումով զարկերակ՝ զարկերակային խցանման հետևանքով կամ էմբոլիզացիայից, որը սովորաբար դրսևորվում է անմիջապես սուր ցավով և մանուշակագույն-կարմիր բծերով հեմոռագիկ բշտիկների պատճառով: Անոթային բարդություն կարող է առաջանալ նաև երակային խցանման հետևանքով, որը պայմանավորված է փափուկ հյուսվածքների լցոնիչով անոթի արտաքին սեղմմամբ:

Անոթային խցանումը պահանջում է անհապաղ բուժում, քանի որ ժամանակի ընթացքում մեծանում է հյուսվածքների վնասման և մաշկի նեկրոզի վտանգը:

Աշխատանքը ուսումնասիրում է անոթային բարդության կլինիկական դեպքը՝ հիալուրոնաթթվով կողային քունքային բարձրացման տեխնիկայից հետո, որը դրսևորվում է որպես ցավ հիալուրոնաթթվի դեղամիջոցի ներարկման, լիդոկայնի, հետագայում ալոպեկիայի և պահանջվում է հիվանդի բուժումը 3 ամսվա ընթացքում:

СОСУДИСТОЕ ОСЛОЖНЕНИЕ ПОСЛЕ ТЕХНИКИ ЛАТЕРАЛЬНОГО ВИСОЧНОГО ЛИФТИНГА: КЛИНИЧЕСКОЙ СЛУЧАЙ

Дарауше Х.М.,¹ Энтел Т.,² Омарова З.К.,³ Батов А.А.,¹ Смилык И.М.,⁴ Глинский А.В.,⁴ Бакиева Ф.И.,⁵ Мейланова Р.Д.,¹ Кытко О.В.,¹ Васильев Ю.Л.¹

- ¹ Институт клинической медицины имени Н.В. Склифосовского, Первый Московский государственный медицинский университет имени И.М. Сеченова (Сеченовский университет), Москва, Россия
- ² Клиника пластической хирургии и косметологии «Время красоты», Москва, Россия
- ³ Клиника цифровой стоматологии и косметологии доктора Омарова, Москва, Россия

⁴ Институт анатомии «Сколково», Сколково, Москва, Россия

⁵ Российский университет дружбы народов имени Патриса Лумумбы, Москва, Россия

Аннотация

Сосудистое осложнение после техники латерального височного лифтинга филлерами на основе гиалуроновой кислоты может возникнуть в результате тромба артерий путем прямой инъекции в артерию или эмболизации продуктом, что обычно сразу проявляется острой болью и багрово-красными пятнами из-за геморрагических пузырей. Сосудистое осложнение также может быть результатом венозного тромба из-за внешней компрессии сосуда наполнителем мягких тканей.

Сосудистый тромб требует немедленного лечения, так как со временем возрастает риск повреждения тканей и некроза кожи.

В работе рассмотрен клинический случай сосудистого осложнения после техники латерального височного лифтинга гиалуроновой кислоты, проявившийся болезненностью зоны введения препарата гиалуроновой кислоты, ливедо, в дальнейшем аллопецией, и лечение данной пациентки в течение 3-х месяцев.



PILOT STUDY

EFFECTS OF RECOMBINED HUMAN BONE MORPHOGENETIC PROTEIN-2 AS ALVEOLAR RIDGE PRESERVATION ON PAIN REDUCTION AND SOFT TISSUE HEALING PROCESS: A SPLIT MOUTH DESIGNED PILOT STUDYJean Nassar,¹ Georges Aoun,^{2*} Linda Abou-Abbas,³ Mirna Sabra³¹ Department of Periodontology, Faculty of Dental Medicine, Lebanese University² Department of Oral Medicine and Maxillofacial Radiology, Faculty of Dental Medicine, Lebanese University³ Neuroscience Research Center, Faculty of Medical Sciences, Lebanese University

* Corresponding author: Professor Georges Aoun, Department of Oral Medicine and Maxillofacial Radiology, Faculty of Dental Medicine, Lebanese University, Beirut, Lebanon;

e-mail: dr.georges@aoun@gmail.com;

ORCID ID: <http://orcid.org/0000-0001-5073-6882>

Received: Oct. 2, 2023; **Accepted:** Oct. 27, 2023; **Published:** Nov. 5, 2023

Abstract

Background: The alveolar ridge undergoes physiological bone resorption following tooth extraction. Several alveolar ridge preservation (ARP) techniques have been researched and developed in an effort to reduce this process and maintain a favorable volume and morphology of the alveolar ridge for appropriate implant placement.

Bone morphogenetic proteins (BMPs) are proteins derived from a subgroup of the transforming growth factor β family that accelerates ossification by controlling essential factors of the bone induction cascade, resulting in the proliferation of osteoblasts from mesenchymal stem cells and the biosynthesis of bone matrices. One of these BMPs is recombinant human bone morphogenetic protein-2 (rhBMP-2) that has been authorized to be used for ARP.

Objective: This study aims to evaluate the effect of rhBMP-2 on the healing process and the level of pain following dental extraction.

Methods: In this split-mouth pilot study, 11 patients underwent extractions of a minimum of two teeth, and randomly, one of the alveolar sockets was filled with a hemostatic sponge while the other was filled with a hemostatic sponge embedded with rhBMP-2. Both sockets were sutured using the X technique. Wound healing measurements were done on days 3, 7, and 14, and each participant was requested to document his pain experience using the Numerical Rating Scale (NRS).

Results: In accordance with clinical evidence, it was observed that the mean pain score was at its peak on day 0 and progressively diminished in the subsequent days. Notably, this decline was more pronounced in the rhBMP-2 group compared to the control group. Importantly, a statistically significant reduction in pain level was detected on day 3 within the rhBMP-2 group, in contrast to the control group (P-value < 0.05). This indicated that the application of rhBMP-2 led to a noteworthy and meaningful alleviation of pain on the third day after treatment, surpassing the impact observed in the control group. For the wound healing changes, it uncovered statistically significant mean differences across various time intervals: day 0 and day 3, day 0 and day 7, day 0 and day 14, day 3 and day 7, and day 7 and day 14 (P-value < 0.0001). These significant differences strongly suggest dynamic changes in wound closure rates over time. Furthermore, the observed differences were more pronounced in the rhBMP-2-treated group compared to the control group. This augmentation of differences indicates that the utilization of rhBMP-2 for ARP within a fresh socket site resulted in a heightened acceleration of the wound healing process.

Conclusion: Our results suggest that rhBMP-2 can decrease post-operative pain after tooth extraction and accelerate the soft tissue healing process.

Keywords: Human bone morphogenetic protein-2; rhBMP-2; alveolar ridge preservation; pain reduction; soft tissue healing.

Introduction

Tooth extraction affects masticatory efficiency and causes homeostatic and structural changes in periodontal tissues, leading to alveolar ridge resorption that may jeopardize esthetics and complicate functional rehabilitation.¹⁻³ Alveolar ridge preservation (ARP) is a method of decreasing bone resorption and facilitating prosthetically-driven implant placement by eliminating the need for bone augmentation procedures.⁴ It also reduces the risk of complications and the cost of the treatment.⁵

The use of autogenous bone for alveolar augmentation and preservation has been considered the gold standard.⁶ However, complications, including donor site comorbidity, a limited amount of harvest, resorption after grafting, and difficulty in harvesting because of anatomical and underlying diseases make this technique difficult. To avoid some of these complications, autogenous bone has been replaced by allogenic, xenogeneic, and alloplastic materials, but all of them are osteoconductive materials. Recently, many efforts have been made to improve bone regeneration by combining various growth factors with bone substitutes.⁷

Bone morphogenetic protein (BMP), which was discovered by Urist in 1965,⁸ has been extensively investigated in the field of bone regeneration as an effective enhancer of osteogenesis. BMP belongs to the large transforming growth factor- β (TGF- β) superfamily. It has high osteoinductive capacity resulting from the chemotaxis, proliferation, and differentiation of mesenchymal stem cells. Recombinant human BMP-2 (rhBMP-2) is a BMP-2 that can be produced with recombinant technology. It is highly osteoinductive and has been used to enhance bone regeneration and ARP.^{9,10}

Post-teeth extraction pain is common; however, the pain is a subjective response that is registered as a conscious experience unique to the patient.¹¹

After tooth extraction, the healing process begins with a blood clot formation to fill the socket and fulfill homeostasis and coagulation.¹² From the first day, erythrocytes and mesenchymal cells take place in the apical zone, and granulation tissue gradually replaces the clot, followed by fibrous and osteogenic tissues.¹³ After the first month of the extraction, the site is full of trabecular bone that matures gradually.¹⁴ During the

healing process, dimensional alterations have been reported to cause a ridge width reduction of up to 50% during the first year following tooth loss in premolar and molar sites, where two-thirds of the total changes take place within the first 3 months post-extraction.¹⁵ A systematic review showed a loss of 2.6–4.5 mm in width and 0.4–3.9 mm in height of healed sockets.¹⁰

Many studies have compared bone resorption, pain management, and wound healing at the extraction site using different techniques of ridge preservation. A study conducted by Ma et al.¹⁶ evaluating the effect of interactions between neuropeptides and rhBMP-2 on human osteoblasts revealed that rhBMP-2 enhanced gap junction intercellular communication between osteoblasts in vivo and could be physiologic activators of bone formation through regulating the proliferation and activation of osteoblasts by promoting signal transmission among bone cells. To our knowledge, no other study has compared hemostatic sponges embedded with rhBMP-2 with regular hemostatic sponges in socket preservation techniques. Our primary objective is to determine the effect of rhBMP-2 on the pain during the healing process, as well as to evaluate the soft tissue healing in both techniques.

Materials and methods

This study has been approved by the Neuroscience Research Committee at the Lebanese University Faculty of Medical Sciences. The surgeries were made by JN from February until June 2023 under the recommendations of the Declaration of Helsinki for human subjects.

Trial design and participants

This is a split-mouth clinical trial design with a minimum of two teeth to be extracted for each patient from both sides of the jaw to compare the outcome of the two techniques on ridge preservation. We included in this study male and female healthy patients, aged 18 to 70 years old. Exclusion criteria were: a) heavy smokers (≥ 20 cigarettes per day); b) HIV-positive patients; c) patients taking bisphosphonate; d) pregnant and lactating women; e) patients with systemic disorders (diabetes mellitus, hyperthyroidism, etc.) interfering with the healing

process. Patients needing extraction of wisdom teeth were also excluded from the study.

Study outcome

The Numerical Rating Scale (NRS) was used to subjectively evaluate the postoperative pain of the patient on days 1, 3, and 7. It has good sensitivity and generates data that can be statistically analyzed for audit purposes. The NRS is an 11-point scale where the end points are the extremes of no pain and pain as bad as it could be, or worst pain. The numbers are often enclosed in boxes, and the scale is referred to as

an 11-box scale depending on the number of levels of discrimination offered to the patient.¹⁷ The baseline pain perception was recorded in the clinic before the treatment, and the pain perception was noted before any analgesic medication was taken.

For the soft tissue healing, we used the periodontal probe Kohler® (Germany) to measure the distance between the soft tissue margins. On the day of the extraction, after pulling out the tooth, the distance between soft tissue margins was measured bucco-lingually and palatally on days 0, 3, 7, and 14 after surgery (Figure 1).

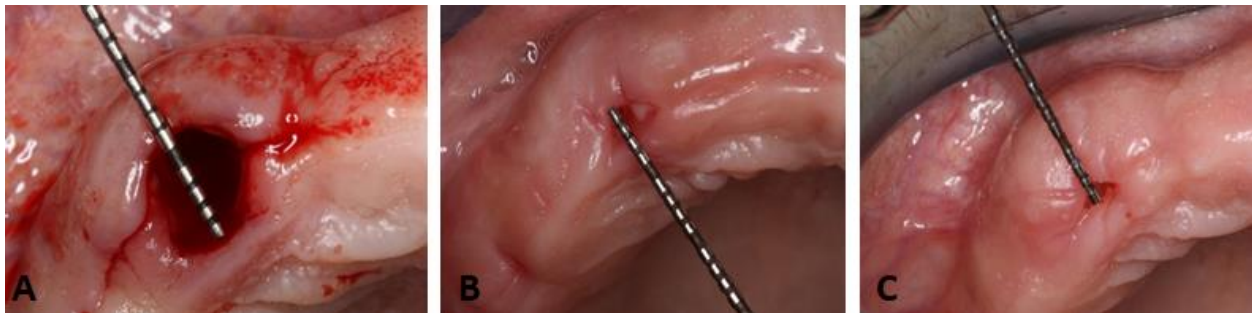

Figure 1. Soft tissue healing measurement

A) bucco-palatal distance measure at day 0 after tooth extraction;

B) bucco-palatal distance measure at day 7 after surgery;

C) bucco-palatal distance measure at day 14 after surgery

Preoperative phase

Each patient included in the study was informed about details concerning the surgery, and a written consent form containing information about the procedure, the product used, and the benefits and precautions of the surgery was carefully read and signed by the patient. All patients underwent intraoral photographs before, during, and after the surgical procedure. In addition, periapical X-rays were made at the sites of extractions. Moreover, the patient was not informed about the exact site imbedded with rhBMP-2, and this was essential for precise results for the pain scale later on.

Surgical phase

Under infiltration anesthesia, using Septanest® (Septodont, France), which contains articaine hydrochloride with 1:100,000 adrenaline, a minimally flapless invasive extraction was made to preserve the

surrounding soft and hard tissues. A syndesmotomy using a surgical blade (No. 15C) for intrasulcular incision was performed to preserve the papilla and the gingival margins.

When the tooth of interest had one root, we used the periotome after the syndesmotomy, thus trying to mobilize the tooth. Then, we made slow movements of rotation and pulling using adequate forceps to cut the fibers in the periodontium and pull out the tooth from the socket with minimum damage to the surrounding soft and hard tissues (Figure 2).

When the extracted tooth had multiple roots, a carbide burs on a high-speed turbine was used to section the tooth into two or three parts, thereby preserving as much as possible the surrounding bone and soft tissues, and the roots were finally pulled out of the socket without any damage (Figure 3).

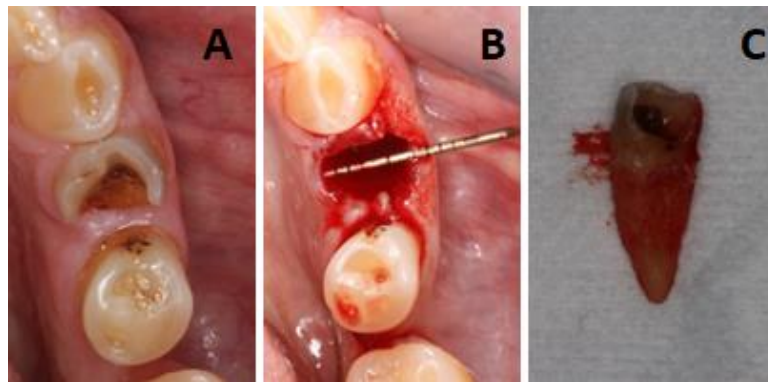


Figure 2. Atraumatic extraction of a single root
A) pre-operative image of the lower right first premolar;
B) atraumatic extraction of the lower right first premolar showing the continuity and integrity of the soft tissues around it;
C) the lower right first premolar pulled out from the socket

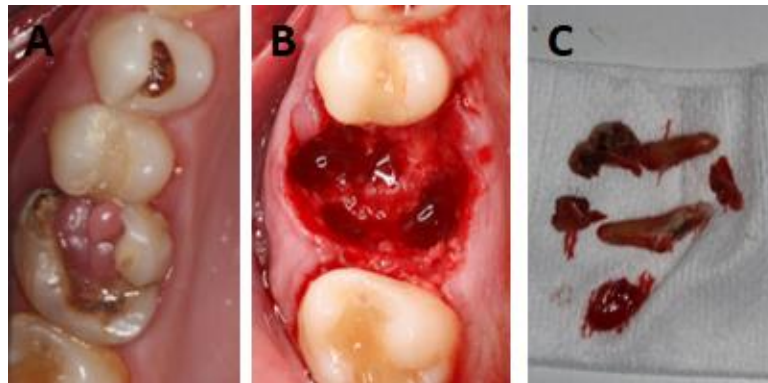


Figure 3. Atraumatic extraction of multiple roots with sectioning of the tooth
A) pre-operative image of the upper right first molar;
B) atraumatic extraction of the upper right first molar, showing the continuity and integrity of the soft and hard tissues;
C) showing roots sectioned and pulled out from the sockets

After pulling out the teeth, we used curettes of small and medium sizes to eliminate all the remaining fibers of the periodontal ligament and the granulation tissues. The remaining bony walls were checked using a probe. Finally, we irrigated the socket with a sodium chloride solution, and randomly and based on

allocation concealment, one of the alveolar sockets was filled with the standard hemostatic sponge, while the other was filled with hemostatic sponge embedded with rhBMP-2, followed by a conventional X suture (Figure 4).

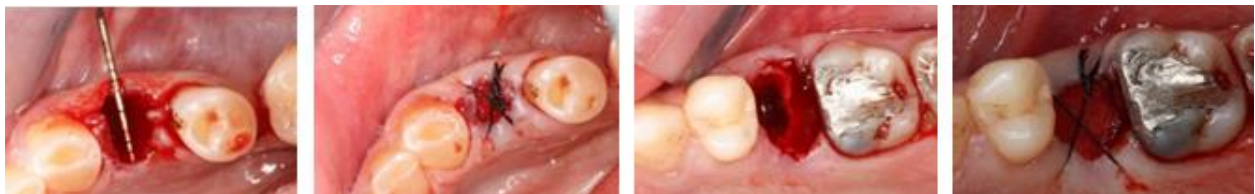

Figure 4. Extraction and insertion of the hemostatic sponge embedded with rhBMP-2 on the first side and extraction and insertion of the standard hemostatic sponge on the second side followed by a conventional X suture

Postoperative phase

The patients were instructed on proper brushing, flossing, and using the mouthwash. In fact, each patient was given Eludrilpro® (Pierre Fabre medicament production, France), which is a mouthwash containing 0.5 ml of chlorhexidine digluconate and 0.5 g/100 ml of chlorobutanol hemihydrate. They were advised to use it twice per day for 10 days.

Statistical analysis

Data entry and analysis were performed using the statistical software SPSS, version 22.0. Descriptive statistics were reported using means and standard deviations (SD) for continuous variables and frequency with percentages for categorical variables. The two-way repeated measures ANOVA test was used to compare the mean pain scores between the rhBMP-2 side and the control side, and the significance level was set at 0.05.

The one-way repeated measures ANOVA test was used to compare the mean bucco-palatal distance of soft tissue margins between the rhBMP-2 side and the

control side, and the significance level was set at 0.0001.

Results

A total of 30 patients were assessed for participation. Of these patients, 10 didn't meet our inclusion criteria, 5 refused to participate, and 4 didn't come to the follow-up appointment. The remaining 11 patients fulfilled all the inclusion criteria. The total sample included 6 men (54.5%) and 5 women (45.5%). The study patient's age range varied between 24 and 64 years, and the mean age was 49.4±11.14.

The two-way repeated measures ANOVA statistical test was used, and the analysis revealed that there were no statistically significant differences in the mean pain scores at day 0 between the rhBMP-2 side and the control side (P-value = 0.641). Moreover, the mean pain scores for days 1 and 2 on the rhBMP-2 side were found to be lower than the mean pain scores on the control side, although these differences were not statistically significant, with P-values of 0.349 and 0.183, respectively (Figure 5).

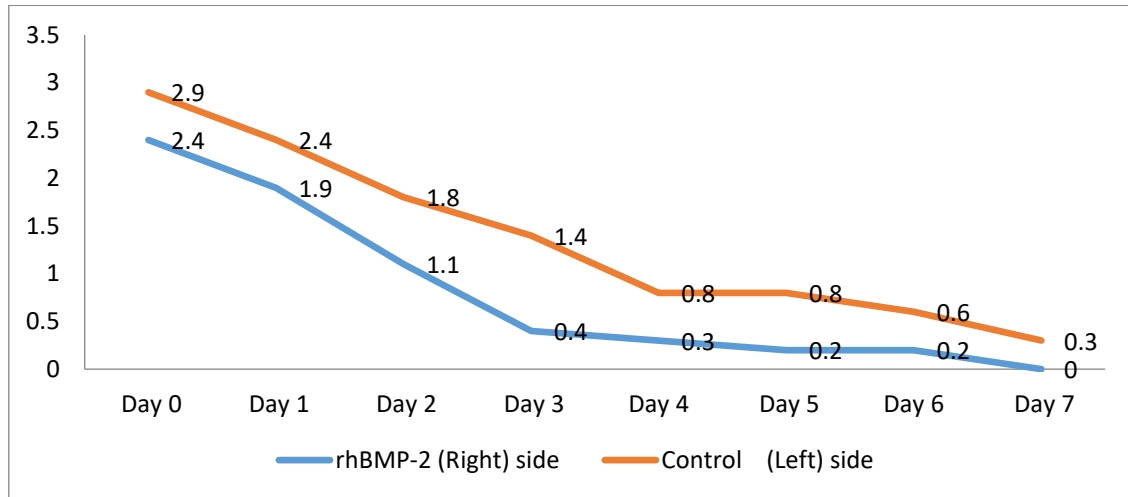


Figure 5. A graph showing the mean pain scores between the rhBMP-2 side and the control side

Interestingly, a statistically significant difference in the mean pain score at day 3 between the two groups emerged (P-value = 0.028), indicating that the pain scores diverged significantly on that particular day, favoring the rhBMP-2 side. This difference was statistically significant, as P-value (0.028) was less than the defined alpha level of 0.05. For days 4, 5, 6,

and 7, the analysis showed that there were no statistically significant differences between the rhBMP-2 side and the control side, as the calculated P-values were all greater than 0.05. These findings suggest that from day 4 onwards, there were no significant disparities in pain scores between the two sides (Table 1).

Table 1: Comparison of the pain score between the rhBMP-2 side and the control side.

	rhBMP-2 side Mean (SD)	Control side Mean (SD)	Mean Difference (Both sides)	P-value
Pain score Day 0	2.4 (2.2)	2.9 (2.3)	-0.5	0.641
Pain score Day 1	1.9 (1.2)	2.4 (1.4)	-0.5	0.349
Pain score Day 2	1.1 (0.8)	1.8 (1.5)	-0.7	0.183
Pain score Day 3	0.4(0.5)	1.4(1.4)	-1.1	0.028*
Pain score Day 4	0.3(0.5)	0.8(1.2)	-0.5	0.19
Pain score Day 5	0.2(0.4)	0.8(1.4)	-0.6	0.163
Pain score Day 6	0.2 (0.6)	0.6(1.1)	-0.4	0.250
Pain score Day 7	0(0)	0.3(0.5)	-0.3	0.067

SD: standard deviation; a P-value less than 0.05 is considered significant

Across the groups, in accordance with clinical evidence, it was observed that the mean pain score was at its peak on day 0 and progressively diminished in the subsequent days. Notably, this decline was more pronounced on the rhBMP-2 side compared to the control side. Importantly, statistically significant reductions in pain levels were detected on day 3 within the rhBMP-2 group, in contrast to the control group (P-value < 0.05). This signified that the application of rhBMP-2 led to a noteworthy and meaningful alleviation of pain on the third day after treatment, surpassing the impact observed in the control group.

To assess the rate of wound closure, we employed measurements of the space between the bucco-palatal soft tissue margins (mm) on both the rhBMP-2-treated side and the control side.

The one-way repeated measures ANOVA test yielded compelling results. It uncovered statistically

significant mean differences across various time intervals: day 0 and day 3, day 0 and day 7, day 0 and day 14, day 3 and day 7, and day 7 and day 14 (P-value < 0.0001). These significant differences strongly suggest dynamic changes in wound closure rates over time.

Furthermore, the observed differences were more pronounced on the rhBMP-2-treated side compared to the control side, as indicated in Table 2. This augmentation of differences indicates that the utilization of rhBMP-2 as ARP within a fresh socket site resulted in a heightened acceleration of the wound healing process.

Collectively, these findings lead us to a conclusive inference: the incorporation of rhBMP-2 in ARP can substantially expedite the wound healing process, as evident by the increased rate of wound closure.

Table 2: Comparison of the mean of bucco-palatal distance (mm) of soft tissue margins between rhBMP-2 side and control side

BP measurement (mm)	rhBMP-2 side	P-value	Control side	P-value
Day 0 Mean (SD)	7.8(2.5)		7.8(2.3)	
Day 3 Mean (SD)	5.3(1.6)		5(1.7)	
Day 7 Mean (SD)	3.1(0.9)		2.8(1.2)	
Day 14 Mean (SD)	0.1(0.3)		0.05(0.2)	
Difference in BP between Day 0 and Day 3	2.9(0.2)	<0.0001	2.5(0.3)	<0.0001
Difference in BP between Day 3 and Day 7	2.2(0.2)	<0.0001	2.2(0.3)	<0.0001
Difference in BP between Day 7 and Day 14	2.7(0.3)	<0.0001	3.0(0.3)	<0.0001
Difference in BP between Day 0 and Day 7	5.1(0.4)	<0.0001	4.7(0.6)	<0.0001
Difference in BP between Day 0 and Day 14	7.8(0.5)	<0.0001	7.7(0.8)	<0.0001
P-value	<0.0001			<0.0001

BP: bucco-palatal distance in mm of the soft tissue margin at the extracted site; SD: standard deviation

Discussion

The post-extraction healing process was the subject of much research in terms of pain and ARP. Postoperative pain is a stressful condition that the patient faces, and the oral surgeons try to reduce it by prescribing analgesics and non-steroidal anti-inflammatory drugs. As for ARP, many clinical studies have evaluated the induction and repair of bony defects in a variety of indications.^{5,18,19} In this context, they compared bone resorption, pain management, and wound healing at the extraction sites using different techniques of ridge preservation.^{15,16} The present study investigates the effect of rhBMP-2 embedded in a hemostatic sponge as ARP on reducing postoperative pain as well as its efficacy on the soft tissue healing process. To our knowledge, no other study compared hemostatic sponges embedded with rhBMP-2 with hemostatic sponge alone as ridge preservation techniques. Howell et al. used an absorbable collagen sponge filled with rhBMP-2 and found that it was well tolerated locally and systemically with no complications in ARP.¹⁹

For the postoperative pain, the rhBMP-2 was not significantly efficient during the 7 days except for the third one. The fact that there is no significant difference in pain rating scores between the rhBMP-2 and control sides may be due to the low sample size used in this study, but we noticed that the mean pain scores of the rhBMP-2 sides were less than the mean pain scores of the control sides during the 7 consecutive days.

Concerning the soft tissue healing process, our study concluded that rhBMP-2 induced faster soft tissue healing, but definite conclusions must be

delayed until future research with a larger sample validates our results.

Conclusion

Within the limits of our study, we can conclude that rhBMP-2 can decrease post-operative pain after tooth extraction and accelerate the soft tissue healing process.

Declarations

Conflict of interest and financial disclosure

The author declares that he has no conflict of interest and there was no external source of funding for the present study. None of the authors have any relevant financial relationship(s) with a commercial interest.

Ethical approval

Research protocol was approved by the local Ethical Committee (2018/23) and in accordance with those of the World Medical Association and the Helsinki Declaration.

Informed consent

Informed consent was obtained from all individual participants included in the study.

Source of Funding

Non funding.

Availability of Data and Materials

Not applicable.

REFERENCES

1. Alenazi A, Alotaibi AA, Aljaeidi Y, Alqhtani NR. The need for socket preservation: a systematic review. *J Med Life*. 2022;15(3):309-312. doi:10.25122/jml-2021-0308
2. Araújo MG, Lindhe J. Dimensional ridge alterations following tooth extraction. An experimental study in the dog. *J Clin Periodontol*. 2005;32(2):212-218. doi:10.1111/j.1600-051X.2005.00642.x
3. Juodzbaly G, Stumbras A, Goyushov S, Duruel O, Tözüm TF. Morphological classification of extraction sockets and clinical decision tree for socket preservation/augmentation after tooth extraction: a systematic review. *J Oral Maxillofac*

- Res. 2019;10(3):e3. doi:10.5037/jomr.2019.10303
4. Kalsi AS, Kalsi JS, Bassi S. Alveolar ridge preservation: why, when and how. *Br Dent J.* 2019;227(4):264-274. doi:10.1038/s41415-019-0647-2
 5. Stumbras A, Kuliesius P, Januzis G, Juodzbaly G. Alveolar ridge preservation after tooth extraction using different bone graft materials and autologous platelet concentrates: A systematic review. *J Oral Maxillofac Res.* 2019;10(1):e2. doi:10.5037/jomr.2019.10102
 6. Wood RA, Mealey BL. Histologic comparison of healing after tooth extraction with ridge preservation using mineralized versus demineralized freeze-dried bone allograft. *J Periodontol.* 2012;83(3):329-336. doi:10.1902/jop.2011.110270
 7. Fukuba S, Akizuki T, Matsuura T, et al. Effects of combined use of recombinant human fibroblast growth factor-2 and β -tricalcium phosphate on ridge preservation in dehiscence bone defects after tooth extraction: A split-mouth study in dogs. *J Periodontal Res.* 2021;56(2):298-305. doi:10.1111/jre.12818
 8. Urist MR. Bone: formation by autoinduction. *Science.* 1965;150(3698):893-899. doi:10.1126/science.150.3698.893
 9. Carragee EJ, Hurwitz EL, Weiner BK. A critical review of recombinant human bone morphogenetic protein-2 trials in spinal surgery: emerging safety concerns and lessons learned. *Spine J.* 2011;11(6):471-491. doi:10.1016/j.spinee.2011.04.023
 10. Ten Heggeler JM, Slot DE, Van der Weijden GA. Effect of socket preservation therapies following tooth extraction in non-molar regions in humans: a systematic review. *Clin Oral Implants Res.* 2011;22(8):779-788. doi:10.1111/j.1600-0501.2010.02064.x
 11. Treede RD. The International Association for the Study of Pain definition of pain: as valid in 2018 as in 1979, but in need of regularly updated footnotes. *Pain Rep.* 2018;3(2):e643. doi:10.1097/PR9.0000000000000643
 12. Simpson HE. The healing of extraction wounds. *Br Dent J.* 1968;124(12):569.
 13. Cardaropoli G, Araújo M, Lindhe J. Dynamics of bone tissue formation in tooth extraction sites. An experimental study in dogs. *J Clin Periodontol.* 2003;30(9):809-818. doi:10.1034/j.1600-051x.2003.00366.x
 14. Devlin H, Sloan P. Early bone healing events in the human extraction socket. *Int J Oral Maxillofac Surg.* 2002;31(6):641-645. doi:10.1054/ijom.2002.0292
 15. Schropp L, Wenzel A, Kostopoulos L, Karring T. Bone healing and soft tissue contour changes following single-tooth extraction: a clinical and radiographic 12-month prospective study. *Int J Periodontics Restorative Dent.* 2003;23(4):313-323
 16. Ma WH, Liu YJ, Wang W, Zhang YZ. Neuropeptide Y, substance P, and human bone morphogenetic protein 2 stimulate human osteoblast osteogenic activity by enhancing gap junction intercellular communication. *Braz J Med Biol Res.* 2015;48(4):299-307. doi:10.1590/1414-431X20144226
 17. Glossary. *Spine* 25(24):p3200-3202, December 15, 2000
 18. Cochran DL, Jones AA, Lilly LC, Fiorellini JP, Howell H. Evaluation of recombinant human bone morphogenetic protein-2 in oral applications including the use of endosseous implants: 3-year results of a pilot study in humans. *J Periodontol.* 2000;71(8):1241-1257. doi:10.1902/jop.2000.71.8.1241
 19. Howell TH, Fiorellini J, Jones A, et al. A feasibility study evaluating rhBMP-2/absorbable collagen sponge device for local alveolar ridge preservation or augmentation. *Int J Periodontics Restorative Dent.* 1997;17(2):124-139

ՄԱՐԳՈՒ ՈՍԿՐԱՅԻՆ ՄՈՐՖՈԳԵՆԵՏԻԿ ՊՐՈՏԵԻՆ-2-Ի ՎԵՐԱՀԱՄԱԿՑՎԱԾ ԱՉԴԵՑՈՒԹՅՈՒՆԸ ՈՐՊԵՍ ԱՆՎԵՈՒԱՅԻՆ ԳԱԳԱԹԻ ՊԱՀՊԱՆԱՆ, ՑԱՎԻ ՆՎԱԶԵՑՄԱՆ և ՓԵՓՈՒԿ ՀՅՈՒՄՎԱԾՔՆԵՐԻ ԲՈՒԺՄԱՆ ԳՈՐԾՐՆԹԱՅԻ ՎՐԱ ՊԵՆՏԱՅԻՆ ՓՈՐՁԱՐԱՐԱԿԱՆ ՀԵՏԱԶՈՏՈՒԹՅՈՒՆ

Ժան Նասսար,¹ Ժորժ Աուն,² Լինդա Աբու-Աբբաս,³ Միռնա Սաբրա³

- ¹ Պարողոնտոլոգիայի բաժին, Ստոմատոլոգիական բժշկության ֆակուլտետ, Բեյրութի Լիբանանի համալսարան, Բեյրութ Լիբանան
- ² Ստոմատոլոգիայի և դիմածնոտային ճառագայթաբանության ամբիոն, Ստոմատոլոգիական բժշկության ֆակուլտետ, Լիբանանի համալսարան, Բեյրութ, Լիբանան:
- ³ Նյարդաբանության հետազոտությունների կենտրոն, Լիբանանի համալսարանի բժշկական գիտությունների ֆակուլտետ, Բեյրութ, Լիբանան

Ամփոփում

Ներածություն. Ատամի հեռացումից հետո ատամնաբնային ելունում գնում է ոսկրային ֆիզիոլոգիական ռեգորբցիայի պրոցես:

Հետազոտվել և մշակվել են ատամնաբնային ելունի պահպանման (ARP) մի քանի տեխնիկա՝ այս գործընթացը նվազեցնելու և իմպլանտների համապատասխան տեղադրման համար բարենպաստ ատամնաբնային ելունի ծավալի և մորֆոլոգիայի պահպանման համար:

Ոսկրային մորֆոգենետիկ սպիտակուցները (BMPs) սպիտակուցներ են, որոնք ստացվում են փոխակերպող աճի գործոնի ընտանիքի ենթաբազմությունից, որոնք արագացնում են ոսկրացումը՝ վերահսկելով ոսկրերի ինդուկցիայի կասկադի հիմնական գործոնները՝ հանգեցնելով օստեոբլաստների տարածմանը մեզենխիմային ցողունային բջիջներից և ոսկրային մատրիցայի կենսասինթեզից: Այս BMP-ներից մեկը մարդու ոսկրերի ռեկոմբինանտ մորֆոգենետիկ սպիտակուց-2-ն է (rhBMP-2), որը հաստատված է ARP-ում օգտագործման համար:

Նպատակը. Այս հետազոտության նպատակն է գնահատել rhBMP-2-ի ազդեցությունը ատամի հեռացումից հետո բուժման գործընթացի և ցավի մակարդակի վրա:

Մեթոդներ. Այս պիլոտային հետազոտության ընթացքում 11 հիվանդի առնվազն երկու ատամ են հանել և պատահականորեն լցրել մեկ ավելոլային խոռոչը հեմոստատիկ սպունգով, իսկ մյուսը՝ rhBMP-2 պարունակող հեմոստատիկ սպունգով: Երկու անցքերն էլ կարվել են X-տեխնիկայի միջոցով: Վերքերի բուժման չափումներ կատարվեցին 3-րդ, 7-րդ և 14-րդ օրերին, և յուրաքանչյուր մասնակցի խնդրվեց փաստաթղթավորել իրենց ցավի փորձը՝ օգտագործելով թվային գնահատման սանդղակը (NRS):

Արդյունքները. Համապատասխան կլինիկական տվյալներին, նկատվեց, որ ցավի միջին միավորը հասել է զազաթնակետին 0-րդ օրը և աստիճանաբար նվազել հաջորդ օրերին: Հատկանշական է, որ այս կրճատումն ավելի ցայտուն էր rhBMP-2 խմբում՝ համեմատած հսկիչ խմբի հետ: Կարևոր է նշել, որ 3-րդ օրը rhBMP-2 խումբը, ի տարբերություն հսկիչ խմբի, ցույց է տվել ցավի մակարդակի վիճակագրորեն զգալի նվազում (P արժեքը < 0,05): Սա ցույց տվեց, որ rhBMP-2-ի օգտագործումը հանգեցրել է նկատելի և նշանակալի ցավազրկման բուժումից հետո երրորդ օրը, ինչը գերազանցում է վերահսկիչ խմբում նկատված ազդեցությունը: Ինչ վերաբերում է վերքերի բուժման փոփոխություններին, վիճակագրորեն նշանակալի միջին տարբերություններ են հայտնաբերվել տարբեր ժամանակային ընդմիջումներով՝ օր 0 և 3 օր, օր 0 և օր 7, օր 0 և օր 14, օր 3 և օր 7, օր 7 և օր 14 (P- արժեքը < 0,0001): Այս էական տարբերությունները վճռականորեն ենթադրում են ժամանակի ընթացքում վերքերի փակման արագության դինամիկ փոփոխություններ: Ավելին, նկատված տարբերություններն ավելի ցայտուն էին rhBMP-2-ով բուժված խմբում, համեմատած վերահսկիչ խմբի հետ: Տարբերությունների այս անը ցույց է տալիս, որ RhBMP-2-ի օգտագործումը ARP-ի համար թարմ վարդակի տեղում հանգեցրել է վերքերի բուժման գործընթացի արագացման:

Եզրակացություն. Մեր արդյունքները ցույց են տալիս, որ rhBMP-2-ը կարող է նվազեցնել հետվիրահատական ցավը ատամի հեռացումից հետո և արագացնել փափուկ հյուսվածքների ապաքինման գործընթացը:

ВЛИЯНИЕ РЕКОМБИНИРОВАННОГО МОРФОГЕНЕТИЧЕСКОГО БЕЛКА-2 ЧЕЛОВЕЧЕСКОЙ КОСТИ В КАЧЕСТВЕ КОНСЕРВАЦИИ АЛЬВЕОЛЯРНОГО ГРЕБНЯ НА УМЕНЬШЕНИЕ БОЛИ И ПРОЦЕСС ЗАЖИВЛЕНИЯ МЯГКИХ ТКАНЕЙ: РАЗДЕЛЕННОЕ ПИЛОТНОЕ ИССЛЕДОВАНИЕ

Жан Нассар,¹ Жорж Аун,² Линда Абу-Аббас,³ Мирна Сабра³

- ¹ Кафедра пародонтологии, факультет стоматологической медицины, Ливанский университет Бейрут, Ливан
- ² Кафедра стоматологии и челюстно-лицевой радиологии, факультет стоматологической медицины, Ливанский университет, Бейрут, Ливан
- ³ Центр нейробиологических исследований, факультет медицинских наук, Ливанский университет, Бейрут, Ливан

Абстракт

Введение: После удаления зуба альвеолярный отросток подвергается физиологической резорбции кости. Несколько методов сохранения альвеолярного отростка (ARP) были исследованы и разработаны с целью уменьшить этот процесс и сохранить благоприятный объем и морфологию альвеолярного отростка для соответствующей установки имплантата.

Костные морфогенетические белки (BMP) представляют собой белки, полученные из подгруппы семейства трансформирующих факторов роста, которые ускоряют оссификацию путем контроля основных факторов каскада индукции кости, что приводит к пролиферации остеобластов из мезенхимальных стволовых клеток и биосинтезу костного матрикса. Одним из этих BMP является рекомбинантный костный морфогенетический белок-2 человека (rhBMP-2), который разрешен к использованию для ARP.

Цель: Целью данного исследования является оценка влияния rhBMP-2 на процесс заживления и уровень боли после удаления зуба.

Методы: В этом пилотном исследовании с разделенным ртом 11 пациентам были удалены как минимум два зуба, и случайным образом одна из альвеолярных лунок была заполнена гемостатической губкой, а другая - гемостатической губкой, содержащей rhBMP-2. Обе лунки были ушиты по X-технике. Измерения заживления ран проводились на 3, 7 и 14 дни, и каждому участнику было предложено документировать свои ощущения боли, используя числовую рейтинговую шкалу (NRS).

Результаты: В соответствии с клиническими данными было замечено, что средний показатель боли достиг своего пика в день 0 и постепенно уменьшался в последующие дни. Примечательно, что это снижение было более выраженным в группе rhBMP-2 по сравнению с контрольной группой. Важно отметить, что на 3-й день в группе rhBMP-2 в отличие от контрольной группы было выявлено статистически значимое снижение уровня боли (значение $P < 0,05$). Это указывало на то, что применение rhBMP-2 привело к заметному и значимому облегчению боли на третий день после лечения, превосходя эффект, наблюдавшийся в контрольной группе. Что касается изменений в заживлении ран, были выявлены статистически значимые средние различия в различных временных интервалах: день 0 и день 3, день 0 и день 7, день 0 и день 14, день 3 и день 7, день 7 и день 14 (P -значение $< 0,0001$). Эти существенные различия убедительно свидетельствуют о динамических изменениях скорости закрытия ран с течением времени. Более того, наблюдаемые различия были более выраженными в группе, получавшей rhBMP-2, по сравнению с контрольной группой. Это увеличение различий указывает на то, что использование rhBMP-2 для ARP в свежем участке лунки приводило к повышенному ускорению процесса заживления ран.

Заключение: Наши результаты показывают, что rhBMP-2 может уменьшить послеоперационную боль после удаления зуба и ускорить процесс заживления мягких тканей.



A LIFE DEDICATED TO STOMATOLOGY



A life dedicated to dentistry

Doctor of Medical Sciences, Professor Karen Lalayan celebrates her 80th anniversary with great merit as a scientist, as an experienced physician and as a dedicated lecturer.

Born 09.12.1943, graduated from Baku State Medical University in 1965.

The most unique, memorable page of Karen Lalayan's biography was written at the "Van" dental center in Yerevan/Armenia, where he has been working as the head of the department of surgical dentistry since 1974.


Karen Lalayan headed the Department of Family and Surgical Dentistry at the National Institute of Health for many years, from 2014 to 2018 headed the Department of Family and Surgical Dentistry of Yerevan State Medical University M. Heratsi, from 2018 to the present, Professor of the Department of Surgical Stomatology and Maxillofacial Surgery of Yerevan State University. M. Heratsi

Thanks to the talented leadership, the department has reached a high level of scientific and technical development. As the head of the department, Professor Karen Lalayan was a mentor to many young doctors and scientists who achieved impressive successes in Armenia and around the world, and now the professor also continues his scientific and teaching activities.

Professor Karen Lalayan is the author of more than 65 scientific works, including 2 monographs.

Karen Lalayan created and headed the Armenian Association of Dentists of the 21st Century.

The area of his scientific activity includes the introduction of the hemostatic drug Kaprofer, which has antiseptic, antimycotic and antioxidant properties, used in surgical practice (both in dentistry, maxillofacial surgery, and in military field and general surgery).



Professor Karen Lalayan at the presentations of the book monograph Kaprofer

research on the development of a new design of intraosseous dental implants.

For many years of fruitful work and scientific achievements, Professor Karen Lalayan has been awarded numerous awards and titles and currently continues to be active for the benefit of higher medical education in Armenia.

His professional achievements are recognized nationally and internationally.

Awards

- Badge "Excellence in Healthcare"
- Medal of Honor. P. Ehrlich
- Medal of Honor. R. Virchow

He lives to share his experiences, connect with fellow clinicians and students, and care for patients.

Karen Lalayan enjoys life. He excels in music, especially jazz. He is an inspiring father, a playful grandfather and a devoted and caring husband to his wife. He is principled, goal-oriented, open and honest.

On behalf of the members of the editorial board of "Bulletin of Dentistry and Maxillofacial Surgery" /JBSMFS/ we have the honor to congratulate Professor Karen Lalayan with deep respect, express pride and gratitude to him, and wish him new achievements and success both in his professional and work activities.

Editor-in-Chief Professor Gagik Hakobyan
Head of the Department of Surgical Dentistry and Maxillofacial Surgery,
Yerevan State Medical University after M. Heratsi

ԿՅՁՆՔ՝ ՆՎԻՐՎԱԾ ԱՏՈՄԱՏՈԼՈԳԻԱՅԻՆ

Բժշկական գիտությունների դոկտոր, պրոֆեսոր Կարեն Լալայանը մեծ վաստակով նշում է իր ծննդյան 80-ամյակը՝ որպես գիտնական, որպես փորձառու բժիշկ և որպես նվիրյալ դասախոս:

Ծնվել է 1943 թվականի դեկտեմբերի 9-ին, 1965 թվականին ավարտել է Բաքվի պետական բժշկական համալսարանը:

Կարեն Լալայանի կենսագրության ամենայնուհանդերձ, հիշարժան էջը գրվել է Երևանի Վան ստոմատոլոգիական կենտրոնում, որտեղ նա 1974 թվականից աշխատում է որպես վիրաբուժական ստոմատոլոգիայի բաժանմունքի ղեկավար:

Կարեն Լալայանը երկար տարիներ ղեկավարել է Առողջապահության ազգային ինստիտուտի ընտանեկան և վիրաբուժական ստոմատոլոգիայի ամբիոնը, այնուհետև ղեկավարել է Մ. Հերացու անվ Երևանի պետական համալսարանի ընտանեկան և վիրաբուժական ստոմատոլոգիայի ամբիոնը: 2018թ.-ից առ այսօր Մ. Հերացու անվ Երևանի պետական համալսարանի ստոմատոլոգիական և դիմաձևոտային վիրաբուժության ամբիոնի պրոֆեսոր:

Հնուտ ղեկավարության շնորհիվ ամբիոնները հասել են գիտատեխնիկական զարգացման բարձր մակարդակի: Որպես ամբիոնի վարիչ՝ պրոֆեսոր Կարեն Լալայանը կրթել է բազմաթիվ երիտասարդ բժիշկների և գիտնականների, ովքեր տպավորիչ հաջողությունների են հասել Հայաստանում և ամբողջ աշխարհում, այժմ պրոֆեսորը շարունակում է իր գիտական և դասախոսական գործունեությունը:

Պրոֆեսոր Կարեն Լալայանը հեղինակ է ավելի քան 65 գիտական աշխատությունների, այդ թվում՝ 2 մենագրության:

Կարեն Լալայանը ստեղծել և ղեկավարել է 21-րդ դարի ստոմատոլոգների հայկական ասոցիացիան:

Գիտական գործունեության ոլորտը ներառում է հեմոստատիկ Kaprofer դեղամիջոցի ներդրումը, որն ունի հակասեպտիկ, հակամիկոտիկ և հակաօքսիդիչ հատկություններ, որն օգտագործվում է վիրաբուժական պրակտիկայում (ինչպես ստոմատոլոգիայում, դիմաձևոտային վիրաբուժության, այնպես էլ ռազմաբժշկության և ընդհանուր վիրաբուժության մեջ):

Հայաստանում առաջին անգամ նա կատարել է ներոսկրային ատամնային իմպլանտների նոր համակարգի մշակման հետազոտություն:

Երկար տարիների բեղմնավոր աշխատանքի և գիտական նվաճումների համար պրոֆեսոր Կարեն Լալայանը արժանացել է բազմաթիվ մրցանակների ու կոչումների և ներկայումս շարունակում է իր ակտիվ գործունեությունը՝ ի նպաստ Հայաստանում բարձրագույն բժշկական կրթության:

Նրա մասնագիտական ձեռքբերումները ճանաչված են ինչպես ազգային, այնպես էլ միջազգային մակարդակով:

Մրցանակներ

- Կրծքանշան «Գերազանցություն առողջապահության ոլորտում»:
- Պատվո շքանշան Պ. Էրլիխ
- Պատվո շքանշան Ռ. Վիրխով

Նա ապրում է կիսելու իր փորձառությունները, կապվելու գործընկեր բժիշկների և ուսանողների հետ և հոգ տանելու հիվանդների մասին:

Կարեն Լալայանը վայելում է կյանքը, նա գերազանց է երաժշտության, հատկապես ջազի մեջ: Նա ոգեշնչող հայր է, ժիր պապիկ և իր կնոջ համար նվիրված ու հոգատար ամուսին: Նա սկզբունքային է, նպատակասլաց, բաց ու ազնիվ:

«Bulletin of Dentistry and Maxillofacial Surgery» /JBSMFS/ ամսագրի խմբագրական խորհրդի անդամների անունից պատիվ ունենք խորին հարգանքով շնորհավորել պրոֆեսոր Կարեն Լալայանին, հայտնել հպարտություն և երախտագիտություն նրան, մաղթել նորանոր ձեռքբերումներ և ձեռքբերումներ: հաջողություններ ինչպես մասնագիտական, այնպես էլ աշխատանքային գործունեության մեջ:

Գլխավոր խմբագիր, պրոֆեսոր Գագիկ Հակոբյան
Երևանի պետական համալսարանի վիրաբուժական ստոմատոլոգիայի
և դիմաձևոտային վիրաբուժության ամբիոնի վարիչ:
Երևանի Մ. Հերացու անվան պետական բժշկական համալսարան

ЖИЗНЬ, ПОСВЯЩЕННАЯ СТОМАТОЛОГИИ

Доктор медицинских наук, профессор Карен Лалаян с огромными заслугами отмечает свое 80-летие как ученый, как опытный врач и как самоотверженный лектор.

Родился 09.12.1943 года, в 1965 году окончил Бакинский государственный медицинский университет.

Самая уникальная, запоминающаяся страница биографии Карена Лалаяна написана в стоматологическом центре «Ван» в Ереване/Армения, где он работает заведующим отделением хирургической стоматологии с 1974 года.

Карен Лалаян долгие годы, возглавлял кафедру семейной и хирургической стоматологии Национального института здравоохранения, позже возглавлял кафедру семейной и хирургической стоматологии ЕГМУ им. Гераци, с 2018 г. по настоящее время профессор кафедры хирургии стоматологии и челюстно-лицевой хирургии ЕГМУ им. Гераци. Благодаря талантливому руководству кафедра достигла высокого уровня научно-технического развития. Будучи заведующим кафедрой, профессор Карен Лалаян был наставником многих молодых врачей и ученых, добившихся впечатляющих успехов в Армении и во всем мире, и сейчас профессор также продолжает свою научную и преподавательскую деятельность.

Профессор Карен Лалаян является автором более 65 научных работ, в том числе 2 монографий.

Карен Лалаян создал и возглавил Армянскую ассоциацию стоматологов XXI века.

В область научной деятельности входит внедрение кровоостанавливающего препарата Капрофер, обладающего антисептическими,

антимикотическими и антиоксидантными свойствами, применяемого в хирургической практике (как в стоматологии, челюстно-лицевой хирургии, так и в военно-полевой и общей хирургии).

Впервые в Армении он провел исследования по разработке новой конструкции внутрикостных дентальных имплантатов.

За многолетнюю плодотворную работу и научные достижения профессор Карен Лалаян удостоен многочисленных наград и званий и в настоящее время продолжает вести активную деятельность на благо высшего медицинского образования в Армении.

Его профессиональные достижения признаны на национальном и международном уровне.

Награды

- Знак «Отличник здравоохранения».
- Медаль за отвагу. П. Эрлих
- Медаль за отвагу. Р. Вирхова

Он живет, чтобы делиться своим опытом, общаться с коллегами-клиницистами и студентами и заботиться о пациентах.

Карен Лалаян наслаждается жизнью. Он преуспевает в музыке, особенно в джазе. Он вдохновляющий отец, игривый дедушка и преданный и заботливый муж для своей жены. Он принципиален, целеустремлен, открыт и честен.

От имени членов редколлегии журнала «Вестник стоматологии и челюстно-лицевой хирургии» /JBSMFS/ мы имеем честь с глубоким уважением поздравить профессора Карена Лалаяна, выразить ему гордость и благодарность, пожелать ему новых достижений и успехов в его профессиональной и трудовой деятельности.

Главный редактор, профессор Гагик Акопян
Заведующий кафедрой хирургической стоматологии и челюстно-лицевой хирургии,
Ереванский государственный медицинский университет имени М. Гераци

Content

<p>Galina Chistyakova COMPARATIVE ANALYSIS OF THE EFFECT OF ADHESIVE SYSTEMS ON THE MICROELEMENT COMPOSITION OF THE DENTIN OF THE CROWN PART OF THE TOOTH</p>	5-11
<p>Harpreet Singh, Urvashi Sagar, Rishu Gautam, Rajiv K. Chugh PREVALENCE AND MORPHOLOGY OF MIDDLE MESIAL CANAL AND MIDDLE DISTAL CANAL IN MANDIBULAR FIRST MOLARS IN NORTH INDIAN SUBPOPULATION: A RETROSPECTIVE CBCT ANALYSIS</p>	12-18
<p>Vahe Azatyan, Lazar Yessayan, Yuri Azbekyan THE CLINICAL AND MORPHOLOGICAL LESIONS OF THE ORAL MUCOSA AND PERIODONTIUM WITH VIRAL HEPATITIS C</p>	19-30
<p>Ginosyan Knarik, Ghazinyan Irina, Nazaretyan Eduard, Eghiazaryan Nikolay, Efremidu Maritsa, Sevoyan Lilit, Osipyany Magda COEXISTENCE OF SJOGREN'S SYNDROME AND FAMILIAL MEDITERRANEAN FEVER: A RARE COMBINATION</p>	31-35
<p>Komal K. Ghadge, Sharath K. Shetty, Anita Kulloli, Ketan Deshetti, Dharmarajan Gopalakrishnan ENHANCEMENT OF SOFT TISSUE SURROUNDING DENTAL IMPLANTS – AN OVERVIEW OF LITERATURE</p>	36-48
<p>Gagik Hakobyan, Lazar Yessayan, Hovhannes Karapetyan, Yuri Azbekyan, Davit Mathevossyan APPLICATION OF THE METHOD OF FREQUENCY-RESONANCE ANALYSIS OF IMPLANTS INSTALLED AFTER AUTOGENOUS BONE TRANSPLANTATION</p>	49-58
<p>Sergo Hovhannisyanyan, Karen Mashinyan, Levon Khachatryan, Edgar Karapetyan, Artavazd Kharazyan, Mikayel Ordoyan, Aram Badalyan MAXILLOFACIAL REHABILITATION IN PATIENT WITH NEOPLASMS USING ZYGOMATIC IMPLANT-SUPPORTED PROSTHESES</p>	59-71
<p>Karen Grigoryan ACCURACY OF A ROBOTIC DENTAL IMPLANT NAVIGATION SYSTEM IN DENTAL IMPLANT PRACTICE</p>	72-82
<p>Francesco Litta, Lucia Memè, Filippo Grilli, Enzo Iacomino, Fratini Chiara,2 Fabrizio Bambini, Stefano Mummolo RARE ODONTOSTOMATOLOGY COMPLICATION ASSOCIATED WITH DISLOCATION OF A SILASTIC NASAL SPLINT: A CASE REPORT</p>	83-90
<p>Lourimar de Moura Moreira, Ricardo Grillo, Jeová Clementino de Almeida Júnior, Rubens Gonçalves Teixeira FAMILIAL FOURTH MOLARS IN NON-SYNDROMIC PATIENTS: CASE REPORT OF AN UNUSUAL ENTITY</p>	91-95
<p>Boris Gharamanyan, Tina Chkhikvadze, Valery Bekreev COMPLEX TREATMENT OF INTERNAL TMJ DISORDERS IN PATIENTS WITH DIFFERENT BIT TYPES</p>	96-105
<p>Armine Gharakeshishyan, Hovsep Miroyan, Meri Stepanyan CASE REPORT: IDIOPATHIC SCLEROSING ORBITAL INFLAMMATION</p>	106-111
<p>Tereza Azatyan, Stepan Grigoryan MODERN METHODS FOR ASSESSING MOTOR AND SENSORY INTER-HEMISPHERIC ASYMMETRY OF THE BRAIN IN CHILDREN OF PRIMARY AND SECONDARY SCHOOL AGE (8-11 YEARS OLD)</p>	112-119
<p>Lyudmila Tatintsyanyan, Lazar Yessayan, Gohar Gevorgyan, Tatevik Barseghyan, Valery Tatintsyanyan THE USE OF “DIPLÉN-S” ADHESIVE MEMBRANE IN THE COMPLEX THERAPY OF RECURRENT APHTHOUS STOMATITIS. (CLINICAL CASE REPORT)</p>	120-127

H.M. Darawsheh, T. Entel, Z.K. Omarova, A.A. Batov, I.M. Smilyk, A.V. Glinskii, F.I. Bakieva, R.J. Meylanova, O.V. Kytko, Yu.L. Vasil'ev VASCULAR COMPLICATION AFTER LATERAL TEMPORAL LIFTING TECHNIQUE: A CASE REPORT	128-135
Jean Nassar, Georges Aoun, Linda Abou-Abbas, Mirna Sabra EFFECTS OF RECOMBINED HUMAN BONE MORPHOGENETIC PROTEIN-2 AS ALVEOLAR RIDGE PRESERVATION ON PAIN REDUCTION AND SOFT TISSUE HEALING PROCESS: A SPLIT MOUTH DESIGNED PILOT STUDY	136-145
Gagik Hakobyan A LIFE DEDICATED TO STOMATOLOGY	146-149

ISSN 1829-006X
BULLETIN OF STOMATOLOGY AND MAXILLOFACIAL
SURGERY
Scientific and practical journal
Volume 19, Issue 4
2023

The journal is indexed in international databases: Scopus, Google Scholar, CrossRef, CiteFactor, Scilit (Scientific Literature), Academic Resource Index (ResearchBib), ResearchGate, DOI.

Information sponsor: YSMU, Armenian Association of Oral and MFS Surgeons, Armenian Association of Dentists, Periodontists, Orthodontists, Ophthalmologists, Otorhinolaryngologists, Dermatovenerolog, medu.am.

Founder: "Akra" LLC

State certificate number registration: 01²-043330, dated: October 23, 1998

Contacts

Editorial address: 375025 RAYerevan, st. Heratsi 5

Tel.: +37491403038

E-mail: hakobyan_gv@rambler.ru

E-mail: prom_hg@yahoo.com

E-mail: stomatologymfsjournal@gmail.com

Responsible for the release: Professor Gagik Hakobyan

Signed for printing: 05.12.2023

Printed on 14.12.2023

Format 60 x 84 1/8

Offset paper, typeface Times

Volume 2.625 standard print.l.

Circulation 100 copies.

Typography: info@tparan.am