

DOI: 10.58240/1829006X-2023.19.4-49



ORIGINAL ARTICLE

APPLICATION OF THE METHOD OF FREQUENCY-RESONANCE ANALYSIS OF IMPLANTS INSTALLED AFTER AUTOGENOUS BONE TRANSPLANTATION

Gagik Hakobyan,^{1*} Lazar Yessayan,² Hovhannes Karapetyan,³ Yuri Azbekyan,⁴ Davit Mathevosyan⁵

- ¹ Professor, Head of Department of Oral and Maxillofacial Surgery, Yerevan State Medical University after M. Heratsi, Armenia
² Professor, Head of Department of Therapeutic Stomatology, Yerevan State Medical University after M. Heratsi, Armenia
³ Center of Excellence in Dental Education Yerevan State Medical University after M. Heratsi, Armenia
⁴ Student, Faculty of Stomatology Yerevan State Medical University after M. Heratsi, Armenia
⁵ Assistant Professor, Department of Oral and Maxillofacial Surgery, Yerevan State Medical University after M. Heratsi, Armenia

* Corresponding author: Professor Gagik Hakobyan DMSc, PhD, Head of Department of Oral and Maxillofacial Surgery, University of Yerevan State Medical University, Yerevan, Armenia
e-mail: prom_hg@yahoo.com

Received: Oct. 2, 2023; Accepted: Oct. 27, 2023; Published: Nov. 5, 2023

Abstract

Background: Purpose of study determine the timing of prosthetic rehabilitation of patients after autograft and dental implantation of the jaw bone using resonance-frequency method (RFA).

Methods: The analysis of the treatment of 34 with vertical resorption of the lower jaws, and dental implant prosthetic rehabilitation performed for the period 2020-2023. All patients underwent a complex clinical, laboratory study, computed tomography (CT). At the first stage, the autogen bone grafting procedure, at the second stage, 4 months after autogen bone grafting implants were installed. 3 months later, after implants inserted to determine the timing of prosthetic rehabilitation, the method of RFA-Resonance Frequency Analysis method was used, if normal results were recorded, the prosthodontic phase began. Postoperative clinical and radiological monitoring was regularly conducted, and criteria for the success of implantation and success of prosthetics of implant- supported reconstructions were evaluated. Change in marginal bone levels was assessed by taking digital x-rays immediately after restoration fixation (base line for comparison), after 1 and 3, 5 years post operatively.

Results: No intra-operative or immediate post-operative complications were noted after autografting procedure. The postoperative of the patients was favorable, with the integration of the autografts. 3 months after autogenous bone grafting, the resorption of the graft in some transplant recipients is up to 10%. All of the patients presented with healthy soft tissue. Marginal bone loss data were recorded, mean marginal bone loss (MBL) was 1.2 ± 0.25 mm after 3 years. The mean RFA recordings of all 136 implants were 65 ISQ at implant placement respectively 73 ISQ after 3 months. The functional load on dental implants was performed with ISQ values above 65 (dental prosthetic rehabilitation was performed after 3-4 months of submerged healing). A total of 8 implant failures were recorded. After 5 years show survival rates 97%.

Conclusions: RFA could serve as a noninvasive diagnostic tool for detecting implant stability during healing stages and subsequent routine follow ups. The method of resonance-frequency analysis allows us to determine the timing of the beginning of the prosthetic stage in each specific case.

Keywords: RFA-Resonance Frequency Analysis, autogenous bone grafting, dental implantation, implant stability

Introduction

The problem of orthopedic rehabilitation of patients with maxillofacial defects of the jaws is one of the most pressing problems of modern reconstructive maxillofacial surgery.

Acquired maxillofacial defects are usually accompanied by severe functional and aesthetic impairments, impaired socio-psychological adaptation of this category of patients.¹

These can be defects of a traumatic and inflammatory nature, flaws that arise as a result of the removal of pathological purulent foci.

Long-term tooth loss leads to significant bone resorption, which makes implant placement difficult, causing functional and aesthetic problems.²⁻⁴ Particularly difficult problems arise with pronounced vertical bone resorption, since the use of osteoplastic materials does not provide the necessary restoration of bone tissue parameters.⁵⁻⁸

In case of insufficient quantitative parameters of the jaws in patients, various bone-growth operations are performed to prepare for implantation.⁹⁻¹²

The use of bone grafts is the standard for atrophied bone repair, as they contain both osteogenic cells and an osteoconductive mineralized extracellular matrix where they can grow.

For the restoration of bone tissue in such clinical situations, the use of autogenous grafts is highly effective in comparison with other methods.¹¹⁻¹⁴

According to many authors, the two-stage method is more predictable and reliable, since during this period the autograft matures and has good blood circulation,

In the case of serious defects, there is a risk of resorption of the autograft volume before implant placement or after orthopedic rehabilitation.^{15,16}

Radiographic diagnostic data assessing the condition of bone tissue after reconstructive surgery show that the bone tissue undergoes changes over time after surgery, gradually increasing in density, reaching a maximum within six months.¹⁷ Based on the above, it should be noted that this period is the most expedient for the placement of implant.

Usually, implant stability and osseointegration have been assessed using various techniques, including insertion torque, percussion testing and radiographic analysis.^{18,19} Loading protocols and

healing time for individual patients are often empirically calculated based on clinical research studies evaluating implant stability and osseointegration over time.

Analysis of scientific publications shows that the most modern and reliable clinical method for assessing the stability of dental intraosseous implants is the method of resonance frequency analysis (RFA).²⁰

The method is based on the registration of resonant electromagnetic oscillations of the implant surrounding the bone when exposed to an electromagnetic field by means of an electronic sensor. RFA-Resonance Frequency Analysis developed by N. Meredith²¹ is widely used to objectively assess the quality of bone tissue.

This test records the resonant spectrometric vibrations of a Smart peg post attached to an implant under the influence of an electromagnetic field. Performed by the device Osstell-mentor ISQ (Integration Diagnostics, Gothenburg, Sweden) is an objectively informative method for assessing the osseointegration of an implant. RFA allows you to determine the timing of the load on the implant and for the early diagnosis of complications. The Implant Stability Index (ISQ) is recorded on the screen of the device, the higher the index, the stronger the implant fixation. Higher bone density has been positively correlated with higher RFA values. According to N. Meredith, the index of primary stability of the implant in the upper jaw is -58 ISQ, and in the lower jaw - 66 ISQ.²²

Despite numerous scientific studies using this method, there are few publications in which the method of resonance frequency analysis is used to determine the time of the functional load of implants installed in an autologous bone graft.²³

Considering the above, this method was included in our study, among other diagnostic methods, for an objective assessment of the stability of the implant and to determine the optimal timing of orthopedic treatment in the area of bone regeneration. All of the above confirms the urgency of the problem and determined the purpose of this study.

Purpose of study determine the timing of orthopedic rehabilitation of patients after autograft reconstructive operations on the jaw using the method

of dental implantation using resonance-frequency method.

Materials and methods

The analysis of the treatment of 34 patients (men-14, women-12, age from 28 to 63 years) with vertical resorption of the lower jaws, performed for the period 2020-2023. The following criteria were with drawn from this study the presence of somatic, endocrine, oncological, infectious diseases, blood diseases, pregnancy.

All patients provided written consent to be included in this study and to use facial images for the purposes of the study. All patients underwent a complex clinical, X-ray, laboratory study, computed tomography (CT). The treatment was planned taking into account the parameters of the bone tissue in the area of the missing teeth. After research and diagnosis, a treatment plan was drawn up, including an implant surgery followed by prosthodontic treatment.

At the first stage, auto-transplantation was carried out in the chewing areas of the lower jaw, at the second stage, after four months further implantation. The treatment plan was agreed with the patient. The autograft was taken from the chin or retromolar areas of the mandible. The operation was performed under premedication and local anesthesia. The autograft was adapted and fixed in the donor area with titanium screws, the empty space in the donor area was filled with bone material and then closed with resorbable membrane Bio Oss. After reposition of the mucous membrane, sutures were applied. Prophylactic anti-inflammatory therapy and local antiseptic measures were carried out. The postoperative period was calm, without complications.

136 dental implants were installed in the edentulous arches using surgical guides. Implants were installed 3 months after autogenous bone grafting. After implant insertion, preventive complex anti-inflammatory therapy was performed, the patient was under dynamic control. 4 months later, the implant closure screws were removed, the smart peg pin was fixed to the implants and determine the timing of prosthetic rehabilitation, the method of RFA-

Resonance Frequency Analysis method was used, if normal results were recorded, the prosthodontic phase began.

Digital technologies were included in the workflow with the laboratory scanning of the master casts and CAD/CAM manufacturing software. The orthopedic treatment was performed using metal-ceramic implant-based fixed orthopedic structures.

Postoperative clinical and radiological monitoring was regularly conducted, and criteria for the success of implantation and success of prosthetics of implant-supported reconstructions were evaluated. Outcome measures were: graft success, implant success; complications and marginal bone levels, prosthesis success. Change in implants marginal bone levels was assessed by taking digital x-rays immediately after restoration fixation (base line for comparison), after 1, 3- and 5-years post after one and three years post operatively.

Statistical analysis

Statistical analysis was performed using the statistical software package SPSS 23 (Statistical Package for Social Science 23).

Results

No intra-operative or immediate post-operative complications were noted and no flap failure occurred. The postoperative of the patients was favorable, with the integration of the autografts. Complete engraftment of bone autografts and wound healing was obtained in all observations. 3 months after autogenous bone grafting, the resorption of the graft in some transplant recipients is up to 10%. 6-month follow-up period evaluation of CT scan revealed implants demonstrated to integrate normally. All of the patients presented with healthy soft tissue. Marginal bone loss data were recorded, mean marginal bone loss (MBL) was 1.2 ± 0.25 mm. After 5 years show survival rates 97.6% The mean RFA recordings of all 104 implants were 65 ISQ at implant placement respectively 73 ISQ after 3 months. The functional load on dental implants was performed with

ISQ values above 65 (dental prosthetic rehabilitation was performed after 3-4 months of submerged healing) (Figure 1-10). According to the given computed tomography, patients, who underwent autograft surgery of the vertical resorption, had an average height of 6.2mm and after graft surgery 12.8mm.

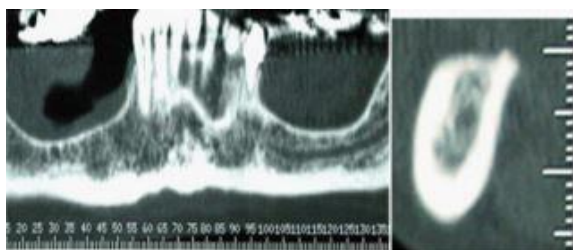


Figure 1 (a, b). CT scan before autograft

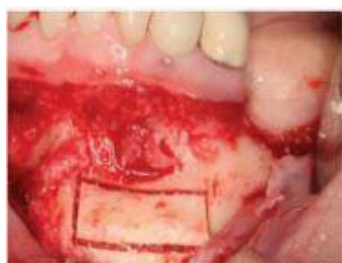

Figure 2. The autograft from the chin areas

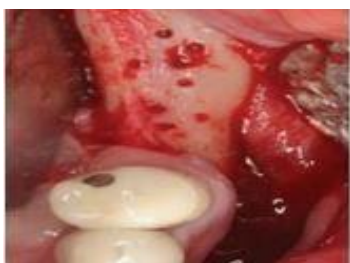

Figure 3. Recipient area before autograft surgery with round bar

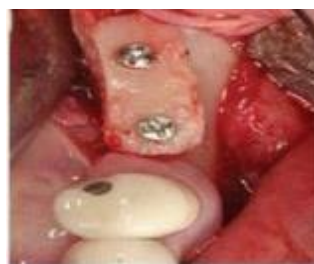

Figure 4. The autograft was adapted and fixed in the donor area with titanium screws

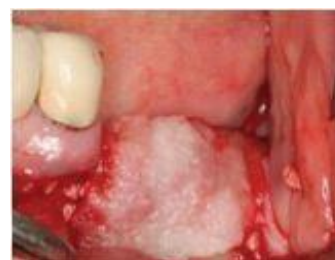

Figure 5. Intraoral clinical view, the empty space in the donor area was filled with bone material Bio Oss and then closed with resorbable membrane

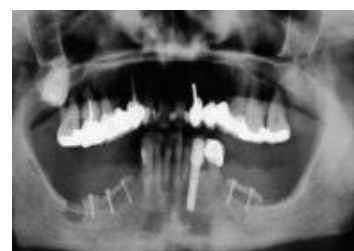

Figure 6. CT scan after autograft surgery, the autograft was adapted and fixed in the donor area with titanium screws

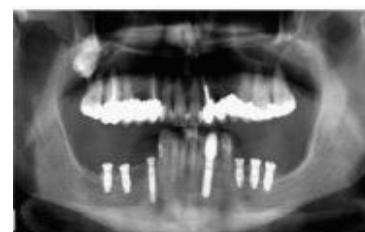

Figure 7. CT scan after implants insertion

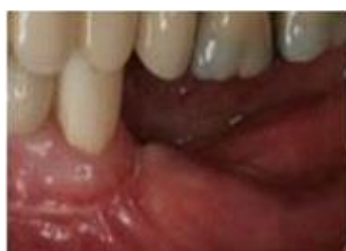

Figure 8. Intraoral clinical view before implant screws removed

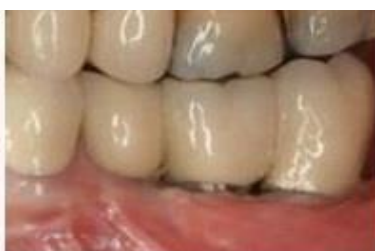

Figure 9. Intraoral view after prosthetic rehabilitation

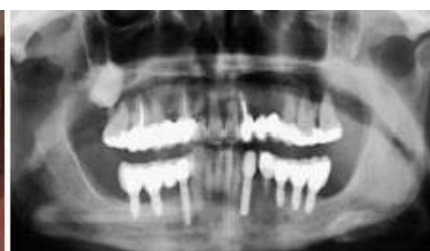

Figure 10. CT scan after prosthetic rehabilitation

Discussion

Dental implants are a predictive and reliable treatment option, provided there is a sufficient quantity and quality of bone to achieve the desired functional and aesthetic results.²⁴ When using implants, jaw atrophy is sharply slowed down to the physiological level, which undoubtedly plays an important role in implant placement. For effective implantation, sufficient parameters of the bone tissue in the implantation zone are required. However, unfavorable conditions, due to oral infections, bone atrophy after dental extractions, and long term edentulism, may result in insufficient available bone, making implant placement impossible. In case of bone deficiency, bone grafting is performed using Guided bone regeneration, autogenous bone grafting, distraction osteogenesis, ridge-split. Autogenous bone transplants are the gold standard for bone grafting, but the difficulty of obtaining the graft and the soreness of the donor part of the jaw hinders their use.²⁵⁻³²

Currently, after bone grafting, however resorption of bone materials after surgery and complications limits their use, which is especially important for vertical resorption, in which vertical bone augmentation is effective only during autogenous plastic surgery.^{33,34}

The timing of implant insertion after bone grafting is important for the effectiveness of osteointegration in the area of bone grafting, taking into account the risk of resorption of the graft and according to numerous reports, the percentage after autogenous grafting is 20-30 percent.³⁵⁻³⁷

The degree of maturity of the autograft and the readiness of implant insertion in the area is determined according to the data of the catheter and according to certain bones.^{37,38}

In the literature, there are few publications on the determination of the timing of the functional load of implants installed in the area of bone grafting, which prompted this study.³⁹

ISQ readings can be used to determine different healing phases and the stability of dental implants.^{40,41}

The results of a clinical study prove the reliability of autologous bone grafts for pre-prosthetic reconstruction of the alveolar ridge before implant placement. High graft success rate (95.6%) and implant failure rate (2,4% periimplantitis). Our

observations of patients treated with this technique prove that intraoral and extraoral autologous bone grafts should be considered the gold standard for preprosthetic dentoalveolar reconstruction. This study demonstrates that the reconstruction of atrophic jaws using bone grafts from intraoral donor sites is a predictable technique for the dental rehabilitation of patients with crestal atrophy associated with high bone survival and implantation success. Currently, despite the fact that there are many bone substitutes, autologous bone is considered as the most effective material for two-stage preprosthetic augmentation for oral implantation. Intraoral autologous grafts can be a reliable option for restoring the resorbed mandible with further implant placement. Autologous overhead grafts from the ramus of the mandible, symphysis, offer sufficient bone volume to restore an atrophic jaw and are excellent treatment alternatives for patients when reconstruction is required prior to implant placement. In addition to the successful reconstruction of the alveolar ridge with the correct choice of the donor site, the pain of the procedure should be minimal, this study presents results of treatment effectiveness 26 patients with lower jaw edentulous and with vertical atrophy. 104 implants were installed for arch reconstructions after autograft and dental implant and 4 months later, the implant closure screws were removed, the smart peg pin was fixed to the implant. The resonance frequency analysis method (RFA-) use to determine the timing of the beginning of the prosthetic stage, if normal results were recorded, the prosthodontic phase began. ISQ gradually increases after implant placement, and in case of a decrease in the index due to implant overload, timely therapeutic and preventive measures are taken to prevent loss of the implant.

Conclusions

The results of this study indicated the prosthetic rehabilitation of patients after autograft and dental implant at prosthetic rehabilitation of the jaw bone can provide good esthetic and functional results. RFA could serve as a noninvasive diagnostic tool for detecting implant stability during healing stages and subsequent routine follow ups. The method of resonance-frequency analysis allows us to determine

the timing of the beginning of the prosthetic stage in each specific case.

Declarations

Conflict of interest and financial disclosure

The author declares that he has no conflict of interest and there was no external source of funding for the present study. None of the authors have any relevant financial relationship(s) with a commercial interest.

Ethical approval

Research protocol was approved by the local Ethical Committee (2018/23) and in accordance with

those of the World Medical Association and the Helsinki Declaration.

Informed consent

Informed consent was obtained from all individual participants included in the study.

Source of Funding

Non funding.

Availability of Data and Materials

Not applicable.

Acknowledgements

Not applicable.

REFERENCES

1. Dings JPI, Merckx MAW, de Clonie Maclennan-Naphausen MTP, van de Pol P, Maal TJJ, Meijer GJ. Maxillofacial prosthetic rehabilitation: A survey on the quality-of-life Affiliations expand. *J Prosthet Dent.* 2018;120(5):780-786. doi:10.1016/j.prosdent.2018.03.032
2. Ahmed W, Adil Asim M, Ehsan A, Abbas Q. Non-Vascularized Autogenous Bone Grafts for Reconstruction of Maxillofacial Osseous Defects. *J Coll Physicians Surg Pak.* 2018;28(1):17-21. doi:10.29271/jcpsp.2018.01.17
3. Buser D, Dula K, Belser UC, Hirt HP, Berthold H. Localized ridge augmentation using guided bone regeneration. II. Surgical procedure in the mandible. *Int J Periodontics Restorative Dent.* 1995;15(1):10-29
4. Chiapasco M, Casentini P, Zaniboni M. Bone Augmentation Procedures in Implant Dentistry. *The International Journal of Oral & Maxillofacial Implants.* 2009;24:237-259
5. Bak MM, Jacobson AS, Buchbinder D, et al. Contemporary Reconstruction of the Mandible. *Oral Oncology.* 2010;4:71-76. doi:10.1016/j.oraloncology.2009.11.006
6. Falisi G, Galli M, Velasquez PV, Rivera JCG, Di Paolo C. Implant stability evaluation by resonance frequency analysis in the fit lock technique. A clinical study. *Ann Stomatol (Roma).* 2013;4(2):196-203
7. Cassetta M, Ricci L, Iezzi G, Dell'Aquila D, Piattelli A, Perrotti V. Resonance frequency analysis of implants inserted with a simultaneous grafting procedure: a 5-year follow-up study in man. *Int J Periodontics Restorative Dent.* 2012;32(5):581-589
8. Aloja ED, Ricci M, Caso G, et al. The use of bone block allografts in sinus augmentation, followed by delayed implant placement: Case Series. *Clinical Dentistry.* 2013;4(1):175-185. doi:10.4103/0976-237X.111587
9. Buser D, Dula K, Belser UC, Hirt HP, Berthold H. Localized ridge augmentation using guided bone regeneration. II. Surgical procedure in the mandible. *Int J Periodontics Restorative Dent.* 1995;15(1):10-29

10. Cebrian-Carretero JL, Guiñales-Díaz de Cevallos J, Sobrino JA, Yu T, Burgueño-García M. Predictable dental rehabilitation in maxillomandibular reconstruction with free flaps. The role of implant guided surgery. *Med Oral Patol Oral Cir Bucal*. 2012;19(6):605- 611. doi:10.4317/medoral.19116
11. Kim YK, Ku JK. Ridge augmentation in implant dentistry. *Journal of the International Clinical Dental Research Organization*. 2015;7(1):95-112. doi:10.5125/jkaoms.2020.46.3.211
12. Harshakumar K, Varghese NM, Ravichandran R, Lylajam S. Alveolar Ridge Augmentation using Autogenous Block Bone Grafts Harvested from Mandibular Ramus to Facilitate Implant Placement: A Case Report. *International Journal of Scientific Study*. 2014;2(1):46-50
13. Assoumane A, Liu K, Shao Z, Shang ZJ. Double Barrel Fibula Flap with Immediate Dental Implant Insertion for Reconstruction of Mandibular Defects. *Global Journal of Otolaryngology*. 2018;14(1):121-26. doi:10.19080/GJO.2018.13.555876
14. Dawood A, Susan T, Hutchison I. Computer Guided Surgery for Implant Placement and Dental Rehabilitation in a Patient Undergoing Sub-Total Mandibulectomy and Microvascular Free Flap Reconstruction. *Jour. of Oral Implant*. 2013;35(4):497-502. doi:10.1563/AAID-JOI-D-11-00142
15. van der Meij AJ, Baart JA, Prahl-Andersen B, Valk J, Kostense PJ, Tuinzing DB. Computed tomography in evaluation of early secondary bone grafting. *Int J Oral Maxillofac Surg*. 1994;23:132-136. doi:10.1016/s0901-5027(05)80286-3
16. Swami V, Vijayaraghavan V, Swami V. Current trends to measure implant stability. *J Indian Prosthodont Socv*. 2016;16(2):124–130. doi:10.4103/0972-4052.176539
17. Mall N, Dhanasekar B, Aparna IN. Validation of implant stability: A measure of implant permanence. *Indian J Dent Res*. 2011;22(3):462-7. doi:10.4103/0970-9290.87071
18. Quesada-García MP, Prados-Sánchez E, Olmedo-Gaya MV, Muñoz-Soto E, González-Rodríguez MP, Vallecillo-Capilla M. Measurement of dental implant stability by resonance frequency analysis: A review of the literature. *Med Oral Patol Oral Cir Bucal*. 2009;14(10):538-46. doi:10.4317/medoral.14.e538
19. Meredith N. Assessment of implant stability as a prognostic determinant. *Int J Prosthodont*. 1998;11(5):491-501
20. Meredith N, Alleyne D, Cawley P. Quantitative determination of the stability of the implant- tissue interface using resonance frequency analysis. *Clin Oral Implants Res*. 1996;7:261–267. doi:10.1034/j.1600-0501.1996.070308.x
21. Vallecillo-Rivas M, Reyes-Botella C, Vallecillo C, Lisbona-González MJ, Vallecillo-Capilla M, Olmedo-Gaya MV. Comparison of Implant Stability between Regenerated and Non-Regenerated Bone. A Prospective Cohort Study. *J Clin Med*. 2021;10(15):3220. doi:10.3390/jcm10153220
22. Montero J. A Review of the Major Prosthetic Factors Influencing the Prognosis of Implant Prosthodontics. *J Clin Med*. 2021;10:816. doi:10.3390/jcm10040816
23. Titsinides S, Agrogiannis G, Karatzas T. Bone grafting materials in dentoalveolar reconstruction: A comprehensive review. *Jpn Dent Sci Rev*. 2019;55(1):26-32. doi:10.1016/j.jdsr.2018.09.003
24. Stricker A, Schramm A, Marukawa E, Lauer G, Schmelzeisen R. Distraction osteogenesis and tissue engineering-new options for enhancing the implant site. *Int J Periodontics Restorative Dent*. 2003;23(3):297-302.
25. Buser D, Dula K, Hirt HP, Schenk RK. Lateral ridge augmentation using autografts and barrier membranes: Clinical study with 40 partially edentulous patients. *J Oral Maxillofac Surg*. 1996;54:420-432. doi:10.1016/S0278-2391(96)90113-5

26. Moses O, Nemcovsky CE, Langer Y, Tal H. Severely resorbed mandible treated with iliac crest autogenous bone graft and dental implants: 17-year follow-up. *Int J Oral Maxillofac Implants*. 2007;22:1017-1021
27. Sakkas A, Wilde F, Heufelder M, Winter K, Schramm A. Autogenous bone grafts in oral implantology - is it still a “gold standard”? A consecutive review of 279 patients with 456 clinical procedures. *Int J Implant Dent*. 2017;3:23. doi:10.1186/s40729-017-0084-4
28. Von Arx T, Buser D, Horizontal ridge augmentation using autogenous block grafts and the guided bone regeneration technique with collagen membranes: A clinical study with 42 patients. *Clinical Oral Implants Research*. 2006;17(4):359-366. doi:10.1111/j.1600-0501.2005.01234.x
29. Cordaro L, Amadè DS, Cordaro M. Clinical results of alveolar ridge augmentation with mandibular block bone grafts in partially edentulous patients prior to implant placement. *Clinical Oral Implants Research*. 2002;13(1):103-111. doi:10.1034/j.1600-0501.2002.130113.x
30. Sheikh Z, Corneliu Sima C, Glogauer M. Bone Replacement Materials and Techniques Used for Achieving Vertical Alveolar Bone Augmentation *Materials (Basel)*. 2015;8(6):2953–2993. doi:10.3390/ma8062953
31. Gultekin BA, Bedeloglu E, Emre Kose T, Mijiritsky E. Comparison of Bone Resorption Rates after Intraoral Block Bone and Guided Bone Regeneration Augmentation for the Reconstruction of Horizontally Deficient Maxillary Alveolar Ridges. *Clinical Study*. 2016;4987437. doi:10.1155/2016/4987437
32. Jensen AT, Jensen SS, Worsaae N. Complications related to bone augmentation procedures of localized defects in the alveolar ridge. A retrospective clinical study. *Oral Maxillofac Surg*. 2016;20(2):115-122. doi:10.1007/s10006-016-0551-8
33. Sakkas A, Wilde F, Heufelder M, Winter K, Schramm A. Autogenous bone grafts in oral implantology—is it still a “gold standard”? A consecutive review of 279 patients with 456 clinical procedures. *Int J Implant Dent*. 2017;3:23. doi:10.1186/s40729-017-0084-4
34. Nkenke E, Neukam FW. Autogenous bone harvesting and grafting in advanced jaw resorption: morbidity, resorption and implant survival. *Eur J Oral Implantol*. 2014;7(2):203-17
35. Maiorana C, Beretta M, Salina S, Santoro F. Reduction of autogenous bone graft resorption by means of Bio-Oss coverage: A prospective study. *Int J Period Rest Dent*. 2005;1:19–25.
36. Alérico FA, Bernardes SR, Fontão FN GK, Diez GF, Alérico JHS, Claudino M. Prospective tomographic evaluation of autogenous bone resorption harvested from mandibular ramus in atrophic maxilla. *Journal of Craniofacial Surgery*. 2014;25(6):543–546. doi:10.1097/SCS.0000000000001045
37. Meenakshi S, Raghunath N, Raju SN, Srividya S, Indira PN. Implant stability a key determinant in implant integration. *Trends Prosthodont Dent Implantol*. 2013;4:28–48
38. Ersanli S, Karabuda C, Beck F, Leblebicioglu B. Resonance frequency analysis of one-stage dental implant stability during the osseointegration period. *J Periodontol*. 2005;76(7):1066-71. doi:10.1902/jop.2005.76.7.1066
39. Andreotti AM, Goiato MC, Nobrega AS, et al. Relationship Between Implant Stability Measurements Obtained by Two Different Devices: A Systematic Review. *Periodontol*. 2017;88(3):281-288. doi:10.1902/jop.2016.160436. Epub 2016 Oct 21

ԱՌՏՈՂԵՆ ՈՍԿՐԱՅԻՆ ՓՈԽՊԱՏՎԱՍՏՈՒՄԻՑ ՀԵՏՈ ՏԵՂԱԴՐՎԱԾ ԻՄՊԼԱՆՏՆԵՐԻ
ՀԱՃԱԽԱԿԱՆ-ՌԵԶՈՆԱՆՍԱՅԻՆ ՎԵՐԼՈՒԾՈՒԹՅԱՆ ՄԵԹՈԴԻ ԿԻՐԱՌՈՒՄ

Գագիկ Հակոբյան,¹ Լազար Եսայան,² Հովհաննես Կարապետյան,³ Ազբեկյան Յուրի,⁴
Դավիթ Մաթևոսյան⁵

- ¹ Պրոֆեսոր, Երևանի Մ. Հերացու անվան պետական բժշկական համալսարանի վիրաբուժական ստոմատոլոգիայի և դիմաձնոտային վիրաբուժության ամբիոնի վարիչ, Հայաստան
- ² Պրոֆեսոր, Երևանի Մ. Հերացու անվան պետական բժշկական համալսարանի թերապևտիկ ստոմատոլոգիայի ամբիոնի վարիչ, Հայաստան
- ³ Երևանի Մ. Հերացու անվան պետական բժշկական համալսարանի Ստոմատոլոգիական կրթության գերազանցության կենտրոն, Հայաստան
- ⁴ Երևանի Մ. Հերացու անվան պետական բժշկական համալսարանի Ստոմատոլոգիական ֆակուլտետի ուսանող, Հայաստան
- ⁵ Երևանի Մ. Հերացու անվան պետական բժշկական համալսարանի վիրաբուժական ստոմատոլոգիայի և դիմաձնոտային վիրաբուժության ամբիոնի ասիստենտ

Ամփոփում

Նպատակ. Հետազոտության նպատակը որոշել է հիվանդների պրոթեզային վերականգնման ժամկետները ծնոտի ոսկորների ավտոփոխպատվաստումից և իմպլանտացիայից հետո՝ օգտագործելով ռեզոնանսային հաճախականության մեթոդը (RFA):

Մեթոդներ. Ստորին ծնոտների ուղղահայաց ռեզորբցիայով 34 հիվանդների բուժման վերլուծությունը և ատամների իմպլանտների պրոթեզավորումը իրականացվել է 2020-2023 թվականներին: Բոլոր հիվանդներն անցել են համալիր կլինիկական, լաբորատոր հետազոտություն, համակարգչային տոմոգրաֆիա (CT): Առաջին փուլում աուտոգեն ոսկրային փոխպատվաստման պրոցեդուրան, երկրորդում՝ աուտոգեն ոսկրային պատվաստման իմպլանտների տեղադրումից 4 ամիս անց: 3 ամիս անց, օրթոպեդիկ վերականգնման ժամկետները որոշելու համար իմպլանտների տեղադրումից հետո, կիրառվել է RFA- ռեզոնանսային հաճախականության վերլուծության մեթոդը, նորմալ արդյունքների գրանցման դեպքում սկսվել է պրոթեզավորման փուլը: Պարբերաբար անցկացվել է հետվիրահատական կլինիկական և ռենտգենաբանական մոնիտորինգ, գնահատվել է իմպլանտացիայի հաջողությունը և իմպլանտի վրա հիմնված վերակառուցումների պրոթեզավորման հաջողությունը: Մարզինալ ոսկրային մակարդակի փոփոխությունը գնահատվել է վերականգնողական ֆիքսացիայից անմիջապես հետո թվային ռենտգենյան ճառագայթների միջոցով (համեմատության բազային զիծ), վիրահատությունից 1 և 3, 5 տարի հետո: **Արդյունքներ.** Աուտոգեն ոսկրային փոխպատվաստումից հետո ներվիրահատական կամ անմիջական հետվիրահատական բարդություններ չեն արձանագրվել: Հիվանդների հետվիրահատական շրջանը բարենպաստ է եղել՝ ավտոփոխպատվաստների ինտեգրմամբ: Աուտոգեն ոսկրային փոխպատվաստումից 3 ամիս հետո որոշ ռեցիպիենտների մոտ փոխպատվաստման ռեզորբցիան հասնում է 10%-ի: Բոլոր հիվանդները ներկայացրել են առողջ փափուկ հյուսվածքներ: Արձանագրվել են սահմանային ոսկրային կորստի տվյալները, միջին սահմանային ոսկրային կորուստը (MBL) եղել է $1,2 \pm 0,25$ մմ 3 տարի հետո: Բոլոր 136 իմպլանտների միջին RFA ձայնագրությունները եղել են 65 ISQ իմպլանտների տեղադրման ժամանակ, համապատասխանաբար 73 ISQ 3 ամսից հետո: Իմպլանտների ֆունկցիոնալ

ճանրաբեռնվածությունը կատարվել է 65-ից բարձր ISQ արժեքներով (ասամի պրոթեզային վերականգնումը կատարվել է ջրի տակ ապաքինումից 3-4 ամիս հետո): Ընդհանուր առմամբ գրանցվել է իմպլանտի 8 կորուստ: 5 տարի անց իմպլանտների գոյատևման մակարդակը 97,6%:

Եզրակացություններ. RFA-ն կարող է ծառայել որպես ոչ ինվազիվ ախտորոշիչ գործիք՝ ապաքինման փուլերում իմպլանտի կայունությունը հայտնաբերելու և հետագա բարդությունները կանխելու համար: Ռեզոնանսային-հաճախական վերլուծության մեթոդը թույլ է տալիս յուրաքանչյուր կոնկրետ դեպքում որոշել պրոթեզավորման փուլի սկզբի ժամանակը:

ПРИМЕНЕНИЕ МЕТОДА ЧАСТОТНО-РЕЗОНАНСНОГО АНАЛИЗА ИМПЛАНТАТОВ, УСТАНОВЛЕННЫХ ПОСЛЕ АУТОГЕННОЙ ТРАНСПЛАНТАЦИИ КОСТИ

Гагик Акопян,¹ Лазар Есаян,² Оганес Карапетян,³ Юрий Азбекян,⁴ Давит Матевосян⁵

¹ Профессор, заведующий кафедрой хирургической стоматологии и челюстно-лицевой хирургии, Ереванский государственный медицинский университет им. М. Гераци, Армения

² Профессор, заведующий кафедрой терапевтической стоматологии, Ереванский государственный медицинский университет им. М. Гераци, Армения

³ Стоматологический образовательный центр превосходства, Ереванский государственный медицинский университет им. М. Гераци, Армения

⁴ Студент Факультета стоматологии, Ереванский государственный медицинский университет им. М. Гераци, Армения

⁵ Преподаватель кафедры хирургической стоматологии челюстно-лицевой хирургии, Ереванский государственный медицинский университет им. М. Гераци, Армения

Абстракт

Цель исследования: Определить сроки протезной реабилитации пациентов после аутотрансплантата и дентальной имплантации кости челюсти с использованием резонансно-частотного метода.

Методы: Проведен анализ лечения 34 пациентов с вертикальной резорбцией нижних челюстей и дентальной имплантологической реставрацией, проведенной за период 2020-2023 гг. Всем пациентам проведено комплексное клинично-лабораторное исследование, компьютерная томография (КТ). На первом этапе проведена процедура аутогенной костной пластики, на втором этапе через 4 месяца после аутогенной костной пластики установлены имплантаты. Через 3 месяца после установки имплантатов для определения сроков ортопедической реабилитации применяли метод резонансно-частотного анализа, при регистрации нормальных результатов начинали этап протезирования. Регулярно проводился послеоперационный клинично-рентгенологический контроль, определялись критерии, оценивалась успешность имплантации и успешность протезирования реконструкций с опорой на имплантаты. Изменение уровня маргинальной кости оценивали с помощью цифровой рентгенографии сразу после фиксации реставрации (базовая линия для сравнения), через 1 и 3, 5 года после операции.

Результаты: После процедуры аутотрансплантации не было отмечено никаких интраоперационных или ближайших послеоперационных осложнений. Послеоперационный период у пациентов был благоприятный, с приживлением аутотрансплантатов. Через 3 мес после аутогенной костной пластики резорбция трансплантата у некоторых реципиентов трансплантата достигает 10%. У всех пациентов были здоровые мягкие ткани. Были записаны данные о потере маргинальной костной массы, средняя потеря маргинальной костной массы (MBL) составила $1,2 \pm 0,25$ мм через 3 года. Средний показатель RFA для всех 136 имплантатов составил 65 ISQ при установке имплантата и соответственно 73 ISQ через 3 месяца. Функциональную нагрузку на дентальные имплантаты осуществляли при значениях ISQ выше 65 (протезирование зубов осуществляли через 3-4 месяца погруженного приживления). Всего было зарегистрировано 8 отказов имплантата. Через 5 лет показатель выживаемости составляет 97,6%.

Выводы: Резонансно-частотный анализа может служить неинвазивным диагностическим инструментом для определения стабильности имплантата на этапах заживления и последующих плановых осмотрах. Метод резонансно-частотного анализа позволяет определить сроки начала ортопедического этапа в каждом конкретном случае.